

Management of Incidental Liver Lesions on CT: A White Paper of the ACR Incidental Findings Committee SA-CME

Richard M. Gore, MD^a, Perry J. Pickhardt, MD^b, Koenraad J. Mortele, MD^c, Elliot K. Fishman, MD^d, Jeanne M. Horowitz, MD^e, Claus J. Fimmel, MD^f, Mark S. Talamonti, MD^g, Lincoln L. Berland, MD^h, Pari V. Pandharipande, MD, MPHⁱ

Abstract

The ACR Committee on Incidental Findings presents recommendations for managing liver lesions that are incidentally detected on CT. These recommendations represent an update from the liver component of the ACR 2010 white paper on managing incidental findings in the pancreas, adrenal glands, kidneys, and liver. The Liver Subcommittee—which included five abdominal radiologists, one hepatologist, and one hepatobiliary surgeon—developed this algorithm. The recommendations draw from published evidence and expert opinion and were finalized by informal iterative consensus. Algorithm branches categorize liver lesions on the basis of patient characteristics and imaging features. They terminate with an assessment of benignity or a specific follow-up recommendation. The algorithm addresses most, but not all, pathologies and clinical scenarios. The goal is to improve the quality of care by providing guidance on how to manage incidentally detected liver lesions.

Key Words: Incidental finding, hepatic cyst, hemangioma, focal nodular hyperplasia, hepatic metastasis, hepatocellular carcinoma

J Am Coll Radiol 2017;■:■-■. Copyright © 2017 American College of Radiology

OVERVIEW OF THE ACR INCIDENTAL FINDINGS PROJECT

The core objectives of the Incidental Findings Project are to (1) develop consensus on patient characteristics and imaging features that are required to characterize an incidental finding, (2) provide guidance to manage such findings in ways that balance the risks and benefits to patients, (3) recommend reporting terms that reflect the level of confidence regarding a finding, and (4) focus future research by proposing a generalizable management

framework across practice settings. The ACR Committee on Incidental Findings (IFC) generated its first white paper in 2010, addressing methods for managing incidental findings in four organ systems: pancreas, adrenal glands, kidneys, and liver [1].

THE CONSENSUS PROCESS: THE LIVER LESION ALGORITHM

The present report represents the first revision of the IFC's 2010 recommendations regarding incidental liver

^aDepartment of Radiology, NorthShore University HealthSystem, Evanston, Illinois.

^bDepartment of Radiology, University of Wisconsin School of Medicine, Madison, Wisconsin.

^cDepartment of Radiology, Beth Israel Deaconess Medical Center, Brookline, Massachusetts.

^dDepartment of Radiology, Johns Hopkins Hospital, Baltimore, Maryland.

^eNorthwestern University Feinberg School of Medicine, Chicago, Illinois.

^fDepartment of Medicine (Gastroenterology), NorthShore University HealthSystem, Evanston, Illinois.

^gDepartment of Surgery, NorthShore University HealthSystem, Evanston, Illinois.

^hDepartment of Radiology, University of Alabama at Birmingham, Birmingham, Alabama.

ⁱDepartment of Radiology, Institute for Technology Assessment, Massachusetts General Hospital, Boston, Massachusetts.

Corresponding author and reprints: Richard M. Gore, MD, Department of Radiology, Evanston Hospital, Evanston, IL 60201; e-mail: rgore@uchicago.edu.

Dr Pickhardt is a cofounder of VirtuoCTC, has received personal fees from Check-Cap and Bracco, and is a shareholder in Collectar, Elucent, and SHINE, outside the submitted work. Dr Berland has received personal fees from Nuance Communications, outside the submitted work. Dr Pandharipande has received a research grant from the Medical Imaging and Technology Alliance, outside the submitted work. All other authors have no conflicts of interest related to the material discussed in this article.

lesions detected on CT. The process of developing this algorithm included naming a subcommittee chair, who appointed four additional abdominal radiologists, one hepatologist, and one hepatobiliary surgeon. The subcommittee then developed and gained consensus on a preliminary version of the algorithm using published evidence as their primary source. Where evidence was not available, they invoked the collective expertise of their team. The preliminary algorithm underwent review by additional members within the IFC, including the Body Commission chair, the IFC chair, and additional IFC subcommittee chairs. The revised algorithm and corresponding white paper draft were submitted to additional ACR stakeholders to gain input and feedback. Consensus was obtained iteratively after successive reviews and revisions. After completion of this process, the algorithm and white paper were finalized. The IFC's consensus processes meet policy standards of the ACR. However,

they do not meet any specific, formal national standards. This algorithm and set of recommendations does not represent policy of the ACR Practice Guidelines or the ACR Appropriateness Criteria. Our consensus may be termed “guidance” and “recommendations” rather than “guidelines,” which has a more formal definition.

ELEMENTS OF THE FLOWCHARTS: COLOR CODING

The proposed algorithm for incidental liver lesions is included in [Figure 1](#). Yellow boxes indicate using or acquiring clinical data (eg, lesion size), green boxes describe recommendations for action (eg, follow-up MRI), and red boxes indicate that no follow-up is needed (eg, the finding is benign). To minimize complexity, the algorithm addresses most, but not all, imaging appearances and clinical scenarios. Radiologists should feel comfortable deviating from the algorithm in

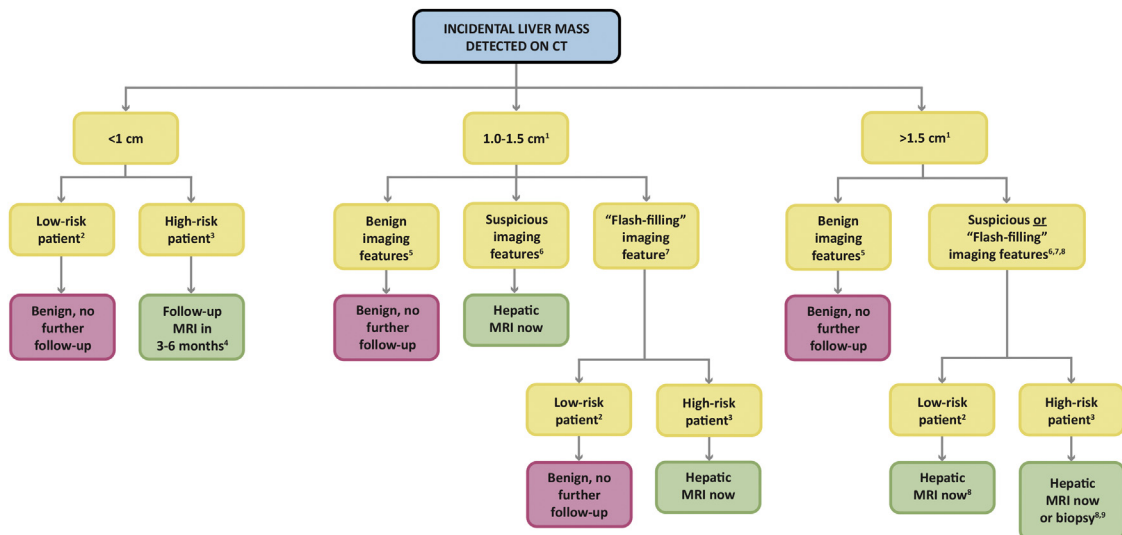


Fig 1. Algorithm for incidental liver lesions. ¹If inadequate imaging is available to ascertain the presence of benign versus suspicious features in a ≥ 1 -cm lesion, prompt MRI is advised. ²Low-risk patient: no known primary malignancy, hepatic dysfunction, or hepatic risk factors (see [Table 1](#)). ³High-risk patient: known primary malignancy with a propensity to metastasize to the liver, cirrhosis, and/or other hepatic risk factors (see [Table 1](#)). ⁴Follow-up MRI in 3 to 6 months. May need more immediate follow-up in some scenarios. CT is also acceptable in a patient with cancer who is due for routine CT surveillance. ⁵Benign features: sharp margin, homogeneous low attenuation (≤ 20 Hounsfield units [HU]) on noncontrast and/or portal venous-phase imaging, and characteristic features of hemangiomas, focal nodular hyperplasia (FNH), focal fatty sparing or deposition, or perfusional changes (see “[Commonly Encountered Benign Lesions](#)” subsection). If pseudoenhancement is present, a benign cyst may measure >20 HU; radiologists’ discretion is necessary. ⁶Suspicious features: ill-defined margins, heterogeneous density, mural thickening or nodularity, thick septa, and intermediate to high attenuation on portal venous-phase imaging (>20 HU, in the absence of pseudoenhancement). If pre- and postcontrast CT is available, enhancement >20 HU is a suspicious feature. To evaluate, prefer MRI. ⁷“Flash-filling” feature: uniform hyperenhancement relative to hepatic parenchyma on arterial-phase (including late arterial/early portal venous-phase) postcontrast imaging. If additional postcontrast phases are available to characterize lesion as benign (eg, hemangioma) or suspicious (eg, hepatocellular carcinoma), the lesion should be placed in one of those respective categories and not here. ⁸Incidental hepatic lesions that are >1.5 cm and do not have benign features should at least undergo prompt MRI. Direct biopsy (without MRI) may be appropriate in some scenarios. Differentiation of FNH from adenoma is important, especially if larger than 3 cm and subcapsular in location; for such patients, MRI with gadoxetate disodium is advised. ⁹If biopsy is pursued, core biopsy is preferred over fine-needle aspiration.

circumstances that are not represented in the algorithm, on the basis of the specific imaging appearance of the finding in question and patient characteristics. The algorithm content must be viewed as recommendations and should not be considered as “standard of care.”

NATURE AND SCOPE OF THE PROBLEM

Advances in cross-sectional imaging have led to the discovery of innumerable incidental liver lesions [2-4]. Such lesions will be detected in up to 30% of individuals older than 40 years [5-23]. Although most are benign, in many cases, further workup can be difficult to avoid. Conversely, it is well recognized that overdiagnosis of benign or indolent lesions places patients at risk for potentially dangerous and expensive follow-up care [24-29]. We provide recommendations for managing incidental liver lesions that appropriately balance the benefits and risks of further workup.

Definition of an Incidentally Detected Liver Lesion

An incidentally detected liver lesion is one that is identified in a patient imaged for an unrelated reason. As a result, we address patients with a wide spectrum of risk for a malignant liver lesion: from an otherwise healthy patient with right lower quadrant pain to a patient with a history of a primary malignancy or cirrhosis with pain after a motor vehicle collision. Although the latter patient is at increased risk for a malignant hepatic lesion—for metastasis or hepatocellular carcinoma, respectively—benign incidental liver lesions are also common in such patients, which makes management decisions particularly difficult in the absence of guidance [30-36]. Therefore, our recommendations are based on both the imaging appearance of the incidental lesion in question and the patient’s risk for having a malignant lesion (Fig. 1). Importantly, our algorithm was developed to distinguish benign from potentially malignant incidental findings, and not hepatic infections or abscesses, given that the latter are very likely to be associated with clinical signs or symptoms.

Risk Categories for Patients With Incidental Liver Lesions: “Low” Versus “High”

Our algorithm requires designation of patients as low risk or high risk for having a malignant hepatic lesion (Table 1). These categories, defined later, stratify the need for, and nature of, further workup. Within each category, “hepatic risk factors” refer to conditions that place patients at risk for primary hepatic malignancy and include hepatitis, alcoholism, nonalcoholic steatohepatitis,

sclerosing cholangitis, primary biliary cirrhosis, choledochal cysts, hemochromatosis and other hereditary hepatic conditions, and anabolic steroid use [37,38]. Low-risk patients have no known malignancy, hepatic dysfunction, or hepatic risk factors. Within the low-risk category, older patients (>40 years of age) are at higher risk than younger patients for malignancy [28]. High-risk patients have known malignancies with a propensity to metastasize to the liver, cirrhosis, and/or other hepatic risk factors. Therefore, when evaluating an incidental hepatic lesion, it is critical to know the patient’s clinical history.

Commonly Encountered Benign Lesions

Independent of patient-level risk, our recommendations are based on the premise that the absence of a benign signature in most incidental lesions ≥ 1 cm should prompt follow-up imaging with MRI (Fig. 1). Therefore, for most incidental lesions in our algorithm, radiologists should seek to identify definitively benign features to prevent unnecessary follow-up imaging.

The most commonly encountered benign hepatic lesions fall into four major categories: hepatic cysts, perfusional changes, hemangiomas, and focal nodular hyperplasias (FNHs) [39-41]. Hepatic cysts, particularly if ≥ 1 cm, can generally be characterized by their low attenuation (discussed further in the “Reporting Considerations” section). If < 1 cm, an accurate density measurement may not be attainable, a circumstance that is addressed in our algorithm by considering the patient’s underlying risk for malignancy (Fig. 1). Perfusional changes, including areas of fatty sparing of the liver, have characteristic locations and enhancement features, which generally enable their definitive characterization without further follow-up (also discussed further in the “Reporting Considerations” section) [42,43].

Table 1. Patient risk factors

Low-risk patients*
No known malignancy
No hepatic dysfunction
No hepatic risk factors†
High-risk patients
Known malignancy with a propensity to metastasize to the liver
Cirrhosis
Presence of hepatic risk factors†

*Within the low-risk category, older patients (>40 years of age) are at higher risk than younger patients for malignancy.

†Hepatic risk factors: hepatitis, nonalcoholic steatohepatitis, alcoholism, sclerosing cholangitis, primary biliary cirrhosis, choledochal cysts, hemochromatosis and other hereditary hepatic conditions, and anabolic steroid use.

Hepatic hemangiomas have an appearance that varies on the basis of the presence of contrast material and the available phase(s) of postcontrast imaging. On unenhanced CT, hemangiomas are similar in density to the blood pool. After the administration of contrast material, in the arterial phase, hemangiomas demonstrate peripheral, nodular enhancement, with progressive fill-in at later phases [41,44-46]. As a consequence, in the portal venous phase and thereafter, they are usually isodense or hyperdense relative to the normal liver [41,44-46]. Importantly, large hemangiomas may not enhance centrally on any postcontrast phase because of cystic degeneration, thrombosis, and/or fibrosis [41,44-46].

In the arterial phase, some smaller hemangiomas will uniformly enhance, rather than adhering to the aforementioned pattern of enhancement, an observation described as “flash-filling.” For this reason, if only the arterial phase (including late arterial/early portal venous phase) is available for evaluation, it can be challenging to distinguish hemangiomas from hypervascular neoplasms (metastases or hepatocellular carcinomas). Unlike hemangiomas, malignant neoplasms usually become hypodense relative to the normal liver in the portal venous phase [41,44-46]. Therefore, the availability of additional postcontrast imaging phases can help discern hemangiomas from hypervascular malignant neoplasms.

Enhancement characteristics of hemangiomas on MRI are analogous to those described for CT [41,44-46]. On unenhanced T1-weighted sequences, hemangiomas are low in signal intensity. On T2-weighted sequences, they are typically bright; internal fibrotic areas are dark [41,44-46].

FNH also has a CT appearance that varies on the basis of the presence of contrast material and the available phase(s) of postcontrast imaging. FNH is usually hypodense or isodense relative to the normal liver on unenhanced CT. A hypodense central scar is seen in one-third of cases [41,45,46]. After the administration of contrast material, FNH avidly enhances in the arterial phase. In the portal venous phase and thereafter, FNH becomes isodense; if present, the central scar enhances more gradually, and may appear hyperdense on delayed phases [41,44-46].

Enhancement characteristics of FNH on MRI are again similar to those described for CT. On unenhanced T1-weighted sequences, FNH is isointense relative to normal liver; on T2-weighted sequences, FNH is slightly hyperintense to isointense. The central scar, if present, is dark on T1-weighted sequences and bright on T2-weighted sequences [41,44-46].

Distinguishing FNH and hepatocellular adenoma (HCA) is important; HCAs can hemorrhage or transform into hepatocellular carcinoma, as described later. This is particularly important if the lesion is larger than 3 cm and subcapsular. For such patients, use of MRI with gadopentetate disodium is helpful because FNHs, unlike HCAs, typically demonstrate its uptake on hepatobiliary-phase imaging [47-52].

HCA

There are three primary subtypes of HCAs. From most to least frequent, they are inflammatory HCA, hepatocyte nuclear factor-1 α inactivated HCA, and β -catenin-activated HCA [53-56]. Inflammatory HCA carries the greatest risk for hemorrhage, whereas β -catenin-activated HCA carries the greatest risk for malignancy [53-56]. All subtypes are associated with arterial-phase enhancement; however, enhancement characteristics in subsequent phases vary [53-56].

Comparisons With Prior Studies

Comparisons with prior imaging are critically important to determine if a hepatic lesion is new or growing. Importantly, review of prior ultrasound, chest CT, PET/CT and PET/MRI, and/or spinal CT or MRI examinations can also help establish stability. Our algorithm does not explicitly incorporate growth; this is because thresholds for intervention may vary substantially across patient risk categories and imaging features. However, in general, absence of growth over a 1-year time period favors the presence of a benign lesion.

Biopsy of Liver Lesions

Liver biopsy is commonly used when follow-up MRI cannot confirm the presence of liver metastases or a primary hepatic malignancy and when such knowledge would affect subsequent management decisions. Importantly, the risks for morbidity (about 0.5%) and mortality (about 0.05%) should be considered when making a decision about the need for, and technique of, biopsy (core versus fine-needle aspiration) [26,29,57]. Characteristic imaging features of hepatocellular carcinoma may obviate the need for biopsy in many patients [57]. However, personalization of treatment may require tissue to be obtained.

REPORTING CONSIDERATIONS

To optimize lesion characterization and management recommendations, the following elements should be considered when reporting an incidental liver lesion detected on CT. Although each element does not require

mention for every incidental hepatic lesion (eg, a simple cyst), radiologists are strongly encouraged to address those elements that guide specific follow-up recommendations.

1. Lesion size
2. Lesion attenuation
3. Lesion homogeneity versus complexity
4. Lesion enhancement pattern
5. Lesion margin
6. Lesion multiplicity
7. Lesion growth pattern
8. Lesion location

Lesion Size

Most liver lesions <1 cm are benign [41,58,59]. Even in high-risk patients, such lesions are commonly benign; however, a potentially new lesion in a high-risk patient warrants follow-up (Fig. 1) [30-36].

Lesion Attenuation

In low-risk patients, lesions with the following characteristics are considered cysts: -10 to $+20$ Hounsfield units (HU), homogeneous, sharply marginated and without enhancement, mural thickening or nodularity, or septations [39,41]. Importantly, liver metastases can be cystic (eg, in ovarian cancer and gastrointestinal stromal tumors). Therefore, low density is not definitive for a simple cyst in certain patients with cancer [40].

Lesion Homogeneity Versus Complexity

To evaluate the homogeneity versus complexity (heterogeneity) of an incidental hepatic lesion on CT, multiple regions of interest should be placed throughout the lesion, including the highest density areas [41]. Wall thickening or peripheral enhancement, mural nodules, and thick septa raise the likelihood of malignancy [41]. It should be recognized that in the appropriate clinical setting, these features could also indicate an abscess.

Lesion Enhancement Pattern

Hepatic cysts should enhance ≤ 20 HU after the administration of contrast material. However, in small lesions, attenuation measurements can be inaccurate; moreover, it is uncommon to have both unenhanced and postcontrast CT available to evaluate an incidental liver lesion. To verify the presence of a cyst, MRI is superior to CT: ascertainment of no enhancement versus enhancement is more reliable, and additional T2-weighted sequences and diffusion-weighted imaging are

helpful for confirmation [45]. Hemangiomas and FNH have characteristic enhancement features, described earlier.

Importantly, the “flash-filling” property of a lesion—uniform enhancement on arterial-phase imaging (including late arterial/early portal venous-phase imaging)—should be reported, particularly when it is the sole detectable feature of the lesion. In our algorithm, such lesions are managed separately in instances in which additional multiphase imaging is not available to enable their further, definitive characterization (eg, as hemangiomas or hepatocellular carcinomas) (Fig. 1).

Lesion Margin

Benign lesions usually have smooth margins; malignant lesions may have smooth, irregular, or ill-defined margins [41].

Lesion Multiplicity

The presence of multiple liver lesions in patients with cancer often raises suspicion for metastatic disease. However, benign entities such as multiple biliary hamartomas are similarly associated with multiplicity [39,41]. If multiple lesions are present, index lesions that are largest in size and/or demonstrate the most concerning features should be identified to guide follow-up.

Lesion Growth Pattern

Growth of a hepatic lesion raises concern for malignancy, but benign and malignant lesions can grow over time [59-61]. Although our algorithm does not explicitly incorporate growth, in general, absence of growth over a 1-year time period strongly favors the presence of a benign lesion.

Lesion Location

Specific regions of the liver are susceptible to effects of perfusional changes and fatty infiltration or sparing; such effects may mimic liver lesions [62-65]. Peripherally, so-called THADs (transient hepatic attenuation differences, seen on CT) and THIDs (transient hepatic intensity differences, seen on MRI) reflect changes in enhancement of the parenchyma due to relative differences in hepatic arterial versus portal venous supply. Near the falciform ligament and the gallbladder fossa, alterations in venous drainage can result in focal fatty deposition or sparing [42,43,62-65].

INCLUSION AND EXCLUSION CRITERIA FOR USE OF THE ALGORITHM

The algorithm should only be applied to incidental liver lesions in asymptomatic adult patients (≥ 18 years of age) for whom CT was requested for an unrelated reason. As described earlier, the algorithm is designed for use in patients with varied underlying risk levels (low versus high) for a malignant hepatic lesion. However, the algorithm should not be applied when index CT (ie, that which demonstrates the incidental lesion) was requested to evaluate a known or suspected liver lesion or hepatic abnormality. There are some hepatic lesions that present with associated vascular invasion, biliary dilation, or adenopathy. Patients with these associated findings should be referred directly for oncologic evaluation.

IMPLICATIONS OF IMAGING AND CLINICAL FEATURES

Five Basic Principles of the Algorithm

1. In a low-risk patient, an incidental hepatic lesion < 1 cm generally does not require further workup and can be considered benign. Radiologists should feel comfortable deviating from this recommendation in instances in which such lesions have suspicious features (ie, ill-defined margins, heterogeneous density, mural thickening or nodularity, or thick septa). In these instances, MRI should be considered.
2. Incidental hepatic lesions that are ≥ 1 cm and have distinctly benign imaging features do not require follow-up. Such features include sharp margin, homogeneous low attenuation (≤ 20 HU) on non-contrast or portal venous-phase imaging, or characteristic features of hemangiomas, FNH, or perfusional changes (including focal fatty sparing or deposition). If pseudoenhancement is present, then a benign cyst may measure > 20 HU; radiologists' discretion is necessary.
3. Incidental hepatic lesions that are ≥ 1 cm and have suspicious imaging features require further workup with prompt MRI or biopsy, depending on the lesion's size and features and the patient's risk level. Suspicious imaging features include ill-defined margins, heterogeneous density, mural thickening or nodularity, thick septa, and intermediate to high attenuation on portal venous-phase imaging (> 20 HU, in the absence of pseudoenhancement). If pre- and postcontrast CT is available, enhancement > 20 HU is a suspicious feature.
4. In this algorithm, "flash-filling" lesions are classified separately as incidental liver lesions that are characterized by uniform enhancement on arterial-phase

imaging (including late arterial/early portal venous-phase imaging), and for which multiphasic imaging is not available to enable definitive characterization. In low-risk patients, they are generally benign; MRI is suggested for follow-up only when they exceed 1.5 cm. In high-risk patients, MRI is advised routinely because of a higher probability of malignancy. Nevertheless, even in patients with cirrhosis with small, wedge-shaped hypervascular lesions, the vast majority of such lesions are benign [66].

5. If inadequate imaging is available to ascertain the presence of benign versus suspicious features in a ≥ 1 cm lesion (eg, a homogeneous 3-cm, 40-HU incidental hepatic lesion with a sharp margin on a non-contrast CT), prompt MRI should be considered for complete characterization of the lesion.

OVERVIEW OF THE ALGORITHM

Low-Risk Patients (Fig. 1)

Incidental Liver Lesion ≤ 1.5 cm. In low-risk patients, incidental liver lesions less than 1 cm generally do not require further workup and can be considered benign. Incidental liver lesions that are 1.0 to 1.5 cm and have benign or flash-filling features also do not require further workup. Prompt MRI is advised for lesions with suspicious features that are 1.0 to 1.5 cm.

Incidental Liver Lesion > 1.5 cm. In low-risk patients, for incidental liver lesions that are greater than 1.5 cm and have benign imaging features, no further workup is necessary. If the lesion has suspicious or flash-filling features, prompt MRI is advised.

High-Risk Patients (Fig. 1)

Incidental Liver Lesion ≤ 1.5 cm. In high-risk patients with incidental liver lesions less than 1 cm, MRI is advised in 3 to 6 months to both characterize the lesion and document the presence or absence of growth. For lesions that are 1.0 to 1.5 cm and have benign features, no further workup with MRI is necessary; for lesions of this size with suspicious or flash-filling features, we recommend prompt MRI.

Incidental Liver Lesion > 1.5 cm. In high-risk patients, for incidental liver lesions that are greater than 1.5 cm and do not have benign imaging features, at minimum, we recommend prompt MRI. For large and highly suspicious lesions (eg, a 3-cm lesion that is likely to be a solitary colorectal metastasis), direct referral to biopsy

may be considered, depending on the clinical scenario. In general, core biopsy is preferred over fine-needle aspiration and is often necessary for the accurate diagnosis of a primary hepatocellular neoplasm.

IMAGING PROTOCOL OPTIMIZATION

CT and MRI

When performed for liver lesion evaluation, a CT protocol may include multiple phases: unenhanced imaging and late arterial, portal venous, and delayed-phase post-contrast imaging. If a dual-energy CT (DECT) examination is performed, the unenhanced CT phase should be eliminated [67-69]. In general, the unenhanced CT phase should be eliminated whenever possible, as it does not provide additional information in many scenarios.

We favor MRI over CT for the characterization of an incidental liver lesion. In general, gadolinium blood pool agents should be used rather than hepatobiliary agents; however, to distinguish FNH and HCA, gadoxetate disodium is recommended, as described earlier. In most cases, MRI enables better characterization of a lesion's internal features, and ascertainment of enhancement is more reliable relative to CT. In addition, radiation exposure is avoided.

DECT

Depending on the method used to process images, if a DECT examination is performed on a DECT-capable unit, it may identify the presence and even quantity of iodine within a lesion. Confirming iodine content demonstrates that a lesion has blood perfusion, rather than simply being a hyperdense lesion from another cause, such as proteinaceous material, calcium, or iron. A color-coded iodine map may be generated to localize foci of enhancement. Iodine can also be detected by comparing the density on different simulated monoenergetic images. On virtual unenhanced series, an iodine-containing lesion would be low attenuation, and dense lesions from other causes would remain higher in attenuation. The ability to generate virtual unenhanced series from a postcontrast examination may eliminate the need to perform a conventional unenhanced series. Using this technology, various types of lesions can be characterized as nonenhancing, including hyperattenuating hepatic cysts and bile duct hamartomas, as opposed to enhancing lesions such as metastases and other malignancies [67,68]. However, if an indeterminate lesion is found on conventional CT, MRI may be preferred over DECT [67-71].

Reduced-Dose CT Scanning

We recommend use of dose-reduction techniques that are responsible and tailored to the clinical question at hand. Detection and characterization of small liver lesions can be a challenging task when aggressive dose reduction techniques have been used. As such, particularly in high-risk patients, we emphasize the need to maintain diagnostic-quality imaging [72-74].

PET/CT and PET/MR Evaluation

In larger hepatic lesions (>1 cm), PET/CT and PET/MR have precluded the need for biopsy in some patients [75-77].

CONCLUSIONS

Hepatic incidental findings are a common problem on CT; we provide an algorithm for their management that is tailored to the patient's risk for malignancy and the lesion's specific imaging features.

Four recommendations that define our updated algorithm include (1) to forgo workup of incidental hepatic lesions that are less than 1 cm in low-risk patients, (2) to forgo workup of lesions with distinctly benign features (regardless of patient risk level), (3) to pursue workup of lesions that are ≥ 1 cm and without distinctly benign features in high-risk patients, and (4) to use MRI for further workup.

We hope that this update provided by the Liver Subcommittee of the IFC will help accurately characterize most incidental hepatic lesions that are detected on CT and minimize the frequency of unnecessary patient workup.

TAKE-HOME POINTS

- Forgo workup of incidental hepatic lesions less than 1 cm in low-risk patients.
- Forgo workup of incidental hepatic lesions with distinctly benign features regardless of risk level.
- Pursue workup of incidental hepatic lesions that are ≥ 1 cm and without distinctly benign features in high-risk patients.

ACKNOWLEDGMENTS

The ACR thanks the Society of Abdominal Radiology and the Society of Computed Body Tomography and Magnetic Resonance for their contributions to and endorsement of the recommendations in this white paper. In addition, we are grateful to Brian Herts, MD (IFC

Renal Subcommittee chair), William Mayo-Smith, MD (IFC Adrenal Subcommittee chair), and Alec Megibow, MD (IFC Pancreas Subcommittee chair), who provided substantial input and feedback for this white paper as members of the ACR IFC's Executive Committee.

REFERENCES

- Berland LL, Silverman SG, Gore RM, et al. Managing incidental findings on abdominal CT: white paper of the ACR incidental findings committee. *J Am Coll Radiol* 2010;7:754-73.
- Gore RM, Thakrar KH, Wenzke DR, et al. That liver lesion on MDCT in the oncology patient: is it important? *Cancer Imaging* 2012;12:373-84.
- Gore RM, Newmark GM, Thakrar KH, et al. Hepatic incidentalomas. *Radiol Clin North Am* 2011;49:291-322.
- Nakamura N, Tsunoda H, Takahashi O, et al. Frequency and clinical significance of previously undetected incidental findings detected on computed tomography simulation scans for breast cancer patients. *Int J Radiat Oncol Biol Phys* 2012;84:602-5.
- Kaltenbach TE, Engler P, Kratzer W, Oeztuerk S, et al. Prevalence of benign focal liver lesions: ultrasound investigation of 45,319 hospital patients. *Abdom Radiol (NY)* 2016;41:25-32.
- Pooler BD, Kim DH, Pickhardt PJ. Indeterminate but likely unimportant extracolonic findings at screening CT colonography (C-RADS category E3): incidence and outcomes data from a clinical screening program. *AJR Am J Roentgenol* 2016;207:996-1001.
- Pooler BD, Kim DH, Pickhardt PJ. Screening CT colonography: incidence and outcomes data from a clinical screening program. *AJR Am J Roentgenol* 2016;206:313-8.
- Quattrocchi CC, Giona A, Di Martino AC, et al. Extra-spinal incidental findings at lumbar spine MRI in the general population: a large cohort study. *Insights Imaging* 2013;4:301-8.
- Dietrich CF, Jensen C. Focal liver lesion, incidental finding. *Dtsch Med Wochenschr* 2012;137:2099-116.
- Choi SH, Kwon HJ, Lee SY, et al. Focal hepatic solid lesions incidentally detected on initial ultrasonography in 542 asymptomatic patients. *Abdom Radiol (NY)* 2016;41:265-72.
- Nguyen XV, Davies L, Eastwood JD, Hoang JK. Extrapulmonary findings and malignancies in participants screened with chest CT in the National Lung Screening Trial. *J Am Coll Radiol* 2017;14:324-30.
- Shuaib W, Johnson JO, Salastekar N, et al. Incidental findings detected on abdomino-pelvic multidetector computed tomography performed in the acute setting. *Am J Emerg Med* 2014;32:36-9.
- Kelly ME, Heeney A, Redmond CE, et al. Incidental findings detected on emergency abdominal CT scans: a 1-year review. *Abdom Imaging* 2015;40:1853-7.
- Koea JB. Hepatic incidentaloma: the rule of tens. *HPB (Oxford)* 2013;15:379-83.
- Maxwell AW, Keating DP, Nickerson JP. Incidental abdominopelvic findings on expanded field-of-view lumbar spinal MRI: frequency, clinical importance, and concordance in interpretation by neuroimaging and body imaging radiologists. *Clin Radiol* 2015;70:161-7.
- Hanna TN, Shekhani H, Zygmunt ME, et al. Incidental findings in emergency imaging: frequency, recommendations, and compliance with consensus guidelines. *Emerg Radiol* 2016;23:169-74.
- Morgan AE, Berland LL, Ananyev SS, et al. Extraordinary incidental findings on CT for hematuria: the radiologist's role and downstream cost analysis. *AJR Am J Roentgenol* 2015;204:1160-7.
- Samim M, Goss S, Luty S, Weinreb J, Moore C. Incidental findings on CT for suspected renal colic in emergency department patients: prevalence and types in 5,383 consecutive examinations. *J Am Coll Radiol* 2015;12:63-9.
- Ather MH, Memon W, Rees J. Clinical impact of incidental diagnosis on non-contrast-enhanced helical CT for acute ureteral colic. *Semin Ultrasound CT MRI* 2005;26:20-3.
- Semaan A, Branchi V, Marowsky AL, et al. Incidentally detected focal liver lesions—a common clinical management dilemma revisited. *Anticancer Res* 2016;36:2923-32.
- Pickhardt PJ, Taylor AJ. Extracolonic findings identified in asymptomatic adults at screening colonoscopy. *AJR Am J Roentgenol* 2006;186:718-28.
- Green DE, Woodward PJ. The management of indeterminate incidental findings detected at abdominal CT. *Semin Ultrasound CT MRI* 2005;26:2-13.
- Behbahani S, Mittal S, Patlas MN, et al. "Incidentalomas" on abdominal and pelvic CT in emergency radiology: literature review and current management recommendation. *Abd Radiol* 2017;42:1046-61.
- Collin P, Rinta-Kiikka I, Rätty S, et al. Diagnostic workup of liver lesions: too long time with too many examinations. *Scand J Gastroenterol* 2015;50:355-9.
- Venkatesh SK, Chandan V, Roberts LR. Liver masses: a clinical, radiologic, and pathologic perspective. *Clin Gastroenterol Hepatol* 2014;12:1414-29.
- Strauss E, Ferreira Ade S, França AV, et al. Diagnosis and treatment of benign liver nodules: Brazilian Society of Hepatology (SBH) recommendations. *Arq Gastroenterol* 2015;52(Suppl 1):47-54.
- Liu CL, Fan ST, Lo CM, et al. Hepatic resection for incidentaloma. *J Gastrointest Surg* 2004;8:785-93.
- Tsung A, Geller DA. Workup of the incidental liver lesion. *Adv Surg* 2005;39:331-41.
- Seeff LB, Everson GT, Morgan TR, et al. Complication rate of percutaneous liver Biopsies among persons with advanced chronic liver disease in the HALT-C trial. *Clin Gastroenterol Hepatol* 2010;8:877-83.
- Krakora GA, Coakley FV, Williams G, et al. Small hypoattenuating hepatic lesions at contrast-enhanced CT: Prognostic importance in patients with breast cancer. *Radiology* 2004;233:667-73.
- Lim GH, Koh DC, Cheong WK, et al. Natural history of small, "indeterminate" hepatic lesions in patients with colorectal cancer. *Dis Colon Rectum* 2009;52:1487-91.
- Patterson SA, Khalil HI, Panicek DM. MRI evaluation of small hepatic lesions in women with breast cancer. *AJR Am J Roentgenol* 2006;187:307-12.
- Jones EC, Chezmar JL, Nelson RC, et al. The frequency and significance of small (less than or equal to 15 mm) hepatic lesions detected by CT. *AJR Am J Roentgenol* 1992;158:535-9.
- Schwartz LH, Gandras EJ, Colangelo S, et al. Prevalence and importance of small hepatic lesions found at CT in patients with cancer. *Radiology* 1999;210:71-4.
- Jang HJ, Lim HK, Lee WJ, et al. Small hypoattenuating lesions in the liver on single-phase helical CT in preoperative patients with gastric and colorectal cancer: prevalence, significance, and differentiating features. *J Comput Assist Tomogr* 2002;26:718-24.
- Khalil HI, Patterson SA, Panicek DM. Hepatic lesions deemed too small to characterize at CT: prevalence and importance in women with breast cancer. *Radiology* 2005;235:872-8.
- Fateen W, Ryder SD. Screening for hepatocellular carcinoma: patient selection and perspectives. *J Hepatocell Carcinoma* 2017;4:71-9.
- Balogh J, Victor D, Asham EH, et al. Hepatocellular carcinoma: a review. *J Hepatocell Carcinoma* 2017;3:41-53.
- Mortele K, Peters HE. Multimodality imaging of common and uncommon cystic focal liver lesions. *Semin Ultrasound CT MRI* 2009;30:368-86.
- Labib PL, Aroori S, Bowles M, et al. Differentiating simple hepatic cysts from mucinous cystic neoplasms: radiological features, cyst fluid tumour marker analysis and multidisciplinary team outcomes. *Dig Surg* 2017;34:36-42.

41. Ros P, Erturk SM. Benign tumors of the liver. In: Gore RM, Levine MS, eds. *Textbook of gastrointestinal radiology*. 4th ed. Philadelphia: Elsevier; 2015:1608-28.
42. Jang JK, Jang HJ, Kim JS, et al. Focal fat deposition in the liver: diagnostic challenges on imaging. *Abdom Radiol* 2017;42:1667-78.
43. Gore RM, Ba-Ssalamah A. Vascular disorders of the liver and splanchnic circulation. In: Gore RM, Levine MS, eds. *Textbook of gastrointestinal radiology*. 4th ed. Philadelphia: Elsevier; 2015: 1676-705.
44. Chiche L, Adam JP. Diagnosis and management of benign liver tumors. *Semin Liver Dis* 2013;33:236-47.
45. Cogley JR, Miller FH. MR imaging of benign focal liver lesions. *Radiol Clin North Am* 2014;52:657-82.
46. Kamaya A, Maturen KE, Tye GA, Liu YI. Hypervascular liver lesions. *Semin Ultrasound CT MRI* 2009;387-407.
47. McInnes MD, Hibbert RM, Inácio JR, Schieda N. Focal nodular hyperplasia and hepatocellular adenoma: accuracy of gadoteric acid-enhanced MR imaging—a systematic review. *Radiology* 2015;277: 413-23.
48. Burgio MD, Ronot M, Salvaggio G, Vilgrain V, et al. Imaging of hepatic focal nodular hyperplasia: pictorial review and diagnostic strategy. *Semin Ultrasound CT MR* 2016;37:511-24.
49. Merkle EM, Zech CJ, Bartolozzi C, et al. Consensus report from the 7th International Forum for Liver Magnetic Resonance Imaging. *Eur Radiol* 2016;26:674-82.
50. Tsurusaki M, Sofue K, Murakami T. Current evidence for the diagnostic value of gadoteric acid-enhanced magnetic resonance imaging for liver metastasis. *Hepatol Res* 2016;46:853-61.
51. Guglielmo FF, Mitchell DG, Roth CG, Deshmukh S. Hepatic MR imaging techniques, optimization, and artifacts. *Magn Reson Imaging Clin N Am* 2014;22:263-82.
52. Ronot M, Vilgrain V. Imaging of benign hepatocellular lesions: current concepts and recent updates. *Clin Res Hepatol Gastroenterol* 2014;38: 681-8.
53. Agrawal S, Agarwal S, Arnsen T, Saini S, Belghiti J. Management of hepatocellular adenoma: recent advances. *Clin Gastroenterol Hepatol* 2015;13:1221-30.
54. Dharmana H, Saravana-Bawan S, Giris S, Low G. Hepatocellular adenoma: imaging review of the various molecular subtypes. *Clin Radiol* 2017;72:276-85.
55. Cristiano A, Dietrich A, Spina JC, et al. Focal nodular hyperplasia and hepatic adenoma: current diagnosis and management. *Updates Surg* 2014;66:9-21.
56. Yoneda N, Matsui O, Kitao A, et al. Benign hepatocellular nodules: hepatobiliary phase of gadoteric acid-enhanced MR imaging based on molecular background. *Radiographics* 2016;36:2010-27.
57. Pang EH, Harris AC, Chang SD. Approach to the solitary liver lesion: imaging and when to biopsy. *Can Assoc Radiol J* 2016;67:130-48.
58. Marrero JA, Ahn J, Rajender Reddy K, Americal College of Gastroenterology. Incidentally detected focal liver lesions—a common clinical management dilemma revisited. *Am J Gastroenterol* 2014;109: 1328-47.
59. Lamba R, Fananapazir G, Corwin MT, Khatri VP. Diagnostic imaging of hepatic lesions in adults. *Surg Oncol Clin N Am* 2014;23:789-820.
60. Ros P, Erturk SM. Malignant liver tumors. In: Gore RM, Levine MS, eds. *Textbook of gastrointestinal radiology*. 4th ed. Philadelphia: Elsevier; 2015:1561-607.
61. Dietrich CF, Sharma M, Gibson RN, et al. Fortuitously discovered liver lesions. *World J Gastroenterol* 2013;19:3173-88.
62. Tian JL, Zhang JS. Hepatic perfusion disorders: etiopathogenesis and related diseases. *World J Gastroenterol* 2006;28:3265-70.
63. Anderson SW, Kruskal JB, Kane RA. Benign hepatic tumors and iatrogenic pseudotumors. *Radiographics* 2009;29:211-29.
64. Desser TS. Understanding transient hepatic attenuation differences. *Semin Ultrasound CT MRI* 2009;30:408-17.
65. Colegrande S, Centi N, Galdiero R, et al. Transient hepatic intensity differences: part 1. Those associated with focal lesions. *AJR Am J Roentgenol* 2007;188:154-9.
66. Holland AE, Hecht EM, Hahn WY, et al. Importance of small (< or = 20-mm) enhancing lesions seen only during the hepatic arterial phase on MR imaging of the cirrhotic liver: evaluation and comparison with whole explanted liver. *Radiology* 2005;237:938-44.
67. Graser A, Johnson TR, Chandrana H, Macari M. Dual energy CT: preliminary observations and potential clinical applications in the abdomen. *Eur Radiol* 2009;19:13-23.
68. Li Y, Li Y, Jackson A, Li X, et al. Comparison of virtual unenhanced CT images of the abdomen under different iodine flow rates. *Abdom Radiol (NY)* 2017;42:312-21.
69. De Cecco CN, Muscogiuri G, Schoepf UJ, et al. Virtual unenhanced imaging of the liver with third-generation dual-source dual-energy CT and advanced modeled iterative reconstruction. *Eur J Radiol* 2016;85: 1257-64.
70. Wortman JR, Bunch PM, Fulwadhva UP, et al. Dual-energy CT of incidental findings in the abdomen: can we reduce the need for follow-up imaging? *AJR Am J Roentgenol* 2016;207:W1-11.
71. Slebocki K, Kraus B, Chang DH, et al. Incidental findings in abdominal dual-energy computed tomography: correlation between true noncontrast and virtual noncontrast images considering renal and liver cysts and adrenal masses. *J Comput Assist Tomogr*. In press.
72. Pooler BD, Lubner MG, Kim DH, et al. Prospective evaluation of reduced dose computed tomography for the detection of low-contrast liver lesions: direct comparison with concurrent standard dose imaging. *Eur Radiol* 2017;27:2055-66.
73. Pickhardt PJ, Lubner MG, Kim DH, et al. Abdominal CT with model-based iterative reconstruction (MBIR): initial results of a prospective trial comparing ultralow-dose with standard-dose imaging. *AJR Am J Roentgenol* 2012;199:1266-74.
74. Mayo-Smith WW, Hara AK, Mahesh M, Sahani DV, Pavlicek W. How i do it: managing radiation dose in CT. *Radiology* 2014;273: 657-72.
75. Basu S, Alavi A. PET-based personalized management in clinical oncology: an unavoidable path for the foreseeable future. *PET Clin* 2016;11:203-7.
76. Paspulati RM, Gupta A. PET/MR imaging in cancers of the gastrointestinal tract. *PET Clin* 2016;11:403-23.
77. Catalano OA, Masch WR, Catana C, et al. An overview of PET/MR, focused on clinical applications. *Abdom Radiol (NY)* 2017;42: 631-44.



Credits awarded for this enduring activity are designated “SA-CME” by the American Board of Radiology (ABR) and qualify toward fulfilling requirements for Maintenance of Certification (MOC) Part II: Lifelong Learning and Self-assessment. Scan the QR code to access the SA-CME activity or visit <http://bit.ly/ACRSACME>.