

Technical note

Removal of a root from the maxillary sinus using functional endoscopic sinus surgery

F. Chandrasena^{a,*}, A. Singh^b, B.G. Visavadia^a

^a Regional Oral and Maxillofacial Surgery/Orthodontics, North West London Hospitals NHS Trust, Northwick Park Hospital and Central Middlesex Hospital, Watford Road, Harrow HA1 3UJ, United Kingdom

^b Ear, Nose and Throat Department, North West London Hospitals NHS Trust, Northwick Park Hospital and Central Middlesex Hospital, Watford Road, Harrow HA1 3UJ, United Kingdom

Accepted 10 September 2009

Available online 21 October 2009

Keywords: Maxillary sinus; Functional endoscopic sinus surgery; Tooth

Removal of teeth where there is a close communication between the maxillary sinus and the oral cavity can lead to the root being dislodged into the maxillary sinus, creating an oroantral communication.

Usually access to the root can be through the socket or by a Caldwell-Luc procedure. Approach through the socket requires a mucoperiosteal flap at the site of the socket, and removal of bone until the maxillary sinus is exposed and the root is identified. However, if the root is higher up within the air space of the maxillary sinus, the Caldwell-Luc technique may be more suitable to provide better access through the canine fossa.

Both methods are moderately invasive and have good rates of success. We describe a case and technique where functional endoscopic sinus surgery was used to retrieve a root from the maxillary sinus.

After a forceps extraction of the UL6 (26) in general practice, the mesiobuccal root became detached and was displaced into the maxillary sinus. The patient presented to our department where an orthopantogram (OPG) showed the root located in the superior extent of the maxillary sinus. Computed tomography (CT) showed that the fragment, measuring 8 mm, was in the superior medial aspect of the left maxillary sinus close to the ethmoidal sinuses (Fig. 1). The

nasal anatomy had been difficult to see on OPG and we felt therefore that CT was justified.

Considering the curvature of the inferior concha, intraoral access would be difficult and traumatic so we decided to approach the root through the nose using functional endoscopic sinus surgery under general anaesthesia.

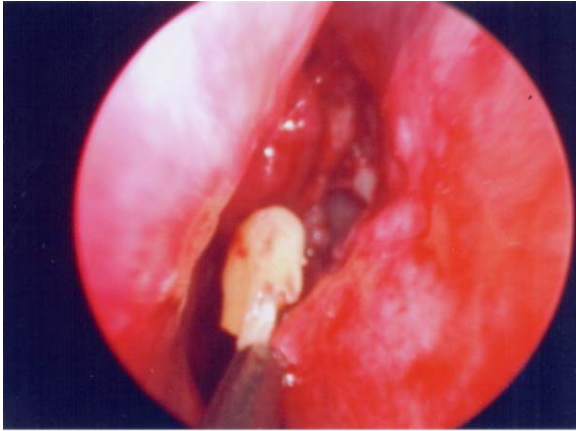
We used the surgical expertise of our ear, nose, and throat colleagues in this procedure as the zero degree endoscope was inserted into the nose through the left nostril, and was manipulated past the inferior concha into the middle meatus where the maxillary sinus was entered through the opening

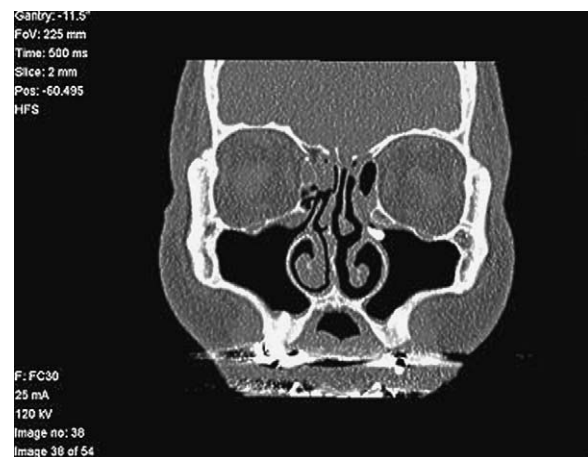

Fig. 1. Computed tomogram (coronal view) showing the root as an 8 mm radio opacity in the left superior medial aspect of the maxillary sinus.

* Corresponding author. Tel.: +44 208 864 3232.

E-mail address: franceschandrasena@googlemail.com (F. Chandrasena).



NORTHWICK PARK HOSPITAL

Fig. 2. Image showing the root being retrieved from within the maxillary sinus.

of the uncinate process. The root was identified within the ostium of the maxillary sinus and was easily removed (Fig. 2).

The patient was discharged on the same day with simple analgesia, and made a complete recovery with minimal discomfort.

Functional endoscopic sinus surgery is a minimally invasive technique of dissection in which the air cells and ostia of the paranasal sinuses are opened under direct vision with the use of an endoscope.¹ Outcome is generally good with complications reported at less than 1%.^{2,3}

On reflection the technique seems to be relatively simple and, with future training could become a skill that the maxillofacial surgeon could add to his armamentarium.

References

1. Swift AC. Functional endoscopic sinus surgery. *Br J Hosp Med* 1996;**55**:554–8.
2. Luong A, Marple BF. Sinus surgery: indications and techniques. *Clin Rev Allergy Immunol* 2006;**30**:217–22.
3. Chiu AG, Kennedy DW. Surgical management of chronic rhinosinusitis and nasal polyposis: a review of the evidence. *Curr Allergy Asthma Rep* 2004;**4**:486–9.