

Cystic Expansile Masses of the Maxilla: Differential Diagnosis with CT and MR

Moon Hee Han, Kee Hyun Chang, Chul Hee Lee, Dong Gyu Na, Kyung Mo Yeon, and Man Chung Han

PURPOSE: To describe the CT and MR findings of various entities causing cystic expansile masses in the maxilla and the significance of the cortical bony plate between the lesions and sinus cavities in the differential diagnosis. **METHODS:** CT findings of 28 patients with cystic expansile masses of the maxilla, including 20 cases of maxillary mucocoeles (17 postoperative mucocoeles, 2 mucocoeles of a septated compartment of the maxillary sinuses, and 1 maxillary antral mucocoele with inflammatory ostial obstruction), 3 cases of fissural cyst, 4 cases of odontogenic cyst, and 1 case of maxillary cystic ameloblastoma, were reviewed. Six cases (4 postoperative mucocoeles and 2 odontogenic cysts) were also examined with MR. **RESULTS:** A thin bony plate between the lesion and antral cavity was demonstrated in every extraantral lesion (ameloblastoma, fissural cysts, and odontogenic cysts) and distinguishing these abnormalities from the antral lesions (mucocoeles). All mucocoeles showed findings of antral lesions except 2 cases of mucocoeles at the septated compartments of the sinuses, in which thin bony septa were identified between the lesions and remaining sinus cavities. Postoperative mucocoeles showed hyperostotic and retracted bony walls caused by previous surgery and localized erosion of bony walls with localized bulging of the cystic masses in every case. **CONCLUSION:** In the differential diagnosis of cystic masses of the maxilla, careful identification of the bony walls of the antrum and bony septa may allow one to locate the origin of a mass as antral or extraantral. This is important to an appropriate differential diagnosis.

Index terms: Maxilla; Paranasal sinuses; Temporomandibular joint, cysts

AJNR Am J Neuroradiol 16:333-338, February 1995

Diverse disease entities may cause masses in the maxilla. Malignant tumors of the maxillary sinus and benign conditions including fibro-osseous disease, mucocoele, and various odontogenic cystic lesions may present with expansile maxillary masses (1-4). With computed tomography (CT), solid tumor or fibroosseous disease can be easily distinguished from cystic lesion, which shows homogeneously low attenuation with frequent remodeling of bony walls. The exact site of origin is very important in the differential diagnosis. A lesion of antral origin is likely to be a maxillary mucocoele with various

possible causes; for extraantral maxillary cystic lesions, the probable diagnoses are fissural cysts, cystic tumors of the maxilla, or cystic masses of dental origin.

We reviewed the CT and magnetic resonance (MR) findings in the patients with cystic expansile masses of the maxilla with special attention to the bone changes and mode of expansion, which may represent the site of origin of the lesion and can be useful in the differential diagnosis.

Materials and Methods

CT and/or MR findings of 28 patients with cystic expansile masses of the maxilla were reviewed. The diagnosis was confirmed by surgery and histopathologic examinations in each patient. Twenty cases of maxillary sinus mucocoeles (17 cases of postoperative mucocoeles after Caldwell-Luc procedures, 2 cases of mucocoeles that arose in septated compartments of the maxillary sinuses, and 1 case of maxillary antral mucocoele secondary to ostial obstruction), 4 cases of odontogenic cyst (2 dentigerous cysts and two odontogenic keratocysts), 3 cases of fissural

Received February 2, 1994; accepted after revision June 17.

From the Departments of Diagnostic Radiology (M.H.H., K.H.C., D.G.N., K.M.Y., M.C.H.) and Otolaryngology (C.H.L.), Seoul National University College of Medicine, Korea.

Address reprint requests to Moon Hee Han, MD, Department of Diagnostic Radiology, Seoul National University Hospital, 28, Yeongun-dong, Chongro-ku, Seoul 110-744, Korea.

AJNR 16:333-338, Feb 1995 0195-6108/95/1602-0333
© American Society of Neuroradiology

cysts (globulomaxillary cyst), and 1 case of maxillary cystic ameloblastoma were included in this series. Seventeen patients with postoperative mucocoeles, including 3 with bilateral lesions, had histories of Caldwell-Luc operations 9 to 21 years before the symptom presentation. The cases of postoperative mucocoeles without significant expansion on CT or MR were excluded. Four cases of postoperative mucocoeles with multicompartimentalized appearance on CT and 1 case of odontogenic cyst were also examined with MR, and one case with odontogenic cyst was examined only with MR.

All CT scanning was performed at a GE 9800 unit (General Electric Medical, Milwaukee) as routine contrast-enhanced study, with 5-mm-thick contiguous sections in axial and coronal planes. The images were obtained with standard algorithm, and coronal images with bone algorithm were also obtained in three cases. MR imaging was performed with either a 1.5-T superconducting (Magnetom SP, Siemens, Erlangen, Germany) ($n = 2$), 2.0-T superconducting (Spectro-20000, GoldStar, Seoul, Korea) ($n = 2$), or 0.5-T superconducting (Supertec-5000, GoldStar, Seoul, Korea) ($n = 2$) unit. MR images were all obtained with spin-echo techniques in axial and coronal planes. For T1-weighted imaging, parameters were 350–500/15–30/4 (repetition time/echo time/excitations), and for proton density- and T2-weighted imaging, 2500–3000/30 and 80–100/2 were used. Every pulse sequence had a section thickness of 5 mm with an intersection gap of 2 mm. Gadolinium-enhanced T1-weighted images were also obtained after intravenous injection (0.1 mmol/kg) of gadopentetate dimeglumine in two cases of postoperative mucocoele.


The cases were divided into two groups, antral and extraantral lesions. *Antral* lesions, defined as lesions originating within the maxillary antrum, included 20 cases of

mucocoeles with various causes. In 8 cases, various entities that arose at the bony maxilla outside the antrum were categorized as *extraantral* lesions. This group included fissural cysts, odontogenic cysts, and a cystic ameloblastoma. The CT or MR findings were analyzed with special attention to (a) the presence of a bony septum between the cystic lesion and the remaining maxillary antrum and (b) the mode of extension of the lesions.

Results

In every case in this series, the bony walls of the maxillary sinus were displaced or eroded at least on one side. In all eight cases of extraantral lesions (fissural cysts, odontogenic cysts, and cystic ameloblastoma), thin bony plates representing the floor of the maxillary sinus between the cystic expansile mass and the adjacent maxillary antrum were demonstrated at least partially (Figs 1, 2, and 3). In one case of odontogenic cyst, this displaced bony plate was not demonstrated on MR, whereas CT with bone algorithm clearly showed the antral superior bony wall and upwardly displaced bony plate (Fig 3). By identifying these bony plates, the extraantral lesions were easily distinguished from the antral lesions except in two cases of mucocoeles at the septated compartments of the maxillary sinus. In these two cases the mucocoeles arose in a smaller compartment in a superior portion of the sinus (Fig 4), and there were thin bony walls of the lesions bulging into the normally aerated maxillary antrum.

Fig 1. Fifty-two-year-old man with a fissural cyst in the maxilla. Axial (A) and coronal (B) CT images show a large cystic expansile mass in the inferomedial portion of the left maxilla. Thin bony walls (arrows) between the cystic lesion and the normally aerated antral cavity are seen. This finding suggests extraantral origin of this lesion. This cyst was excised and diagnosed as a globulomaxillary cyst by histopathologic examination and the typical paramedian location.






Fig 2. Twelve-year-old girl with cystic maxillary ameloblastoma. Postcontrast axial (A) and coronal (B) CT images show a large cystic expansile mass in the left maxilla. There is a bony wall (*arrows*) between the cystic lesion and the small fluid-filled sinus cavity suggesting extraantral origin of the lesion. Axial CT (C) at the level of the lower maxilla shows a small soft tissue mural nodule in the anteromedial portion of the cyst (*arrowhead*); this may be a clue in distinguishing a unicystic ameloblastoma from a dentigerous cyst. Note an unerupted tooth within the cystic lesion.




Fig 3. Twenty-year-old woman with an odontogenic cyst in the right maxilla. Coronal (A) CT image with bone algorithm shows a large cystic expansile mass in the right maxilla with a thin, displaced bony wall (*arrowheads*). The wall of the cyst is seen as a thin, enhancing rim on the postcontrast T1-weighted MR image in the coronal plane (B) and as a slightly hypointense rim on the T2-weighted axial image (C).


All three cases of maxillary fissural cysts showed inferior location with medial and anterior bulging of the lesion (Fig 1). The fissural cysts did not protrude through the posterolateral wall of the maxilla. Four cases of odontogenic lesions showed protrusion (or bulging) through the posterior as well as the anterior and lateral wall (Fig 2).

All 20 postoperative mucocoeles in 17 patients showed hyperostotic and retracted bony walls caused by postoperative bone changes (Fig 5). Localized erosion of bony walls with eccentrically expansile cystic masses were demonstrated in every case. In 11 of these cases, the cystic masses extended through the anterior surgical bone defects, the most common route of extension (Fig 6). Medial extension into the nasal cavity was seen in 9 lesions, posterolateral extension to the infratemporal

fossa in 8, and intraorbital extension in 6. Two cases had epiphora caused by obstruction of the nasolacrimal duct. Compartmentalization of the lesions by bony or fibrous septa were demonstrated in 8 lesions. In 7 cases the lesions were divided into two compartments and 1 lesion was divided into three compartments. MR of 3 cases with multicompartmentalized lesions showed the contents of the lesions as different signal intensities in each compartment. In 1 case, the contents of the compartments showed very high signal intensities on both T1- and T2-weighted images.

Of 14 cases with unilateral lesions, 12 cases with histories of bilateral Caldwell-Luc operations showed postoperative changes of the maxillary sinus in the opposite side. In 6 cases, complete obliteration of the maxillary antrum was demonstrated (Fig 5); inflammatory

Fig 4. Forty-five-year-old man with a mucocele in septated maxillary sinus. Axial (A) and coronal (B) CT images show a round cystic mass in the upper and anterior portions of the left maxillary sinus with intraorbital extension. There is a bony septum (*arrowheads*) between the cystic lesion and the normally aerated antral cavity. The lesion was excised surgically and was diagnosed as a mucocele. Note an incomplete bony septum in the anterior wall of the right maxillary sinus (*arrow*).



changes including mucosal thickening and effusion were seen in 1 case.

A case of maxillary antral mucocele with ostial obstruction showed diffuse antral expansion with homogeneously low-density material within it. No specific disease was found in the ostial area except nonspecific inflammatory change of the nasal mucosa in this case.

Discussion

A mucocele is an expansion of the sinus cavity caused by an obstruction of the sinus ostium and an accumulation of secretion. This is the most common cystic lesion involving the paranasal sinuses and the most significant local complication of sinusitis as a result of obstruction of the sinus ostium. As an antral lesion, a mucocele is the only cystic lesion that may cause expansion or erosion of the maxilla. Mucocele formation by inflammatory ostial ob-

struction in the maxillary sinus is uncommon; the maxillary sinus is the most common location for an inflammatory or allergic process (5-7).

Mucoceles on rare occasions can occur within septated compartments in the maxillary sinus (8, 9). In these cases, only a portion of the sinus is expanded and there may still be residual areas of erosion. Mucoceles also occur in the maxillary sinus after Caldwell-Luc procedures (10). There are scattered reports of postoperative maxillary mucoceles in the West (7, 8); they seem to be more common in Asia (10, 11), although the reason for this is not clear. They are thought to be a late complication after Caldwell-Luc procedure (11) and are caused by a secretion from residual epithelium in postoperative maxillary sinuses.

Postoperative maxillary mucoceles showed peculiar CT findings of localized bone defect and localized bulging (Figs 5 and 6). Such areas of bony expansion can occur in eccentric locations; diffuse or symmetric bulging is the usual finding of mucocele formation by ostial obstruction. The most frequent site of bone defect and soft tissue bulging was the anterior wall in which the bone windows were made during Caldwell-Luc procedures. Compartmentalization of the maxillary antrum, thought to be one of the postoperative changes, may cause eccentric or localized expansion of the lesions. Each compartment may show different signal intensities on MR, probably because of different protein concentration of fluid collection (12). This finding represents the absence of communication between each compartment. Compartmentalization by bony or fibrous septa may have some therapeutic implications (8). The posterior or hidden compartment is not directly seen by a Caldwell-Luc procedure; a preoperative knowl-




Fig 5. Fifty-seven-year-old woman with a history of bilateral Caldwell-Luc operation 37 years ago. Postcontrast axial CT at the midmaxillary level shows a cystic expansile mass in the right maxillary sinus with erosion of the posterolateral wall. The mucocele had broken into the nasal cavity and an air-fluid level is seen within the lesion. The opposite side shows usual postoperative changes including an obliterated maxillary antrum with hyperostotic bony walls and dilated inferior meatus.




Fig 6. Thirty-seven-year-old man with bilateral postoperative maxillary mucocoeles. Postcontrast axial CT at the level of the inferior turbinate (A) shows a cystic mass in the right maxillary sinus protruding anteriorly through the surgical bone defect (arrow). A cystic lesion with mild medial expansion is seen in the opposite maxillary sinus. At midmaxillary level (B), the left maxillary sinus is compartmentalized by the thin bony septa and the posterior chamber is aerated normally.

edge of its existence is important for adequate surgical drainage.

Septation of the maxillary antrum may be developmental (13). Incomplete division of the maxillary antrum by bony septa may be observed occasionally, and on rare occasions the maxillary antrum can be completely compartmentalized by a bony septum (8). In our series, in the cases of mucocoeles arising in the small septated compartment of the maxillary sinus, the involved compartments were located in the upper portion of the antrum at the floor of the orbit (Fig 4). These may be separated ethmoidal air cells (Haller cells) that project inferiorly to the ethmoidal bulla into the floor of the orbit in the region of the maxillary sinus ostium (14, 15). Whether these are septated compartments of the maxillary sinuses or separated ethmoidal air cells (Haller cells), mucocoeles involving such a space will show a thin bony septum between the lesion and the normal maxillary antrum, which may mimic an extraantral origin of the lesion. In our series, however, all the extraantral lesions arose in the inferior part of the maxilla, and the mode of extension of a septated sinus mucocoele was quite different from that of an extraantral lesion.

Extraantral lesions include a number of benign odontogenic cystic lesions and fissural cysts. Odontogenic cystic lesions include developmental odontogenic cysts such as primordial and dentigerous cysts, odontogenic keratocysts, residual cysts, cystic ameloblastomas, and inflammatory lesions such as radicular or periapical cysts (3, 4, 16, 17). Histologic analysis of the epithelial layers, association with other clinical findings, relationship to a tooth, and internal calcification allow further subdivision (4). All nontumorous odontogenic cysts show similar radiologic findings of clearly demarcated expansile cystic mass, usually occur in the mandible, and are related to the root or

crown of a tooth (3, 17). In a dentigerous cyst, the cystic cavity is almost always unilocular, and one can note an unerupted tooth within the cystic lesion (Fig 2). Occasionally odontogenic cysts develop in the maxilla and extend into the antral cavity.

All three fissural cysts in our series were globulomaxillary and showed typical lateral maxillary location. Of the lateral fissural cysts, only globulomaxillary cysts involve the maxillary sinus (1). It is currently believed that the globulomaxillary cyst is a true fissural cyst or possibly of odontogenic origin (16, 17). The cases with globulomaxillary cysts showed typical inferior and paramedian location with medial and anterior bulging of the lesion (Fig 1).

Ameloblastoma occurs in the mandible much more frequently than in the maxilla. The tumor may be cystic, solid, or mixed. A unicystic lesion has a less aggressive tendency (18–21). A unicystic ameloblastoma may show an unerupted tooth within the cyst and radiologic findings similar to that of a dentigerous cyst. Occasionally an ameloblastoma may occur from the epithelial lining of a dentigerous cyst; this has been termed *mural ameloblastoma* (21, 22). The case in our series showed CT findings of a unilocular cystic mass containing an unerupted tooth and a small mural nodule (Fig 2). This intracystic mural nodule may be an important differential point from a dentigerous cyst.

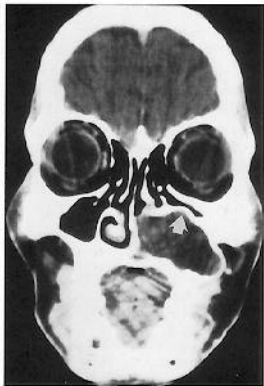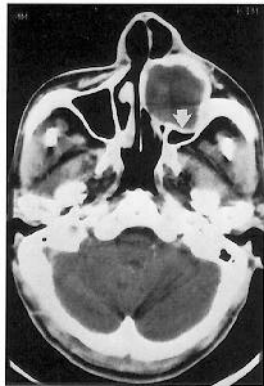Because these fissural cysts and odontogenic lesions arise within the maxillary alveolar process, it is not surprising that every case with extraantral lesions shows bony plates between the cystic lesion and the maxillary antrum (Figs 1–3). These bony plates represent the displaced and remodeled floor of the maxillary sinus. The alveolar process has cancellous bone between two layers of cortical bone. Many odontogenic lesions arise within the alveolar process and so expand the floor of the maxillary sinus upward.

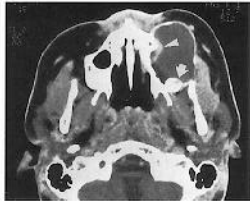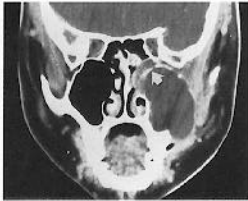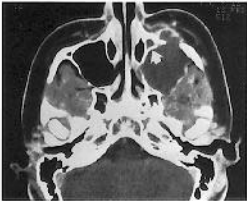
By identifying the bony plate between the cystic mass and the maxillary antrum, one can easily distinguish an extraantral cystic lesion from an antral lesion such as a mucocele. Because an observation of the displaced cortical plate is important, CT would be the most useful imaging mode for these evaluations.

To summarize, in the differential diagnosis of a cystic mass of the maxilla, careful identification of the bony walls and bony septa may allow one to define the location of a mass as antral or extraantral in origin. However, a mucocele arising in a septated compartment of the maxillary sinus may mimic an extraantral lesion by showing a thin bony wall between the lesion and the adjacent antral cavity.

References

- Som PM. Sinonasal cavity. In: Som PM, Bergeron RT, eds. *Head and Neck Imaging*. 2nd ed. St Louis: Mosby, 1991:51-276
- Tassel PV, Lee YY, Jing BS, De Pena CA. Mucoceles of the paranasal sinuses: MR imaging with CT correlation. *AJNR Am J Neuroradiol* 1989;10:607-612
- Goaz PW, White SC. Cysts of the jaws. In: Goaz PW, White SC, eds. *Oral Radiology*. 2nd ed. St Louis: Mosby, 1987:484-513
- Weber AL. Imaging of cysts and odontogenic tumors of the jaw. *Radiol Clin North Am* 1993;31:101-120
- Hesselink JR, Weber AL, New PF, Davis KR, Roberson GH, Taveras JM. Evaluation of mucoceles of the paranasal sinuses with computed tomography. *Radiology* 1979;133:397-400
- Weber AL. Inflammatory diseases of the paranasal sinuses and mucoceles. *Otolaryngol Clin North Am* 1988;21:421-437
- Ormerod LD, Weber AL, Rauch SD, Feldon SE. Ophthalmic manifestations of maxillary sinus mucoceles. *Ophthalmology* 1987;94:1013-1019
- Som PM, Sacher M, Lanzieri CF, Lawson W, Shuger JMA. The hidden antral compartment. *Radiology* 1984;152:463-464
- Som PM, Shugar JMA. Antral mucoceles: a new look. *J Comput Assist Tomogr* 1980;4:484-488
- Hasegawa M, Saito Y, Watanabe I, Kern EB. Postoperative mucoceles of the maxillary sinus. *Rhinology* 1979;17:253-256
- Isoda H, Takehara Y, Masui T, Seki A, Takahashi M, Kaneko M. MRI of postoperative maxillary cysts. *J Comput Assist Tomogr* 1993;17:572-575
- Som PM, Dillon WP, Fullerton GD, Zimmerman RA, Rajagopalan B, Marom Z. Chronically obstructed sinonasal secretions: observations on T1 and T2 shortening. *Radiology* 1989;172:515-520
- Alberti PW. Applied surgical anatomy of the maxillary sinus. *Otolaryngol Clin North Am* 1976;9:3-20
- Laine FJ, Smoker WRK. The ostiomeatal unit and endoscopic surgery: anatomy, variations, and imaging findings in inflammatory diseases. *AJR Am J Roentgenol* 1992;159:849-857
- Kennedy DW, Zinreich SJ. Functional endoscopic approach to inflammatory sinus disease: current perspectives and technique modifications. *Am J Rhinol* 1988;2:89-96
- Christ TF. The globulomaxillary cyst: an embryologic misconception. *Oral Surg* 1970;30:515-526
- Hall RE, Delbalso AM, Carter LC. Radiography of the sinonasal tract. In: Delbalso AM, ed. *Maxillofacial Imaging*. Philadelphia: Saunders, 1990:139-207
- Minami M, Kaneda T, Yamamoto H, et al. Ameloblastoma in the maxillomandibular region: MR imaging. *Radiology* 1992;184:389-393
- Heltzanu Y, Mendelsohn DB, Cohen MA. Computed tomography of mandibular ameloblastoma. *J Comput Assist Tomogr* 1984;8:220-223
- Weber AL. The mandible. In: Som PM, Bergeron RT, eds. *Head and Neck Imaging*. 2nd ed. St Louis: Mosby, 1991:379-405
- Robinson L, Martinez MG. Unicystic ameloblastoma: a prognostically distinct entity. *Cancer* 1977;40:2278-2285
- Matteson SR. Benign tumors of the jaws. In: Goaz PW, White SC, eds. *Oral Radiology*. 2nd ed. St Louis: Mosby, 1987:514-565

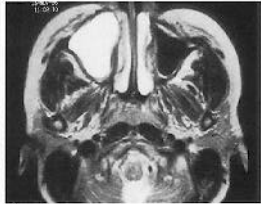
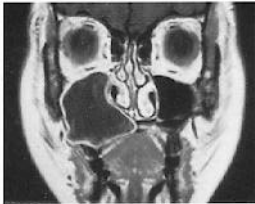
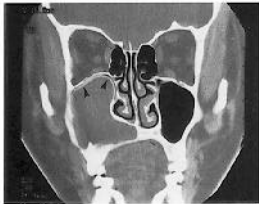

A

B

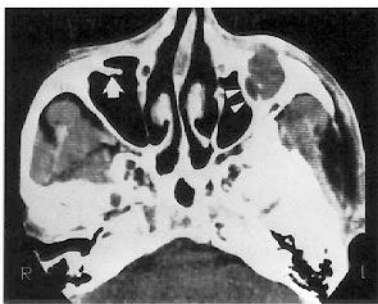
C



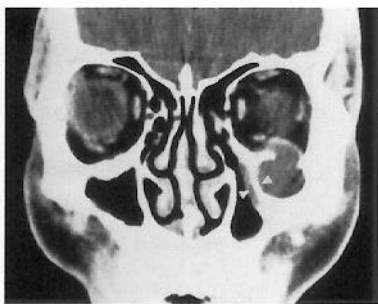
A

B

C

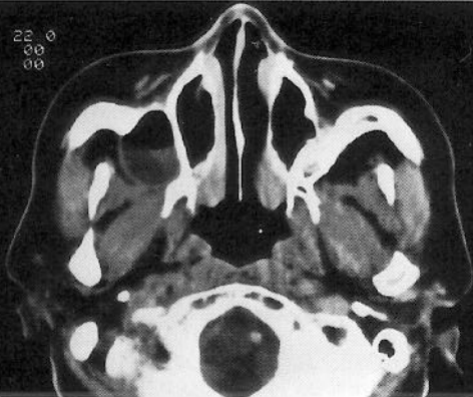


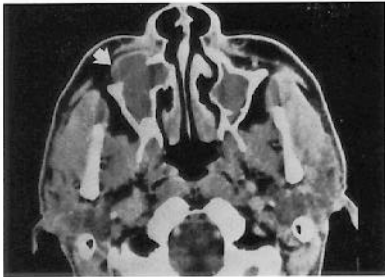
A



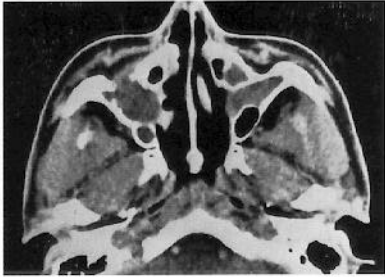
B

22 0
00
00





A



B