




# Intraosseous Dermoid Presenting as an Expansile Lytic Lesion

Grace E. O'Shea<sup>1</sup> Victoria L. Watson<sup>1</sup>  Leslie Acakpo-Satchivi<sup>2</sup>

<sup>1</sup>Southern Illinois University, Department of Neurosurgery, Springfield, Illinois, United States

<sup>2</sup>Springfield Clinic, Department of Neurological Surgery, Springfield, Illinois, United States

**Address for correspondence** Grace E. O'Shea, BA, 801 N Rutledge St., Springfield, IL 62702, United States (e-mail: Graceoshea98@gmail.com).

J Neurol Surg Rep 2022;83:e77–e79.

## Abstract

### Keywords

- ▶ dermoid cysts
- ▶ child
- ▶ frontal bone
- ▶ neuronavigation

Cranial dermoids have the tendency to occur in the midline, especially near fontanelles and sutures early in the life of a patient. Here we present an unusual case of an intraosseous dermoid that presented initially as a lytic lesion, off of the midline and not associated with cranial sutures or fontanelles. The diameter of the lesion grew to approx 15 mm over time, thus the decision was made to take the child to surgery for removal of dermoid with the use of neuronavigation and cranioplasty. A dermoid cyst was confirmed on histopathologic analysis.

## Introduction

Dermoid cysts are uncommon soft tissue lesions composed of squamous, epithelium-lined sacs.<sup>1</sup> The cyst develops during gestation and is generally characterized by a midline location. The wall of the cyst contains sweat glands and sebaceous glands that secrete fluid into the cyst cavity. This causes a hyperintense signal in T1-weighted imaging.<sup>2,3</sup> Clinically, it presents as a raised lump or mass. We report an atypical case of a patient with an intraosseous dermoid cyst, presenting as a lesion noticed as a raised lump and located off the midline.

## Case Report

A 2-month-old female presented with a fluid collection within the deep scalp appearing to overlie a calvarial defect with possible intracranial extension visualized on ultrasound. At approximately 7 months of age, the patient underwent a head computed tomography (CT), which revealed a chronic appearing, small calvarial defect in the inferior right

frontal region immediately anterior to the coronal suture (▶ **Figs. 1** and **2**). It measured approximately 6 mm in greatest dimensions. There were beveled sclerotic margins, and an associated defect appeared to extend through the inner table of the right frontal bone. At 18 months, a repeat head CT revealed the lesion had expanded, demonstrating increased bony remodeling (▶ **Figs. 3** and **4**). The diameter of the lesion grew to approximately 14 to 15 mm. It was decided to excise the lesion due to progression in size. The patient underwent resection of the lesion by supratentorial craniectomy with use of neuronavigation, followed by cranioplasty. The mass was removed in a piecemeal fashion until the entire visible portion was removed. The presence of cottage cheese-like material emanated from the diploic spaces of bone, a finding generally consistent with a dermoid cyst, which was confirmed on histopathologic examination. The craniotomy defect measured approximately 12 × 17.5 × 20 mm after the mass was removed. Cranioplasty was then performed by applying autologous bone chips to the surface of the dura and overlaying them with a moldable demineralized bone putty.

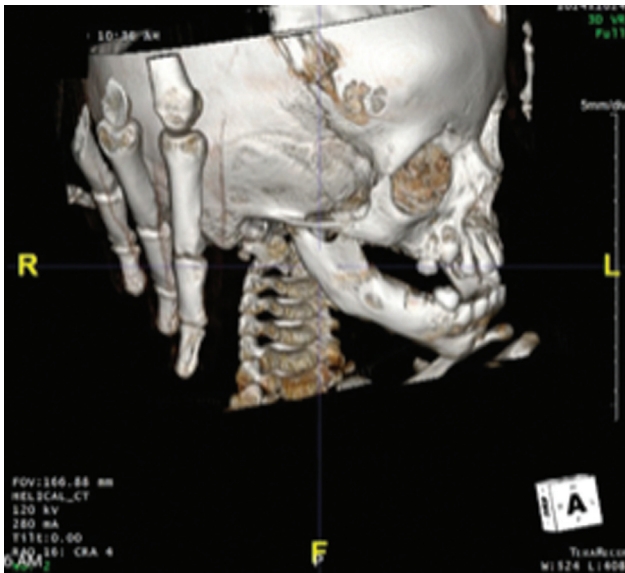
received  
September 23, 2020  
accepted  
March 30, 2022

DOI <https://doi.org/10.1055/s-0042-1750291>.  
ISSN 2193-6358.

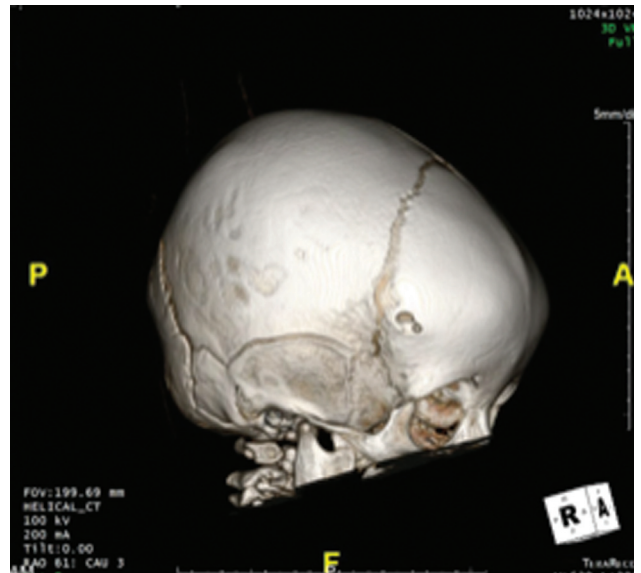
© 2022. The Author(s).

This is an open access article published by Thieme under the terms of the Creative Commons Attribution-NonDerivative-NonCommercial-License, permitting copying and reproduction so long as the original work is given appropriate credit. Contents may not be used for commercial purposes, or adapted, remixed, transformed or built upon. (<https://creativecommons.org/licenses/by-nc-nd/4.0/>)

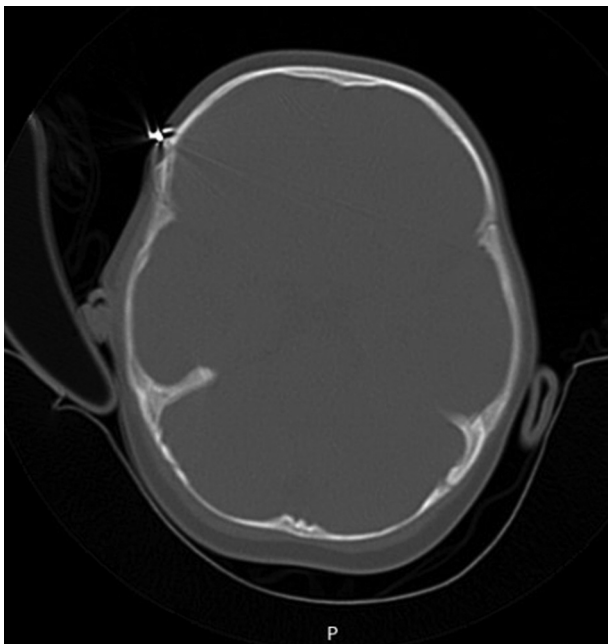
Georg Thieme Verlag KG, Rüdigerstraße 14, 70469 Stuttgart, Germany



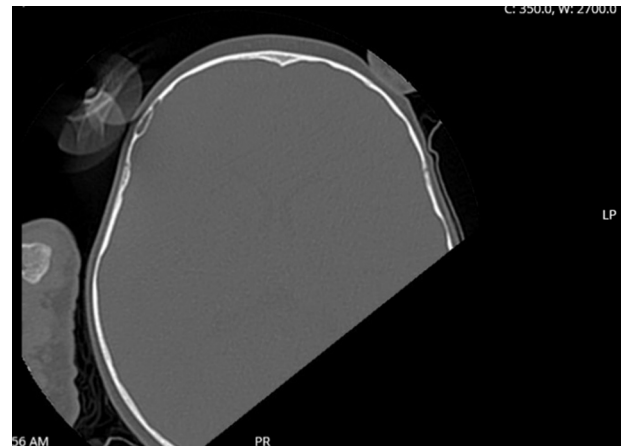
**Fig. 1** Initial head CT with bony reconstruction demonstrating lytic lesion. CT, computed tomography.



**Fig. 3** Follow-up CT demonstrating expansion of bony lesion on bony reconstruction. CT, computed tomography.



**Fig. 2** Initial head CT bony window with overlying radio-opaque marker demonstrating expansile lesion. CT, computed tomography.



**Fig. 4** Follow-up CT demonstrating expansion of diploic space with relative preservation of inner and outer cortices. CT, computed tomography.

## Discussion

Dermoid cysts are uncommon, slow-growing congenital lesions. Their differential diagnosis includes dermoid cyst, cavernous hemangioma, eosinophilic granuloma, Langerhans cell histiocytosis, and fibrous dysplasia.<sup>4</sup> Pediatric patients are the main population affected by dermoid cysts, as most develop during gestation and become symptomatic early in life. This occurs in response to entrapment of the ectoderm surface along the lines of embryonic fusion. The lesion commonly appears superficially along the cranial sutures or anterior fontanelle.<sup>1,5</sup> They are benign but produce keratin and sebaceous material that is deposited into

the cyst cavity.<sup>2,5</sup> This results in the formation of an oily mixture inside the cyst. As secretion continues, increasing intracystic pressure can result in mass effect or rupture.<sup>2</sup> Consequently, this heightens the risk of cranial erosion and expansion in the epidural space.<sup>5</sup>

Dermoid cysts can occur in many locations of the body, but cysts of the head and neck are commonly located at the frontotemporal or brow region.<sup>3</sup> They often present as a benign, painless lump under the scalp. Occasionally, they are noticed as a palpable bony defect, as in this case.<sup>6</sup> Pryor et al performed a retrospective review of pediatric patients presenting with dermoid cysts of the head and neck and found that 61% of the cysts were located in the periorbital region. Due to its close proximity to the orbital region, cysts found in this area can cause symptoms of headache, proptosis, visual disturbances, and development of extradural hematomas. Only 10% of patients presented with cysts located in the

skull.<sup>7</sup> This cyst presented in the right frontotemporal region of the patient's calvarium and was unusual because it was not in the midline. Additionally, it was intradiploic, a rare subtype of frontotemporal dermoid cysts accounting for only 0.4 to 0.7% of all cranial masses.<sup>8</sup> An indication that the cyst arose from the diploe is if the local dura remains unaffected in addition to eroding inner and outer tables of the skull.<sup>9,10</sup>

#### Discloser

No personal or institutional financial interest in drugs, materials, or devices described in this submission. Per the institutional review board, no approval was required, nor was patient consent required due to the case report nature of the submission.

This work has not been previously presented or published.

#### Funding

None.

#### Conflict of Interest

None declared.

#### References

- Howard BE, Masood MM, Clark JM, Thorp BD. Intraorbital dermoid cyst with zygomaticofrontal suture erosion in an adult. *J Craniofac Surg* 2019;30(02):514–515
- Balasundaram P, Garg A, Prabhakar A, Joseph Devarajan LS, Gaikwad SB, Khanna G. Evolution of epidermoid cyst into dermoid cyst: embryological explanation and radiological-pathological correlation. *Neuroradiol J* 2019;32(02):92–97
- Rinna C, Reale G, Calafati V, Calvani F, Ungari C. Dermoid cyst: unusual localization. *J Craniofac Surg* 2012;23(05):e392–e394
- Moreira-Holguin JC, Medélez-Borbonio R, Quintero-Lopez E, García-González U, Gómez-Amador JL. Intradiploic epidermoid cyst with intracranial hypertension syndrome: report of two cases and literature review. *Int J Surg Case Rep* 2015; 16:81–86
- Prior A, Anania P, Pacetti M, et al. Dermoid and epidermoid cysts of scalp: case series of 234 consecutive patients. *World Neurosurg* 2018;120:119–124
- Bikmaz K, Cosar M, Bek S, Gokduman CA, Arslan M, Iplikcioglu AC. Intradiploic epidermoid cysts of the skull: a report of four cases. *Clin Neurol Neurosurg* 2005;107(03):262–267
- Pryor SG, Lewis JE, Weaver AL, Orvidas LJ. Pediatric dermoid cysts of the head and neck. *Otolaryngol Head Neck Surg* 2005;132(06): 938–942
- Vega RA, Hidlay DT, Tye GW, Fuller CE, Rhodes JL. Intradiploic dermoid cyst of the lateral frontotemporal skull: case report and review of the literature. *Pediatr Neurosurg* 2013;49(04): 232–235
- Gaivas S, Rotariu D, Dumitrescu G, Iliescu B. Intradiploic epidermoid cyst of the skull: case report. *Romanian Neurosurg* 2011;18 (02):889–894
- Wani AA, Raswan US, Malik NK, Ramzan AU. Posterior fossa ruptured dermoid cyst presenting with hydrocephalus. *Neurosciences (Riyadh)* 2016;21(04):358–360