

## Mandibular Lesions: A Practical Approach for Diagnosis Based on Multimodality Imaging Findings

Rami Eldaya, MD, MBA, Omar Eissa, MD, Stephen Herrmann, MD, Jax Pham, DO, Susana Calle, MD, and Tomas Uribe, MD

*After participating in this educational activity, the diagnostic radiologist should be better able to diagnose many different benign and malignant lesions involving the mandible.*

**Category: General Radiology**  
**Subcategory: Musculoskeletal**  
**Modality: CT**

**Key Words:** Mandible, Mandibular Cystic Lesions, Mandibular Odontogenic Solid Tumors, Tooth-Related Sclerotic Mandibular Lesions, Nonodontogenic Mandibular Tumors

*The mandible is a physiologically complex bone that plays a role in phonation, mastication, and jaw stability. It is a strong flat bone that serves as an anchor for the lower dentition and an attachment site for masticator muscles and facial muscles. The mandible is composed of multiple bony segments including a U-shaped body segment that fuses in the anterior midline at the symphysis menti and extends posteriorly to the vertical ramus segments. Each ramus connects to the body through the angle. The ramus extends cranially to form the coronoid process and mandibular condyle, which are separated by the mandibular notch. The mandibular condyle articulates with the temporal bone at the glenoid fossa*

Dr. Eldaya, Dr. Eissa, Dr. Herrmann, and Dr. Pham are Residents, Department of Radiology, University of Texas Medical Branch, Galveston, Texas; Dr. Calle is a Fellow, Department of Diagnostic and Interventional Imaging, University of Texas MD Anderson Cancer Center, Houston, Texas; and Dr. Uribe is Assistant Professor of Neuroradiology, Department of Radiology, Baylor College of Medicine, One Baylor Plaza, MS360, Houston, TX 77030; E-mail: tacosta@bcm.edu.

The authors and all staff in a position to control the content of this CME activity and their spouses/life partners (if any) have disclosed that they have no relationships with, or financial interests in, any commercial organizations pertaining to this educational activity.

*forming the temporomandibular joint. The outer cortical bone of the mandible is known as the buccal surface, and the inner cortex is known as the lingual surface. Between the two cortices, there is trabecular bone and the alveolar canal, which carries the mandibular nerves.*

*The mandible is a common site for more than 30 different lesions.<sup>1</sup> Multiple lesion classifications have been proposed, including classifications based on origin (odontogenic vs. nonodontogenic); location; appearance (cystic vs. solid); or pathology. Understanding all of the mentioned classifications is by far the best approach to appreciate the complex overlapping pathologies.*

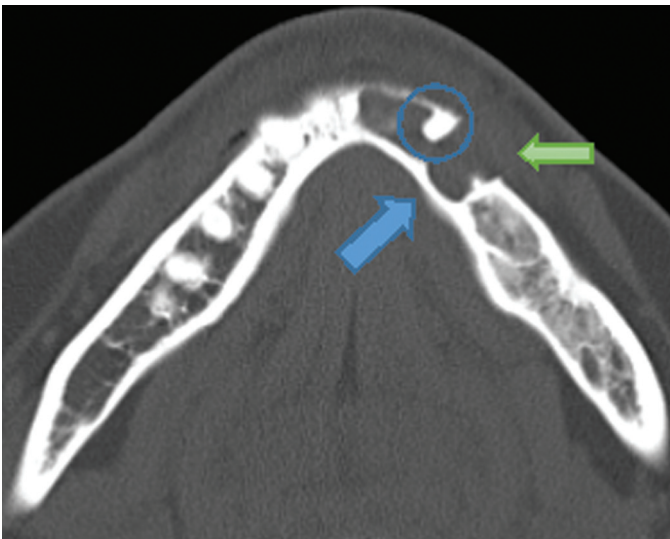
Given the diversity and extensive pathologies affecting the mandible, it is difficult to assess every lesion in great details within a single review. This article serves as a selective review, emphasizing the most common lesions, lesions with a classical “Aunt Minnie” imaging appearance, and important “cannot miss lesions.”

### Mandibular Cystic Lesions

#### Keratocystic Odontogenic Tumor

Keratocystic odontogenic tumors are common lesions, constituting 5% to 15% of all jaw cysts.<sup>2</sup> They mostly present in young adults in the second to fourth decades of life and are thought to arise from the dental lamina (band of ectodermal cells giving rise to the teeth and enamel). Keratocystic odontogenic tumors can expand and thin the cortex. They typically have associated daughter cysts, which explain their high recurrence rate (50%) when treated with curettage. On imaging, these lesions are unilocular, lucent, expansile, and

Lippincott Continuing Medical Education Institute, Inc., is accredited by the Accreditation Council for Continuing Medical Education to provide continuing medical education for physicians. Lippincott Continuing Medical Education Institute, Inc., designates this enduring material for a maximum of 2 AMA PRA Category 1 Credits™. Physicians should only claim credit commensurate with the extent of their participation in the activity. To earn CME credit, you must read the CME article and complete the quiz and evaluation on the enclosed answer form, answering at least seven of the 10 quiz questions correctly. This continuing medical education activity expires on March 14, 2018.



**Figure 1.** Keratocystic odontogenic tumor. Axial, nonenhanced CT scan demonstrates a unilocular, expansile, lucent lesion (*blue arrow*) within the body of the mandible resulting in thinning and erosion of the overlying cortex (*green arrow*) associated with an unerupted tooth (*circle*). Location, expansile appearance, and unerupted tooth combination strongly suggest the diagnosis of keratocystic odontogenic tumor.

often with thin overlying cortex, potentially eroding it (Figure 1). Keratocystic odontogenic tumors can be associated with unerupted teeth and most commonly occur in the body and ramus of the mandible.<sup>1</sup> The treatment is usually surgical removal with wide margins to remove potential daughter cells. The presence of multiple keratocystic odontogenic tumors should raise concern for Gorlin-Goltz syndrome (i.e., basal cell nevi, multiple keratocystic odontogenic tumors, and skeletal malformations).

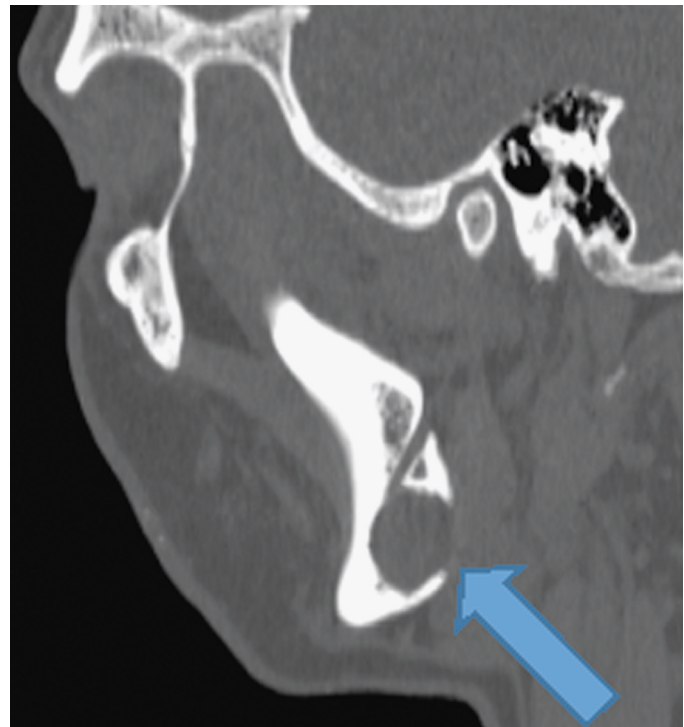---

**Keratocystic odontogenic tumors typically have associated daughter cysts, which also must be removed when treated with curettage to prevent recurrence.**

---

### Traumatic (Simple) Bone Cyst

The mandible is the most common location for traumatic bone cysts.<sup>1</sup> Although these are labeled as cysts, they are not



**Figure 2.** Traumatic (*simple*) bone cyst. Sagittal, nonenhanced CT scan demonstrates a unilocular, lucent, nonexpansile lesion that is corticated but with scalloping of the inferomedial margin (*arrow*) incidentally noted in a 24-year-old man. The imaging appearance and clinical picture suggest the diagnosis of a traumatic bone cyst.

true cysts as they do not contain a true epithelial lining. The pathophysiology of these lesions is not clearly understood but is thought to be secondary to traumatic hemorrhage with subsequent bone resorption.<sup>3</sup> Traumatic bone cysts typically occur in the second decade of life and usually are detected incidentally. They typically appear on imaging as unilocular, lucent lesions with scalloped, thinned cortical margins extending between the teeth roots (Figure 2).

### Dentigerous (Follicular) Cyst

Dentigerous cysts are the most common developmental/noninflammatory odontogenic cysts.<sup>2</sup> Dentigerous cysts occur mostly in young adults, with peak incidence between the second and fourth decades of life. Dentigerous cysts occur secondary to proliferation of the lining of the dental follicle.

The continuing education activity in *Contemporary Diagnostic Radiology* is intended for radiologists.

**Contemporary Diagnostic Radiology** (ISSN 0149-9009) is published bi-weekly by Lippincott Williams & Wilkins, Inc., 14700 Citicorp Drive, Bldg 3, Hagerstown, MD 21742. **Customer Service: Phone (800) 638-3030; Fax (301) 223-2400; E-mail: customerservice@lww.com.** Visit our website at LWW.com. Publisher, Randi Davis.

Copyright © 2017 Wolters Kluwer Health, Inc. All rights reserved. Priority Postage paid at Hagerstown, MD, and at additional mailing offices. POSTMASTER: Send address changes to *Contemporary Diagnostic Radiology*, Subscription Dept., Lippincott Williams & Wilkins, P.O. Box 1600, Hagerstown, MD 21740.

PAID SUBSCRIBERS: Current issue and archives (from 1999) are available FREE online at [www.cdrnewsletter.com](http://www.cdrnewsletter.com).

Subscription rates: *Individual:* US \$723; international \$1059. *Institutional:* US \$1197; international \$1359. *In-training:* US resident \$146 with no CME, international \$170. GST Registration Number: 895524239. Send bulk pricing requests to Publisher. *Single copies:* \$52. **COPYING:** Contents of *Contemporary Diagnostic Radiology* are protected by copyright. Reproduction, photocopying, and storage or transmission by magnetic or electronic means are strictly prohibited. Violation of copyright will result in legal action, including civil and/or criminal penalties. Permission to reproduce in any way must be secured in writing: go to the journal website ([www.cdrnewsletter.com](http://www.cdrnewsletter.com)), select the article, and click "Request Permissions" under "Article Tools," or e-mail [customer-care@copyright.com](mailto:customer-care@copyright.com). **Reprints:** For commercial reprints and all quantities of 500 or more, e-mail [reprint-solutions@wolterskluwer.com](mailto:reprint-solutions@wolterskluwer.com). For quantities of 500 or under, e-mail [reprints@lww.com](mailto:reprints@lww.com), call 866-903-6951, or fax 410-528-4434.

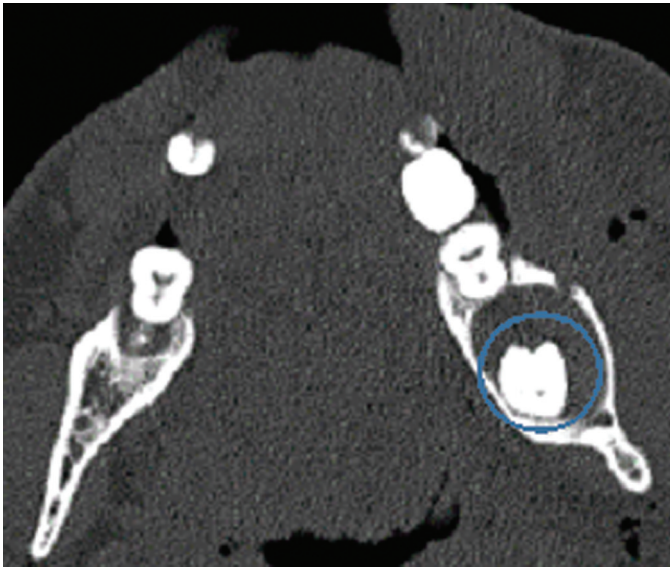
**EDITOR: Robert E. Campbell, MD,** Clinical Professor of Radiology, University of Pennsylvania School of Medicine, Philadelphia, Pennsylvania

#### EDITORIAL BOARD:

**Teresita L. Angtuaco, MD**  
**William G. Bradley Jr., MD, PhD**  
**Liem T. Bui-Mansfield, MD**  
**Valerie P. Jackson, MD**

**Mary C. Mahoney, MD**  
**Johnny U. V. Monu, MBBS, Msc**  
**Pablo R. Ros, MD, MPH, PhD**  
**William M. Thompson, MD**

Opinions expressed do not necessarily reflect the views of the Publisher, Editor, or Editorial Board. A mention of products or services does not constitute endorsement. All comments are for general guidance only; professional counsel should be sought for specific situations. Indexed by Bio-Science Information Services.



**Figure 3.** Dentigerous cyst. Axial, nonenhanced CT scan demonstrates a corticated, lucent mandibular lesion containing the left third molar tooth (*circle*). Imaging appearance and location are virtually pathognomonic of a dentigerous cyst. The subcutaneous air and soft tissue swelling about the mandible were caused by recent trauma. The dentigerous cyst was an incidental finding.

This results in fluid accumulating between the follicular epithelium and the crown of the developing or unerupted tooth. Dentigerous cysts mostly occur around the third mandibular molar. The presence of a tooth crown projecting into a mandibular cyst is pathognomonic for dentigerous cysts. Imaging closely follows the pathophysiology and typically demonstrates a corticated cyst containing a crown of an unerupted tooth (Figure 3). Treatment typically is extraction of the involved tooth with cyst removal.

---

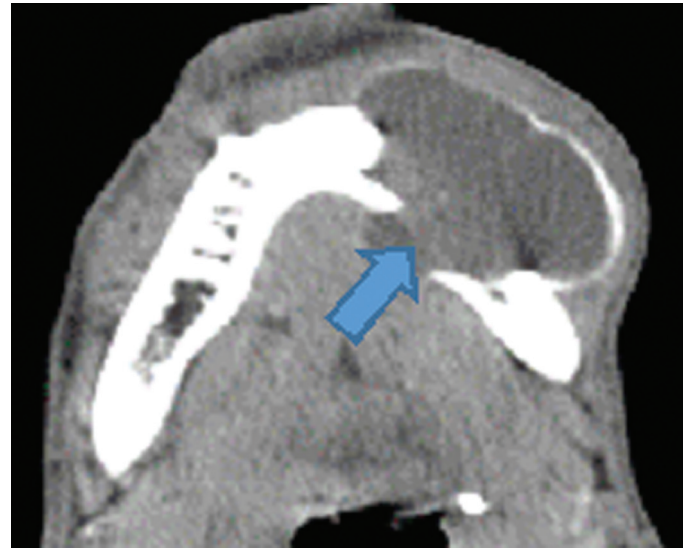
**Dentigerous cysts are the most common developmental/noninflammatory odontogenic cysts.**

---

### Primary Mandibular Odontogenic Solid Tumors

#### Ameloblastoma

Ameloblastoma arises from the enamel-forming cells of the epithelium secondary to faulty progression.<sup>4</sup> They typically present in the third to sixth decades of life and constitute 10% of all odontogenic tumors. Ameloblastomas typically are associated with unerupted teeth and usually are slow growing.<sup>1</sup> Ameloblastomas have variable imaging appearance compared with simple unilocular cysts, which can be indistinguishable from dentigerous cysts or keratocystic odontogenic tumors, to the more classical multiloculated, well-defined lesion with a “soap bubble” appearance. Erosion of the roots of adjacent teeth is very suggestive of ameloblastoma (Figure 4), but erosion is not always present, and if present, indicates aggressive behavior. Multiple subtypes of ameloblastoma have been described, with variable aggressiveness that is best evaluated by histopathologic analysis. Treatment is typically surgical resection with extent of resection dependent on histopathologic findings.



**Figure 4.** Ameloblastoma. Axial, contrast enhanced CT scan demonstrates a well-defined, expansile, lucent lesion completely eroding multiple teeth, with a large, solid, enhancing nodule (*arrow*). The combination of findings is suggestive of the diagnosis. The teeth erosion and solid nodule suggest an aggressive subtype ameloblastoma, which was confirmed by tissue sampling.

---

**Mandibular ameloblastomas are solid, usually slow-growing tumors typically associated with unerupted teeth.**

---

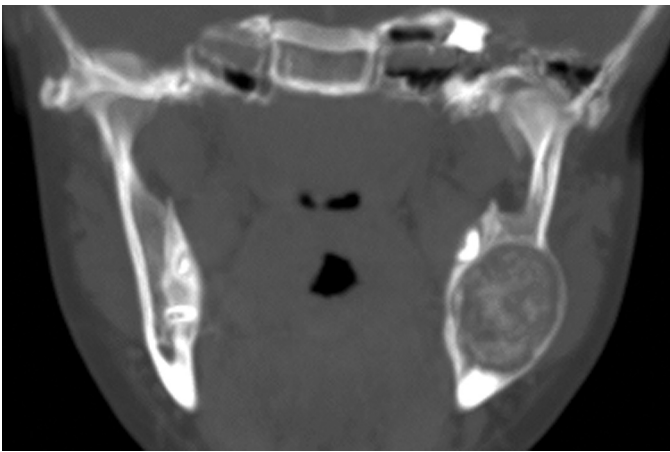#### Cementoblastoma

Cementoblastoma is a rare benign tumor constituting only 1% of odontogenic tumors.<sup>1</sup> They occur primarily in young children, with 75% of cases occurring before the third decade of life. Cementoblastomas arise from the teeth cementoblasts (the outer layer of the tooth root). They have a predilection to the molar/premolar region, with 90% of lesions occurring in these locations. On imaging, cementoblastomas are radiopaque, well-demarcated lesions with a radiolucent border appearing at the edge of the tooth root. Frequently, there is tooth root resorption resulting in a “sunburst” appearance (Figure 5). Treatment typically is resection with removal of the associated tooth to prevent recurrence.

#### Tooth-Related Sclerotic Lesions

##### Florid and Focal Cemento-osseous Dysplasia

Periapical cemental dysplasia is a hamartomatous process that can be focal or florid if it affects more than three quarters of the mandible. It also can affect the maxilla concurrently. Multifocal cemento-osseous dysplasia classically occurs in African American or Asian women in the fourth or fifth decade of life.<sup>5</sup> Focal lesions have a predilection for the anterior mandible, can involve one or few teeth, and early on can mimic inflammatory or infectious lesions.<sup>6</sup> The florid form symmetrically involves the jaw and typically crosses the midline. Imaging demonstrates diffuse expansile lytic and sclerotic masses. Sclerotic lesions typically do not fuse with the tooth root and are above the mandibular canal (Figure 6). Cemento-osseous dysplasia



**Figure 5.** Cementoblastoma. Coronal, nonenhanced CT scan demonstrates an expansile, radiopaque, well-demarcated mandibular lesion with a radiolucent border at the molar region in a child. More than 90% of these lesions occur at the molar/premolar region. Although these lesions are rare, location, appearance, and age group are pathognomonic, and every radiologist should be confident making the diagnosis of cementoblastoma.

typically is asymptomatic but can be painful if complicated by osteomyelitis.

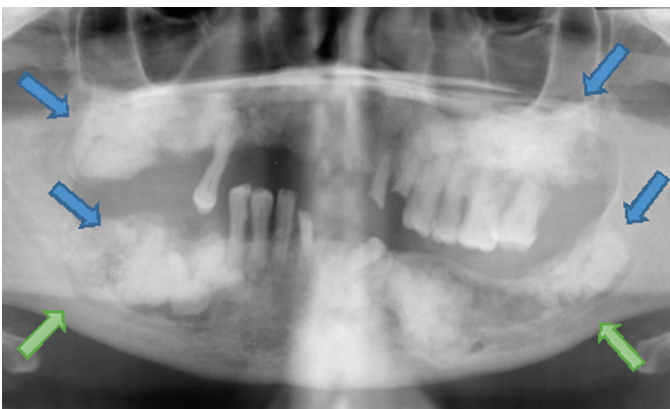
---

**Cemento-osseous dysplasia is a focal or florid, hamartomatous process that primarily affects the mandible but also can involve the maxilla.**

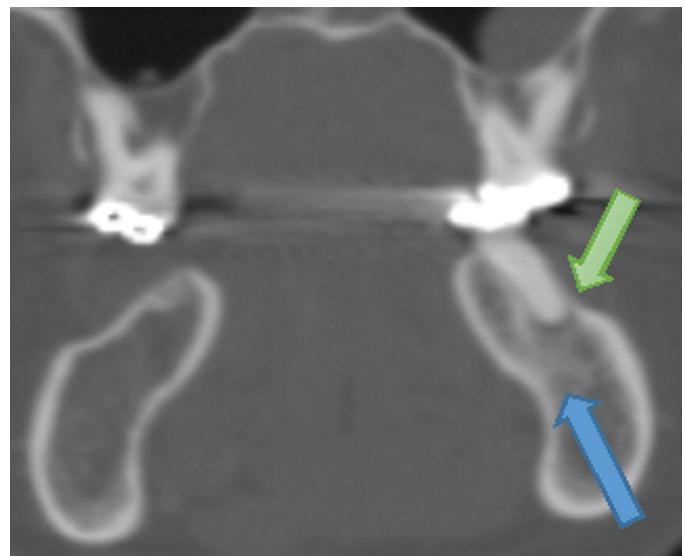
---

### Condensing Osteitis

Condensing osteitis is a periapical inflammation secondary to tooth infection. It usually abuts a tooth root that exhibits evidence of periodontal disease. The adjacent tooth has a periapical abscess or cavity with a decaying dentition. Condensing osteitis usually is seen in the molar area of the mandible, and it is the most common sclerotic lesion of the jaw. It is seen mostly in children or young adults.<sup>5</sup> The



**Figure 6.** Cemento-osseous dysplasia. Panoramic view demonstrates multiple, symmetric sclerotic and lytic, expansile lesions (*blue arrows*) of the mandible and maxilla. The jaw lesions are above the mandibular canal (*green arrows*), and the left maxillary lesion is not fused with the teeth roots. There is also evidence of significant tooth decay. Findings are classical for cemento-osseous dysplasia, another “Aunt Minnie” imaging diagnosis.

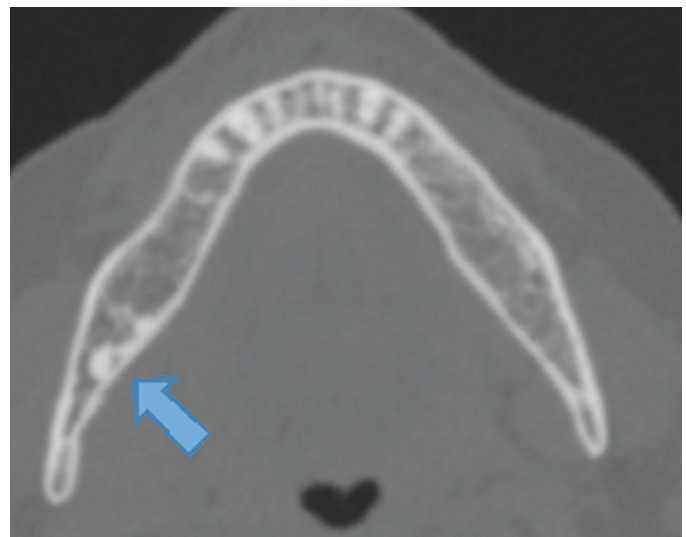


**Figure 7.** Condensing osteitis. Coronal, bone window CT scan demonstrates nonexpansile, poorly defined, sclerotic lesion (*blue arrow*) abutting a molar periapical inflammatory lucency (*green arrow*), typical of condensing osteitis.

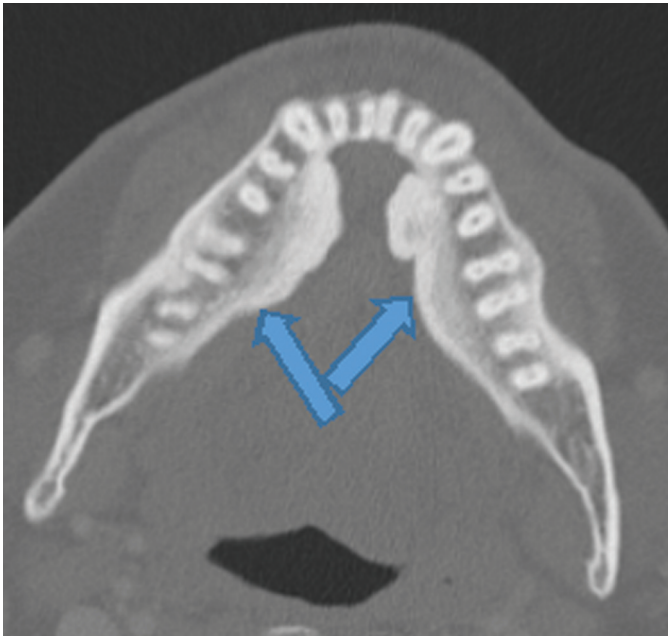
marrow and cancellous bone are replaced by sclerotic compact bone. Imaging follows pathology, demonstrating sclerosis associated with a periapical inflammatory lesion (Figure 7).

### Idiopathic Osteosclerosis

Idiopathic osteosclerosis is an idiopathic focal sclerotic lesion of the mandible; occasionally, multiple lesions are present (Figure 8). It typically occurs in young patients.<sup>5</sup> Idiopathic osteosclerosis usually is asymptomatic and incidentally noted on imaging. It is relatively common in the mandible, and 90% of lesions occur in the mandible. Radiographically, it is a radiopaque/sclerotic area around the tooth (more commonly the premolar and molar region) near the root apex or interradicular region with sharp, angular margins without expansion or a lucent component.



**Figure 8.** Idiopathic osteosclerosis. Axial, nonenhanced, bone window, CT scan demonstrates eccentric, sclerotic lesions with well-defined angulated margins (*arrow*) without associated hypodensity, which suggest the diagnosis of idiopathic osteosclerosis.



**Figure 9.** Torus mandibularis. Axial, bone window, contrast enhanced CT scan demonstrates bilateral buccal cortex exostosis (arrows) consistent with torus mandibularis. Torus mandibularis is a diagnosis often mistaken for more sinister diagnoses, although imaging is virtually diagnostic.

## Sclerotic Non-Tooth-Related Lesions

### Torus Mandibularis

Torus mandibularis represents a bony exostosis composed of cortical bone, typically lacking a medullary component that is covered by mucosa.<sup>5</sup> These bony exostoses usually arise from the lingual cortex of the mandible above the origin of the mylohyoid muscle (Figure 9). These lesions most commonly arise in adults and usually are slow growing with an eventual arrest. Torus mandibularis usually is asymptomatic. The etiology is unknown, but environmental and hereditary factors have been implicated as potential contributors.

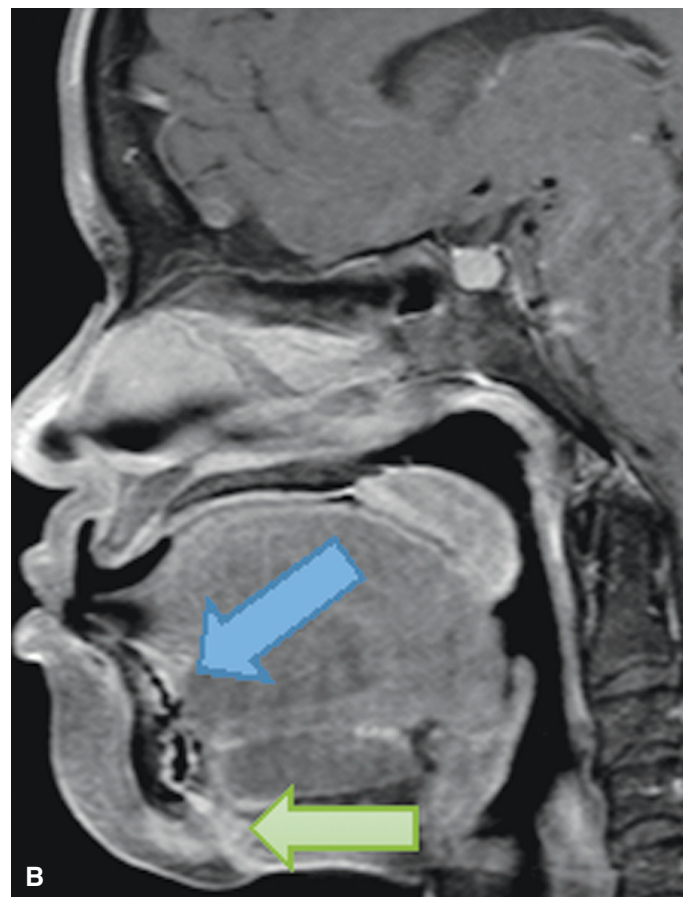
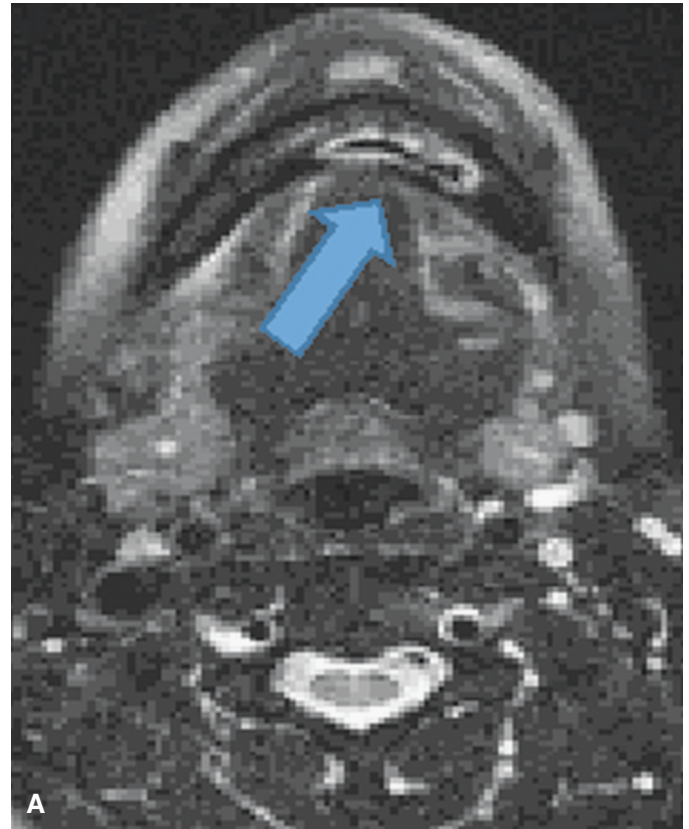
### Infectious

#### Osteomyelitis

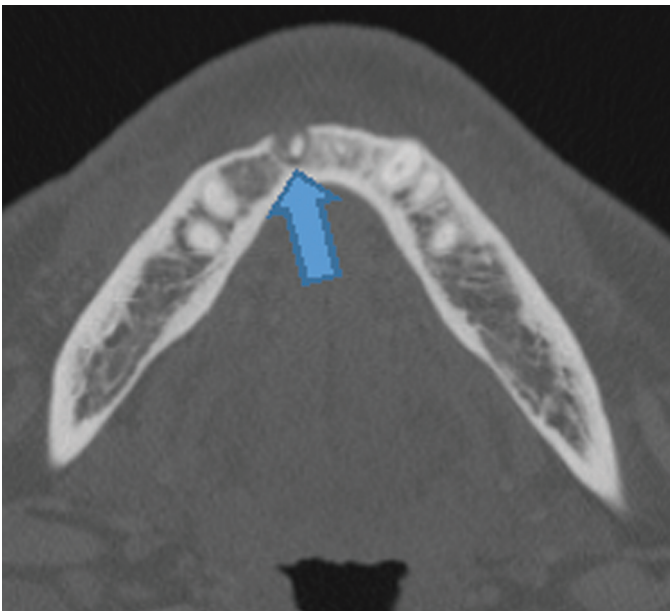
Osteomyelitis of the mandible is most commonly due to underlying tooth infection. Other mechanisms associated with mandibular osteomyelitis include fractures, osteonecrosis, and hematogenous spread of pathogens.<sup>1</sup> Mandibular osteomyelitis can be classified as acute or chronic (lasting more than 1 month). Chronic osteomyelitis can be complicated by sinus tracks, fistulae, bony sequester, or pathologic fractures (Figure 10). Risk factors for osteomyelitis include altered immunity, vascular compromise (such as sickle cell), radiation therapy, and bony conditions. Imaging appearance within the mandible is similar to osteomyelitis in other osseous regions in the body and is dependent on chronicity and associated complications.

#### Apical Periodontitis

Apical periodontitis encompasses the spectrum of periapical cysts, granulomas, and abscesses.<sup>1</sup> The majority of these lesions are secondary to underlying dental carries with a predictable course. Apical periodontitis/abscess usually starts as



**Figure 10.** Osteomyelitis. A: Axial, short T1 inversion recovery MR image demonstrates bone marrow signal abnormality/edema (arrow) in a patient with mandibular pain and “pus draining from skin.” B: Sagittal, fat saturation, postcontrast MR image demonstrates enhancement within the abnormal bone marrow (blue arrow) with an enhancing osteocutaneous fistulous/sinus track (green arrow) explaining the patient’s symptoms. The patient had chronic osteomyelitis with cutaneous fistula.



**Figure 11.** Apical periodontitis. Axial, noncontrast CT scan demonstrates a periapical, round lucency (*arrow*) with cortical break, suggestive of mandibular apical periodontitis.

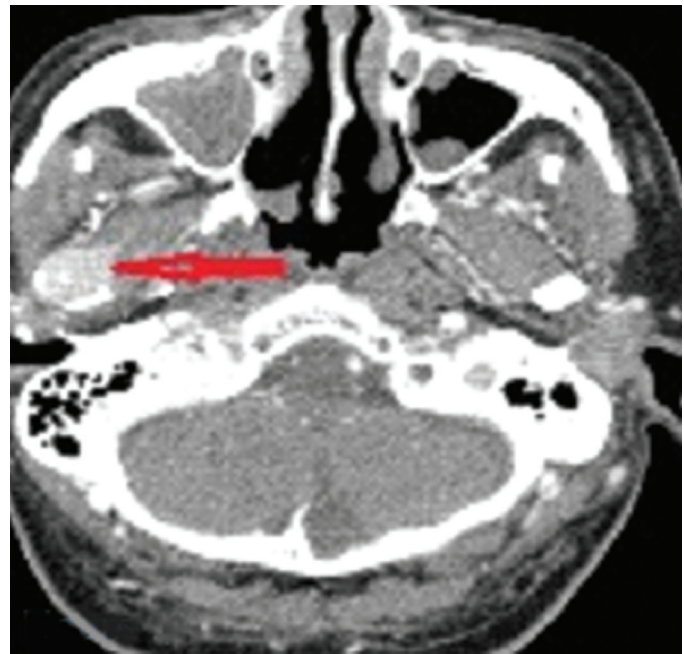a carious tooth that eventually involves the central pulp. The infection then progresses into periapical abscess. If left untreated, osteomyelitis then develops with marrow space extension and, eventually, cortical destruction. Other causes of periodontitis include trauma, postsurgical, and rarely hematogenous spread. On imaging, a mandibular abscess appears as a lucent lesion on noncontrast CT (Figure 11) that exhibits rim enhancement on contrast enhanced images. MRI is more sensitive for detection of periapical abscesses, as it shows loss of normal bone marrow signal, with diffusion-weighted imaging sequences demonstrating restricted diffusion. In addition to making the diagnosis of apical periodontitis, it is important to detect possible associated complications such as periosteal abscess and osteomyelitis. Treatment varies from antibiotics to drainage, depending on disease burden.

## Nonodontogenic Mandibular Tumors

### Mandibular Metastasis

Mandibular metastasis usually is secondary to direct invasion from underlying head and neck malignancy.<sup>1</sup> Systemic metastasis to the mandible is uncommon, with the most common primaries being breast, lung, and renal malignancies. Distant metastasis typically involves the mandibular angle or posterior mandibular body, given their relatively increased vascularity. If metastasis involves the mandibular condyle, it can present as temporomandibular joint disorder. CT imaging typically demonstrates a lucent lesion on bone windows that can be mistaken for a benign lesion. Soft tissue windows on CT or conventional MRI is useful to distinguish the soft tissue component (Figure 12). Rarely, mandibular metastasis can appear as a sclerotic focus in the setting of blastic metastatic primary tumor.

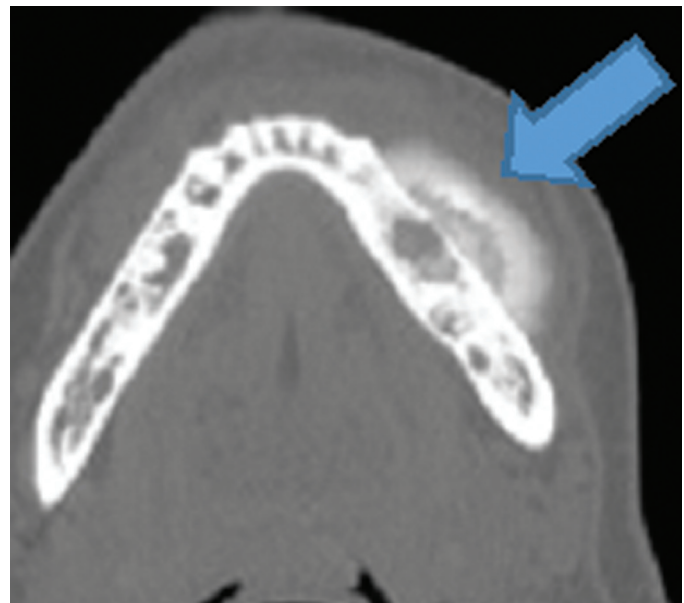
**The majority of mandibular metastasis usually is secondary to direct invasion from underlying head and neck malignancies.**



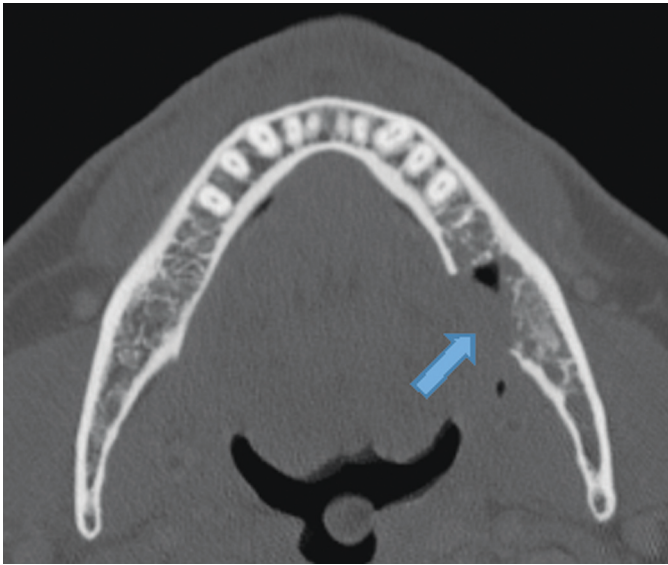
**Figure 12.** Mandibular metastases. Contrast enhanced, soft tissue window CT scan demonstrates an enhancing mass (*arrow*) within the right mandibular condyle, with erosion and expansion of the bony cortex. The patient had a history of renal cell carcinoma. Tissue sampling confirmed metastases to the mandible.

### Osteosarcoma

Osteosarcoma is one of the most common bony primary malignancies; however, mandibular osteosarcomas are rare and constitute only 2% to 10% of all osteosarcomas.<sup>7</sup> Risk factors include prior head and neck radiation therapy, Paget disease of bone, or other known osteosarcoma precursors. Mandibular osteosarcomas typically present one to two decades later than long bone osteosarcomas, with the mean age at presentation within the third decade of life. On imaging, mandibular osteosarcoma exhibits aggressive bony changes,



**Figure 13.** Osteosarcoma. Axial, bone window, nonenhanced CT scan demonstrates a large, dense mass with both osteoid matrix and periosteal reaction at the left mandibular body (*arrow*) with classical lifted perpendicular periosteum with respect to the bone marrow.



**Figure 14.** Osteoradionecrosis. Axial, nonenhanced, bone window, CT scan demonstrates mixed sclerotic and permeative bony destruction of the mandible (*arrow*) with foci of air in a patient who had undergone previous radiation treatment. The imaging findings, in particular air, and the clinical findings are very suggestive of the diagnosis of osteoradionecrosis.

including expansible, erosive, destructive lesions with aggressive periostitis. Occasionally, a classical “sunburst” periosteal appearance is seen (Figure 13). Osteosarcoma of the mandible represents a challenging diagnosis, given its rarity and nonspecific overlapping clinical symptoms. The radiologist is often the first to suggest the diagnosis. Treatment is usually wide excision of the lesion. Neoadjuvant chemotherapy has been effective in reducing tumor burden and improving patient outcomes.

### Osteonecrosis/Osteoradionecrosis

Osteonecrosis of the mandible in adults is not uncommon with bisphosphonate therapy, which often is used to treat bony conditions including osteoporosis, multiple myeloma, metastasis, and Paget disease of bone. Osteoradionecrosis also is relatively common and is seen in up to 37% of patients with head and neck radiation therapy receiving more than a 60-Gy dose.<sup>8</sup> On imaging, osteonecrosis exhibits mixed lytic/sclerotic

changes with associated bony fragmentation and sequestrum. Gas within the involved bones is not always seen but strongly suggests osteonecrosis (Figure 14). The main differential diagnosis to exclude is chronic osteomyelitis.

---

**Osteonecrosis of the mandible is relatively common in patients receiving bisphosphonate therapy and after radiotherapy for head and neck malignancy.**

---

### Conclusion

The mandible is a commonly imaged bone susceptible to multiple pathologies of odontogenic and nonodontogenic origin that have overlapping imaging features and a broad differential diagnosis. This CME activity emphasizes that familiarity with the histologic characteristics and imaging appearance of the common pathologies, their location, demographics, and patient’s clinical history are clues for the diagnosis. Even when following a methodological analysis, many mandibular lesions are not possible to differentiate without a biopsy. However, a combined assessment of all this information allows the radiologist to form a succinct differential diagnosis that can aid in diagnosis and guide clinical management.

### References

1. Dunfee BL, Sakai O, Pistey R, et al. Radiologic and pathologic characteristics of benign and malignant lesions of the mandible. *RadioGraphics*. 2006; 26:1751-1768.
2. Scholl R, Kellett HH, Neumann DP, et al. Cysts and cystic lesions of the mandible: clinical and radiologic-histopathologic review. *RadioGraphics*. 1999;19:1107-1124.
3. Cortell-Ballester I, Figueiredo R, Berini-Aytés L, et al. Traumatic bone cyst: a retrospective study of 21 cases. *Med Oral, Patol Oral Cir Bucal*. 2009;14(5):239-243.
4. Hayashi K, Tozaki M, Sugisaki M, et al. Dynamic multislice helical CT of ameloblastoma and odontogenic keratocyst: correlation between contrast enhancement and angiogenesis. *J Comput Assist Tomogr*. 2002;26(6): 922-926.
5. Curé JK, Vattoth S, Shah R. Radiopaque jaw lesions: an approach to the differential diagnosis. *RadioGraphics*. 2012;32:1909-1925.
6. Resnick CM, Novelline RA. Cemento-osseous dysplasia, a radiological mimic of periapical dental abscess. *Emerg Radiol*. 2008;15(6):367-374.
7. Fernandes R, Nikitakis NG, Pazoki A, et al. Osteogenic sarcoma of the jaw: a 10-year experience. *J Oral Maxillofac Surg*. 2007;65(7):1286-1291.
8. Hoff AO, Toth B, Hu M, et al. Epidemiology and risk factors for osteonecrosis of the jaw in cancer patients. *Ann NY Acad Sci*. 2011;1218(1):47-54.

## CME QUIZ: VOLUME 40, NUMBER 6

To earn CME credit, you must read the CME article and complete the quiz and evaluation on the enclosed answer form, answering at least seven of the 10 quiz questions correctly. **Select the best answer and use a blue or black pen to completely fill in the corresponding box on the enclosed answer form.** Please indicate any name and address changes directly on the answer form. If your name and address do not appear on the answer form, please print that information in the blank space at the top left of the page. Make a photocopy of the completed answer form for your own files and mail the original answer form in the enclosed postage-paid business reply envelope. Only two entries will be considered for credit. Your answer form must be received by Lippincott CME Institute, Inc., by **March 14, 2018**. All CME participants will receive individual issue certificates for their CME participation monthly. These individual certificates will include your name, the publication title, the volume number, the issue number, the article title, your participation date, the AMA credit awarded, and any subcategory credit earned (if applicable). For more information, call (800) 638-3030.

**All CME credit earned via *Contemporary Diagnostic Radiology* will apply toward continuous certification requirements. ABR continuous certification requires 75 CME credits every 3 years, at least 25 of which must be self-assessment CME (SA-CME) credits. All SAM credits earned via *Contemporary Diagnostic Radiology* are now equivalent to SA-CME credits ([www.theabr.org](http://www.theabr.org)).**

**Online quiz instructions:** To take the quiz online, **log on to your account at [www.cdrnewsletter.com](http://www.cdrnewsletter.com)**, and click on the “CME” tab at the top of the page. Then click on “Access the CME activity for this newsletter,” which will take you to the log-in page for <http://cme.lww.com>. Enter your **username** and **password**. Follow the instructions on the site. You may print your official certificate **immediately**. Please note: Lippincott CME Institute **will not** mail certificates to online participants. **Online quizzes expire on the due date.**

- Which one of the following lesions typically crosses the mandibular midline?
  - Dentigerous (follicular) cyst
  - Keratocystic odontogenic tumor
  - Ameloblastoma
  - Cementoblastoma
  - Florid cemento-osseous dysplasia
- Which one of the following conditions is the *most* common cause of mandibular osteomyelitis?
  - Tooth infection
  - Radiation osteonecrosis
  - Fracture
  - Hematogenous spread of pathogens
  - Bisphosphonate therapy
- Which one of the following is the *most* common developmental mandibular lesion?
  - Dentigerous (follicular) cyst
  - Keratocystic odontogenic tumor
  - Ameloblastoma
  - Cementoblastoma
  - Osteosarcoma
- Figure 15 is a coronal, noncontrast CT scan of the mandible of a 22-year-old man. The *most* likely diagnosis is
  - osteosarcoma
  - dentigerous (follicular) cyst
  - focal cemento-osseous dysplasia
  - cementoblastoma
  - torus mandibularis
- Which one of the following mandibular lesions occurs primarily in young children?
  - Dentigerous (follicular) cyst
  - Keratocystic odontogenic tumor
  - Ameloblastoma
  - Cementoblastoma
  - Osteosarcoma
- Which one of the following statements regarding mandibular osteosarcomas is *false*?
  - They are rare.
  - They may have a classical “sunburst” periosteal appearance on CT.
  - Paget disease of bone is a risk factor.
  - They typically present at an earlier age than long bone osteosarcomas.
  - Prior head and neck radiation therapy is a risk factor.
- What percentage of patients treated with radiation therapy (>60-Gy dose) for head and neck malignancy develops mandibular radiation osteonecrosis?
  - Less than 10
  - 10 to 20
  - 30 to 40
  - 50 to 60
  - 100
- Which one of the following mandibular lesions can have a “soap bubble” imaging appearance?
  - Dentigerous (follicular) cyst
  - Keratocystic odontogenic tumor
  - Ameloblastoma
  - Cementoblastoma
  - Osteosarcoma
- All of the following are imaging features of keratocystic odontogenic tumors of the jaw, *except*
  - multilocular lesion
  - lucent lesion
  - expansile lesion
  - cortical thinning
  - associated daughter cysts
- Which one of the following is the *most* common location for a traumatic bone cyst in the head and face?
  - Maxilla
  - Mandible
  - Frontal bone
  - Pterygoid plate
  - Temporal bone

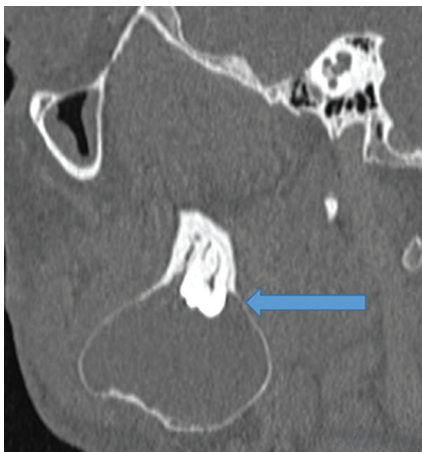

Figure 15.