

ASSESSMENT AND TREATMENT TECHNIQUES FOR CANINE SACROILIAC JOINT DYSFUNCTIONS

Laurie M. Edge-Hughes, BScPT, MAnimSt (Animal Physio), CAFCI, CCRT
The Canine Fitness Centre Ltd, Calgary, Alberta, T2G 1Y7, Canada
physio@fourleg.com ~ www.caninefitness.com

Sacroiliac joint dysfunction is a term used in humans to describe pain in or around the region of the sacroiliac joint (SIJ) which is presumed to be due to misalignment, abnormal movement or insufficient stabilization of the SIJs.²² Dysfunctions and/or lesions affecting the canine sacroiliac joint have received little attention in veterinary research and/or clinical practice. However, the sacroiliac joint in the dog and possibly in other small animals is similar enough to that in humans to argue that sacroiliac joint lesions and dysfunctions may well be a potential source of back, pelvic and/or hind limb pain. Subsequently, similar diagnostics and treatment techniques or therapies to those used in humans may be applied to dogs.

ANATOMY

The SIJ in dogs is formed by both synovial and cartilaginous elements and is stabilized by the dorsal and ventral sacroiliac ligaments as well as the sacrotuberous ligament.(Evans 1993) It is capable of an average of 7° of rotation.¹³ No other motions (shears or translations) have been tested. The canine SIJ has asymmetric and varying angles of dorsoventral slope, medial-lateral slope and concavity between and within breeds, as well as the SIJ articular surface and, the ligamentous attachment sites are proportionately smaller in large dogs.^{1,2,3,14} Therefore theoretically, higher forces are exerted on the SIJs in larger breed dogs. Radiographic appearance of calcification may occur in more than 50% of dogs by the age of 1.0 – 1.5 years.¹⁴ Chronic overuse, microtrauma from daily repetitive activities, or hormonal relaxation in females might precipitate calcification are proposed etiologic factors precipitating this finding.¹⁴ The findings could also potentially suggest that in dogs, SIJ dysfunctions or inflammation may give rise to calcification. However, Vleeming et al 1990 reported that with standard X-rays, the cartilage covered ridges and depressions in humans can easily be misinterpreted as pathologic because of the well-known over projections in SIJs, but these cartilage covered ridges are not pathologic.²⁵

The SIJ is reportedly innervated by the dorsal rami of the first, second, and third or fourth sacral nerves (S1 to S3 or S4) and has sensory innervation from the dorsal root ganglia of the first lumbar (L1) to the third sacral (S3).^{10,20} Thus sacroiliac joint dysfunctions may also cause pain beyond the pelvic or back region. Human studies have found sacroiliac joint pain referral patterns that range from the upper lumbar spine to anywhere in the lower limb.^{6,24}

Human studies have suggested that sciatica may ensue secondary to compression as a result of piriformis tension (known as piriformis syndrome).¹¹ Any lesion of the sacroiliac joint may cause an inflammatory reaction of the piriformis muscle and its fascia since their origin lies at the capsule of the sacroiliac joint.^{12,26} This phenomenon has been classified as secondary piriformis syndrome or pelvic outlet syndrome in cases where there is buttock pain with or without radiation down the leg (as this depends on the location of the pathology in relation to structures adjacent to the sciatic notch) provided that spinal pathology is excluded.²¹ In a recent study and review, it has been speculated that piriformis syndrome may be as common as herniated discs in the cause of sciatica.⁹ In dogs, the origin of the piriformis muscle is reported to be the lateral surface of the third sacral (S3) and first coccygeal vertebrae (Cxy1) and/or the border and ventral surface of the sacrum and sacrotuberous ligament.^{8,23} The phenomenon of piriformis spasm and tension has been hypothesized to occur in association with sacroiliac joint dysfunctions in the dog.⁷

CLINICAL DIAGNOSTIC TESTS

Sacroiliac joint dysfunction in humans is commonly tested by kinematic (movement) tests, pain provocation stress tests, and land-marking evaluation.^{14,16,17,18} A ‘gold standard’ test for the SIJ does not yet appear to exist and hence is impossible to compare against when advocating clinical tests for SIJ

dysfunctions. CT scan, MRI, nuclear scintigraphy, infrared thermography, ultrasonography and analgesic injections are all too non-specific to be considered definitive.^{5,16} Color Doppler imaging that detects SIJ asymmetric laxity shows promise, but has not been utilized for this purpose in dogs.⁴

Pelvis Alignment: Utilizing bilateral, simultaneous palpation of each the ischial tuberosities and iliac crests respectively while the animal is positioned in a 'square' and equally balanced stance position. Ischial tuberosities can be identified by running the examiners thumb nails up against the undersurface of the most caudal portion of the ischial tuberosities. The iliac crests were located by running the examiners fingers down the sides of the back until coming in contact with the wings of the ilia. Subjective and objective assessments can be made. Additionally, palpation using the caudal dorsal iliac spines can be utilized in both standing and sitting.

Piriformis Pain Tolerance: A manual technique of strumming over the piriformis muscle (caudal to cranial) on each side and subjectively quantifying the animal's response on each.

Sacrospinous Ligament Palpation: Palpation of the sacrospinous ligament may reveal an asymmetry of tone from side to side, which can be recognized as a unilateral dysfunction at the SIJ depending upon relative position of the ilium and sacrum. In some instances a very taut sacrospinous ligament may be painful on palpation as compared to the contralateral side.

Pain Provocation Stress Tests: A thigh thrust technique (modified from human use) is conducted with the animal in side lying. A slow, deliberate dorsal displacement force is applied through the dog's thigh with the hip in mid-range and slightly abducted (to avoid hip luxations in dysplastic dogs). The tester's other hand should be on the sacrum to stabilize. The dog's reaction is noted. This test supposedly stresses the dorsal sacroiliac ligaments.

Kinematic Testing: This testing in humans requires a volitional flexion of the limb or flexion of the trunk while the examiner palpates anatomical landmarks of the pelvis and compares the amount and quality of the movement. In the dog, passive flexion and extension of the hip with the examiner palpating the quantity and quality of movement of the iliac spines can detect differences from side to side.

Motor Control / Coordination Testing: With the animal standing, slowly lift one hind leg off the ground. The animal with proper motor control should be able to maintain a stable position without shifting or rotating the spine. While performing this maneuver, the examiner can simultaneously palpate individual muscles/muscle groups to evaluate muscle contractions (required for pelvis stabilization); the contralateral gluteal muscle, the ipsilateral latissimus dorsi, the deep fibres of multifidus bilaterally (just adjacent to the spinous processes), the abdominals and/or the epaxial muscles. Problems in motor control and timing may precede lumbopelvic issues or arise as a result of them.

Flexibility Testing: Several different muscles can affect the motion, mobility and pull on the pelvis. Evaluation of the passive elongation capacity of the hamstrings, piriformis, sartorius, iliopsoas, adductors, erector spinae, tensor fascia lata and oblique abdominals should be conducted. Compare from side to side, assessing quality and quantity of the movements.

Shear tests: In a clinical setting, human physiotherapists utilize translatory movement assessment to detect hypermobility and hypomobility dysfunctions. This requires good palpation skills, an ability to detect movement endfeels and positioning and hand placement to perform the shear tests without causing excessive discomfort over the bony structures being used to push through. Shears to be evaluated should include: sacral nutation, counternutation and rotation; superior and inferior translations; dorsal and ventral translations (thigh thrust technique and traction technique); dorsal rotation (posterior); ventral rotation (anterior); and compressions through both wings of the ilia.

Other: Palpation of the deep fibres of multifidus (adjacent to the spinous process) is useful in detecting atrophy. Palpation of the linea alba (especially in post-partum or spayed bitches) to detect any separation. Palpation of the symphysis pubis to detect any pain or positional faults. Observation of gait: lameness may be detected or evidence of a Trendelenburg gait. Posture evaluation may detect excessive lordosis, kyphosis or off-loading of a limb. Reflexes should be conducted for each muscle / muscle group supplied by different nerves to detect a lower motor neuron lesion which has been seen to occur secondarily to SIJ lesions by this author. Dural mobility / nerve glides can be assessed to detect a nerve entrapment (although much harder in dogs due to a lack of subjective patient feedback).

DIFFERENTIAL DIAGNOSES

L7SI: Lesions at this level would show epaxial muscle spasm adjacent to this vertebral segment, which SIJ lesions would not. Lesions at this level might affect pelvis alignment. Lesions at this level could cause nerve root irritation which might affect all nerves supplied by L7 and possibly S1 – S3, and would therefore affect more than just piriformis muscle sensitivity. Lesions at this level should not be affected by the thigh thrust pain provocation test. Lesions at this level might show as pain in very end ranges of hip flexion or extension but iliac spine kinetics should be equal from side to side prior to the onset of pain.

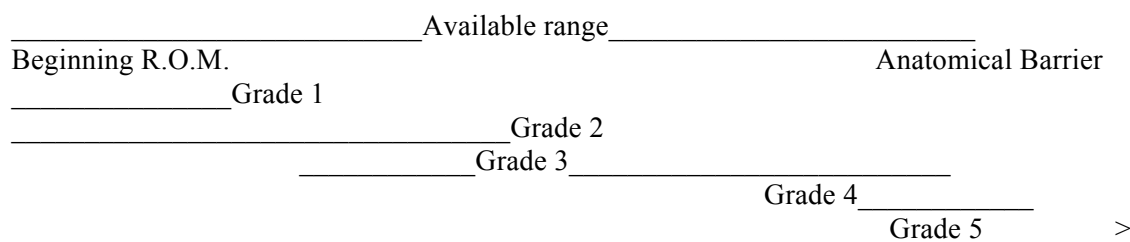
Hip Dysplasia: Hip dysplasia could result in an inability to stand square and therefore affect pelvis alignment. Hip dysplasia does not clinically correlate with piriformis muscle sensitivity. The thigh thrust technique could result in subluxation of the femoral head from the acetabulum in the presence of hip dysplasia if not modified to incorporate hip in abduction. Hip extension is clinically painful earlier in the range and before movement of the iliac spines is detected in dogs with painful hip dysplasia.

TREATMENT

Treatment of the sacroiliac joint should encompass ‘Form Closure’ (aimed at restoring mobility and correction of osseous alignment), ‘Force Closure’ (addressing muscular strengthening or lengthening in order to stabilize the joint or reduce abnormal forces or pulls on the pelvis), and Retraining of Motor Control within the region (in order to re-establish normal patterns of movement required for locomotion as well as stabilization).¹⁸

FORM CLOSURE:

The shear tests are also utilized as treatment techniques in the dog. Please see above. The tests are then turned into mobilizations and can be graded according to Maitland’s Mobilization Scale (below).¹⁹



- Grades 1 and 2 have a neuromodulatory / pain relieving effect
- Grades 2 and 3 have a vascular effect
- Grades 3 and 4 have a mobilizing effect
- Grade 5 is a manipulation

FIGURE 1: MAITLAND’S MOBILIZATION SCALE

FORCE CLOSURE:

Strengthening of the Gluteal muscles specifically may be accomplished by hill walking (especially up steep hills and zig zag down hill), hip abduction (peanut butter in the groin exercise) and/or destination jumping (onto the bed or a platform or over a small jump).

Flexibility will include stretching of the erector spinae (hanging over a ball or cookies under the chest), piriformis (hip flexion and external rotation stretch), hamstrings (hip flexion with stifle extension), sartorius (hip extension with stifle flexion), the oblique abdominal (rotations), iliopsoas (hip extension), adductors (abduction), and/or latissimus dorsi (shoulder extension stretches).

MOTOR CONTROL AND TIMING:

This can be accomplished with static balancing (3 leg standing) by lifting the unaffected hind limb off the ground and making the animal balance for 15 seconds or up to 2 minutes. Incorporation of muscle facilitation techniques can be used (ie tapping on the muscles, neuromuscular electrical stimulation, hand positioning or manual cues) to problematic muscles (i.e. gluteals, latissimus dorsi, transverse abdominus, lumbar multifidus and/or the pelvic floor (i.e. using the pudendal reflex). Another technique might be crossed-leg standing (lifting the unaffected hind limb and its opposite front limb) with balancing for 15 seconds or longer as able. Stationary standing while imparting a rotational hold or small rotational wiggle on the thorax, lumber or pelvic regions may stimulate multifidus contraction.

ADDITIONAL THERAPEUTICS

Advanced proprioceptive retraining could utilize the same balancing techniques as listed above but done on an unstable surface (i.e. mini trampoline, large wobble board, or camping foam). *Endurance retraining* is best accomplished by performing repetitions. *Ballistic movement retraining* might include slow retraining of a fast recall from a sit, short bursts of fetching, small jumps or use of agility equipment and training. *Global hypertonicity or rigidity* can be addressed by stretches, myofascial holds, trigger point releases or ‘Gunn’ intramuscular stimulation. Complete SIJ retraining in a human would also sometimes incorporate breath retraining, self muscle-releasing techniques and self monitoring, all of which are not particularly trainable in a dog.

The creation of a clinical profile and series of tests that point towards the diagnosis of SIJ lesions or dysfunctions as the source of back and/or hind limb problems and/or pain in dogs could have a large impact on the clinical practice of veterinarians and animal health care practitioners. The sacroiliac joint should be included in any physical assessment of a neuromusculoskeletal problem in a dog. Treatment should be comprehensive and include both joint repositioning (mobilizations) as well as targeted exercise programming to attain joint stability and proper lumbopelvic functioning. More clinical and scientific research needs to be conducted in the area of the canine SIJ.

REFERENCES

1. Breit, S, Kunzel, W: On biomechanical properties of the sacroiliac joint in purebred dogs. *Ann Anat.* 183: pp 145 – 150, 2001.
2. Breit S, Knaus I, Kunzel W: Use of routine ventrodorsal radiographic views of the pelvis to assess inclination of the wings of the sacrum in dogs. *AJVR.* 63 (9): pp 1220 – 1225, 2002.
3. Breit S, Knaus I, Kunzel W: The gross and radiographic appearance of sacroiliac ankylosis capsularis ossea in the dog. *Res Vet Sci.* 74: pp 85 – 92, 2003.
4. Damen L, Buyruk HM, Guler-Uysal F et al: The prognostic value of asymmetric laxity of the sacroiliac joints in pregnancy-related pelvic pain. *Spine.* 27 (24): pp 2820 – 2824, 2002.
5. Dreyfuss P, Dreyer SJ, Cole A, Mayo K: Sacroiliac joint pain. *J Am Acad Orthop Surg.* 12 (4): pp 255 – 265, 2004.
6. Dreyfuss P, Michaelsen M, Pauza K, McLarty J, Bogduk N: The value of medical history and physical examination in diagnosing sacroiliac joint pain. *Spine.* 21 (22): pp 2594 – 2602, 1996.
7. Edge-Hughes LM: Check out that pelvis. *CHAP Newsletter.* Summer/Fall: pp 4 – 5, 2001.

8. Evans HE: Arthrology. In *Evans ed. Millers' Anatomy of the Dog, 3rd ed.* WB Saunders Co: Philadelphia PA, p 244, 1993.
9. Filler AG, Haynes J, Jordan SE et al: Sciatica of nondisc origin and piriformis syndrome: diagnosis by magnetic resonance neurography and interventional magnetic resonance imaging with outcome study of resulting treatment. *J Neurosurg Spine.* 2: pp 99 – 115, 2005.
10. Fortin JD, Kissling RO, O'Connor BL, Vilensky JA: Sacroiliac Joint Innervation and Pain. *Am J Orthop.* Dec: pp 687 -690, 1999.
11. Foster MR: Piriformis syndrome. *Orthopedics.* 25 (8): pp 821 – 825, 2002.
12. Freiberg AH: Sciatic pain and its relief by operations on muscle and fascia. *Arch Surg.* 34: pp 337 – 349, 1937.
13. Gregory C, Cullen J, Pool R, Vasseur P: The Canine Sacroiliac Joint. Preliminary study of anatomy, histopathology and biomechanics. *Spine.* 11 (10): pp 1044 – 1048, 1986.
14. Grieve E.: Diagnostic tests for mechanical dysfunction of the sacroiliac joints. *J Manual & Manip Ther.* 9 (4): pp 198 – 206, 2001.
15. Knaus I, Breit S, Kunzel W, Mayrhofer E: Appearance and incidence of sacroiliac joint disease in ventrodorsal radiographs of the canine pelvis. *Vet Rad.* 45 (1): pp 1 – 9, 2004.
16. Kokmeyer DJ, van der Wurff P, Aufdemkampe G, Fickenscher TCM: The reliability of multitest regiments with sacroiliac pain provocation tests. *J Manipulative Physiol Ther.* 25 (1): pp 42 – 48, 2002.
17. Laslett M, Young SB, Aprill CN, McDonald B: Diagnosing painful sacroiliac joints: A validity study of a McKenzie evaluation and sacroiliac provocation tests. *Aus J Physiother.* 49: pp 89 – 97, 2003.
18. Lee, D ed: *The Pelvic Girdle, An approach to the examination and treatment of the lumbopelvic-hip region.* 3rd Ed. Churchill Livingstone, Toronto. 2004.
19. Maitland G, Hengeveld E, Banks K, English K: *Maitland's Vertebral Manipulation.* (Elsevier Butterworth Heinmann: Toronto), 2005.
20. Murata Y, Takahashi K, Yamagata M et al: Origin and pathway of sensory nerve fibers to the ventral and dorsal sides of the sacroiliac joint in rats. *J Orthop Res.* 19: 379 – 383, 2001.
21. Papadopoulos EC & Khan SN: Piriformis syndrome and low back pain: a new classification and review of the literature. *Orthop Clin N Am.* 35: pp 65 – 71, 2004.
22. Riddle DL, Freburger JK: Evaluation of the presence of sacroiliac joint region dysfunction using a combination of tests: A multicenter intertester reliability study. *Phys Ther.* 82 (8): pp 772 – 781, 2002.
23. Sisson S & Grossman JD: The Muscles of the Dog. In *Anatomy of the Domestic Animals.* W.B. Saunders Company, Philadelphia, PA, 1953.
24. Slipman CW, Jackson HB, Lipetz JS et al: Sacroiliac joint pain referral zones. *Arch Phys Med Rehabil.* 81 (Mar): pp 334 – 338, 2000.
25. Vleeming A, Stoeckart R, Volkers ACW, Snijders CJ: 'Relation between form and function in the sacroiliac joint. Part 1: Clinical anatomical aspects.' *Spine.* 15(2): pp 130 – 132, 1990.
26. Yeoman W, Lond MB: The relation of arthritis of the sacro-iliac joint to sciatica. *Lancet.* 212: pp 1119 – 1112, 1928.