

Name _____
Ms. Gabriel/Mr. McManus

Date _____ Period _____
AP Psychology

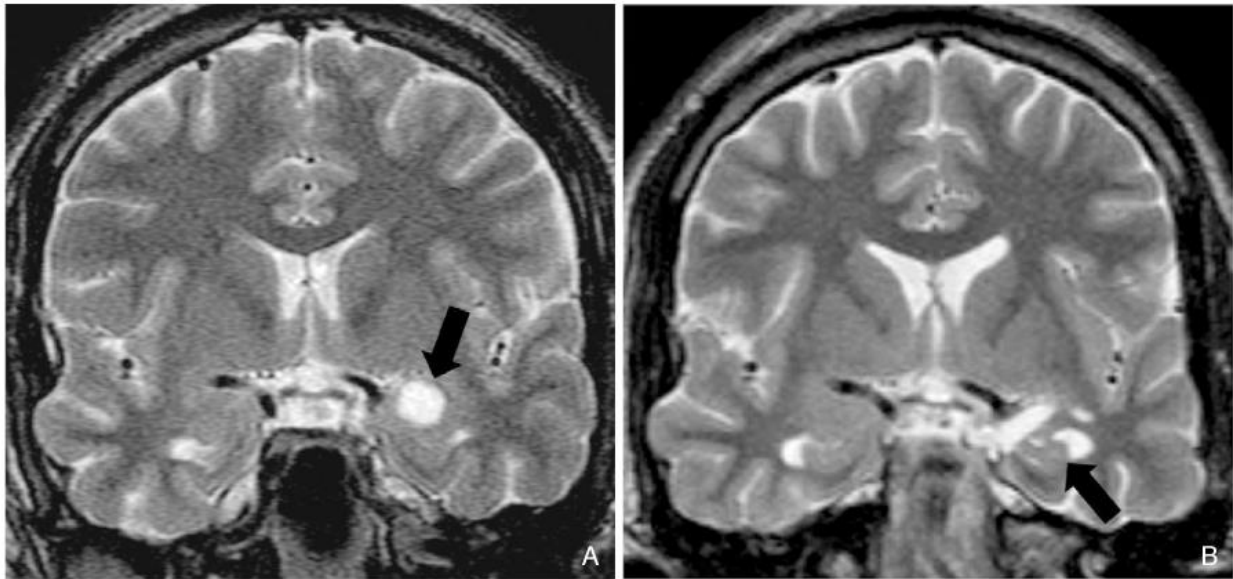
Bad Night in the ER

Bill

Bill is a 32-year-old single man with a rather normal health history. He was brought to the ER by law enforcement for treatment of a laceration (cut) beneath his right eye that was sustained during a fist fight at a local coffee shop. According to witnesses, Bill became irate when the person in front of him ordered a complicated drink that would delay his own order. He started making rude comments and, when the person in front of him asked that he stop, Bill started assaulting the man and a fight broke out.

Up until this year, Bill had no history of violent behavior. However, 3 months ago police were called to his apartment to resolve a dispute between Bill and his girlfriend, who later left him, citing his “out of control anger” as the reason. Concerned about his increasing irritability at work, his employer referred him for anger management training.

Given Bill’s recent fist fight, the physician who completed the intake ordered an MRI to rule out concussion or intracranial bleeding. Although no sign of TBI or bleeding was evident, an abnormal growth was found in the area of his limbic system (indicated by the arrows in the image below).



Jennifer

Jennifer is a 24-year-old patient who was brought to the ER following a very serious car accident. Emergency Responders who arrived at the scene found her unconscious with limited breathing.

By the time she arrived at the ER, Jennifer was unable to breathe on her own. She has been unresponsive to tests of pain sensitivity in her fingers and toes, and her pupils do not constrict when bright lights are shined into her eyes. She requires life support to maintain respiration and heart function.

A CT scan revealed extensive intracranial bleeding. Trepanation was attempted to reduce intracranial pressure (ICP), but the surgeon who performed the procedure is not confident she will be able to recover, even if her ICP returns to normal.

Jin

Jin is a 43-year-old married male, who arrived at the ER concerned that he might be having a heart attack. He is sweaty, his pulse is elevated, and his blood pressure is high (151/90). However, ultrasound imaging revealed no blockages of arteries in the heart.

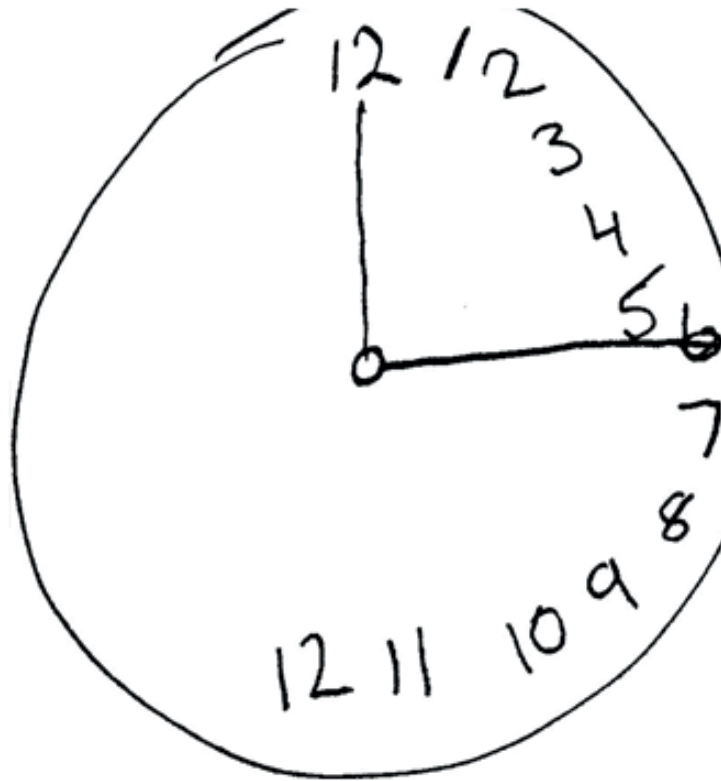
Jin reports that he has been feeling very stressed lately. He is under a great deal of pressure at work and is constantly worried that he will miss a deadline. He sometimes drinks alcohol simply to relax, and has been experiencing gastrointestinal distress periodically over the past couple of months (constipation, diarrhea).

A follow-up EKG revealed that Jin's heart is healthy, so he is not presently at risk for a heart attack. He remains in a state of agitation, however, worried that, "I'll never be able to calm down." Jin was encouraged to make an appointment with a counselor or psychotherapist to get assistance with managing his stress levels.

Maggie

Maggie is a 45-year-old married woman who suddenly developed an apparent visual impairment. She is communicating well and reports no injury to the eyes, although she does wear glasses.

Upon examination, you find that she is demonstrating “left visual field neglect,” meaning she seems not to notice anything presented in her left visual field when looking straight ahead. When you ask her to complete the “Draw-a-Clock Test,” this is what she produces:

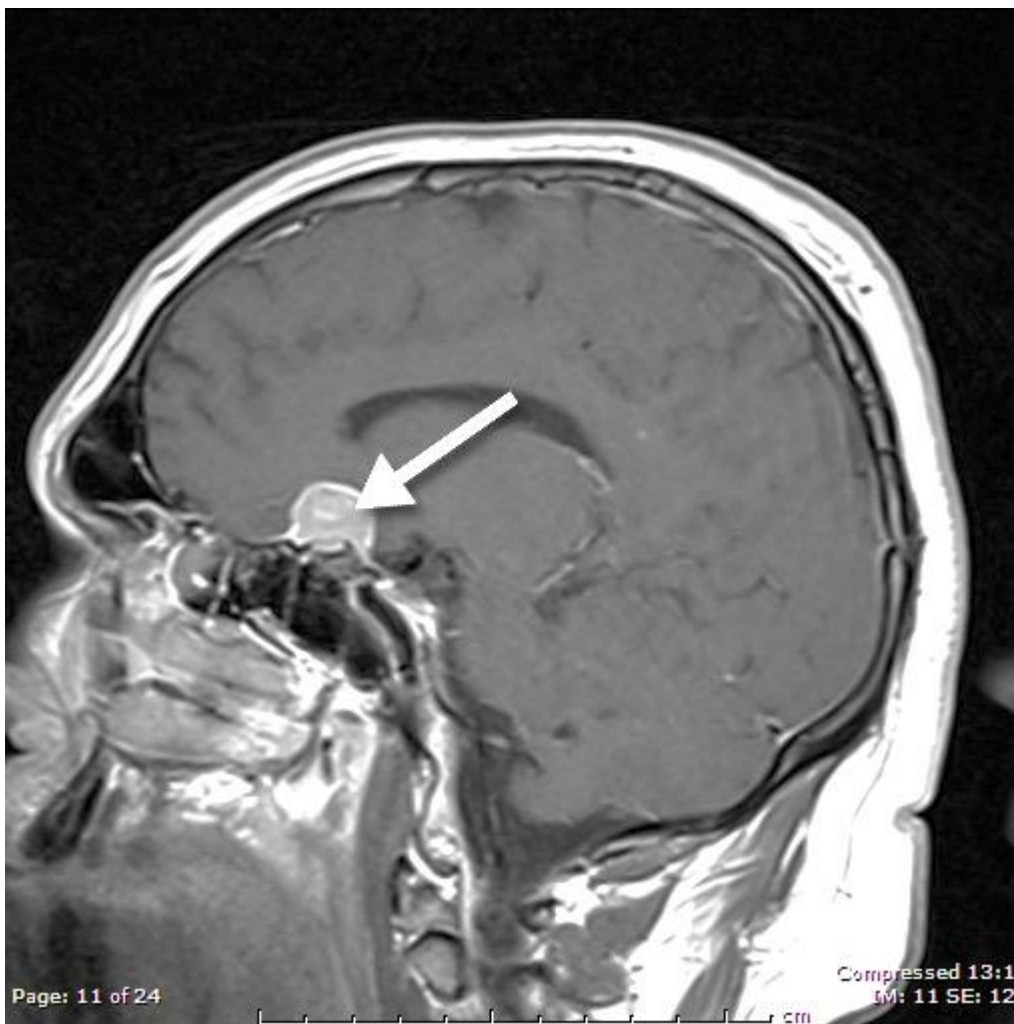

Scott

Scott was brought to the ER after passing out while doing yard work. “I stopped sweating,” he said. “At first I didn’t notice or pay attention to the fact that I wasn’t sweating, but then my body overheated and I passed out.” He was alone at the time, so when he woke up he called an ambulance.

At first, it was presumed Scott was dehydrated. But he revealed that, during the past month, he had been drinking a lot of water (more than a liter a day) but continues to feel thirsty. His appetite had also declined during that time, and he was losing weight, despite all of the water he was drinking.

An MRI was ordered, and it revealed a growth deep within his brain.

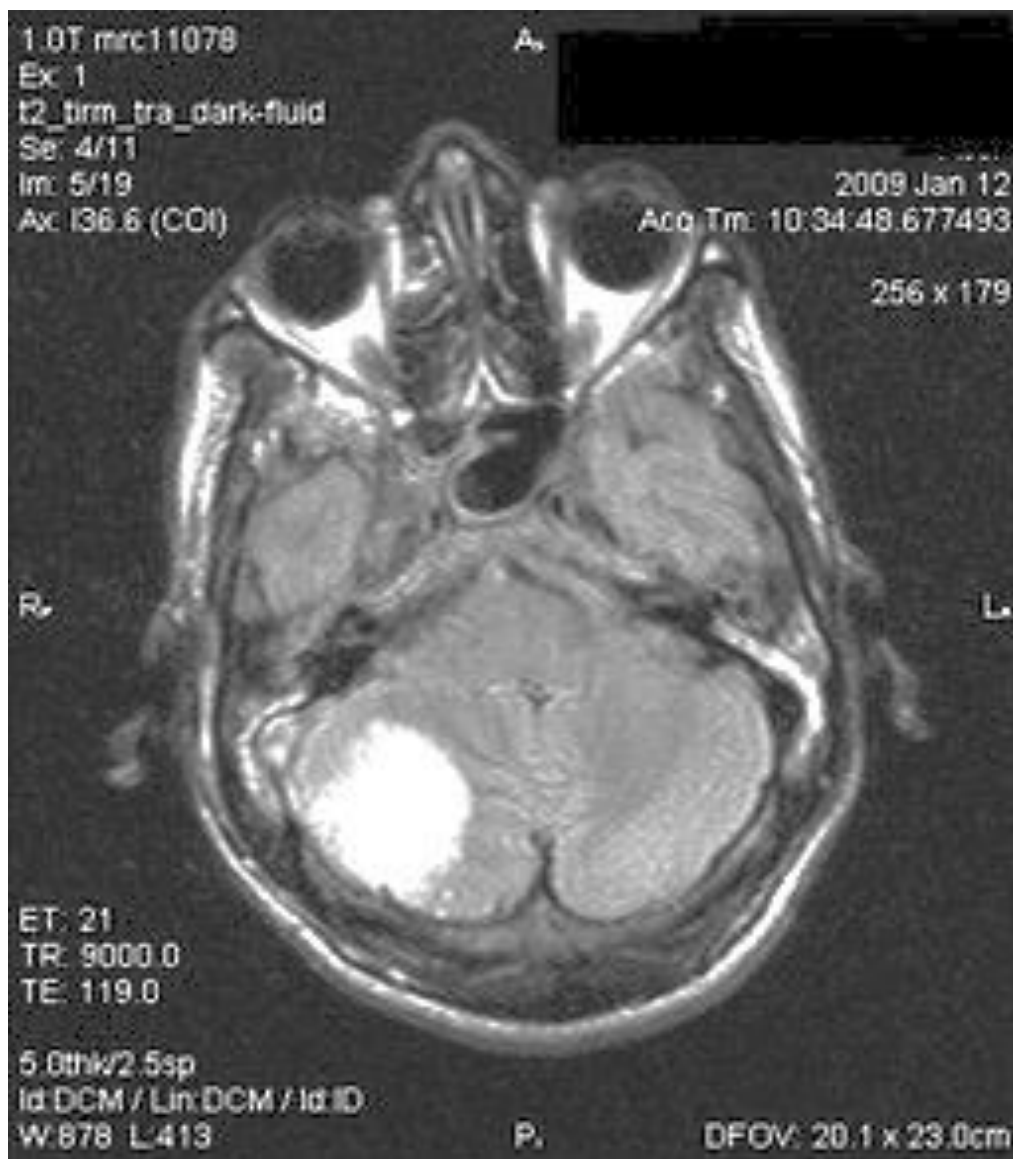

Susan

Susan is an 80-year-old female who currently takes medication to control her blood pressure. She began feeling nauseated this evening, and the staff at her assisted living facility called for an ambulance when she fell after getting up from the dinner table. An X-ray reveals a fracture in her left arm, which occurred during her fall.

She had previously used a cane for assistance while walking, but is now unable to walk in a coordinated fashion. When you ask her to touch her right index finger to her nose, she does so in a halting, jerky motion and nearly hits her own face. Similarly, she has difficulty raising each foot in a coordinated fashion while in a seated position.

An MRI reveals the following:



Maria

Maria is a 12-year-old female who was in a four-wheeler accident two months ago. She was thrown from the ATV and suffered a skull fracture. Although her skull has now healed, Maria's mother has brought her in for evaluation because she is convinced that something continues to be wrong with her daughter. She says, "Maria is simply not herself."

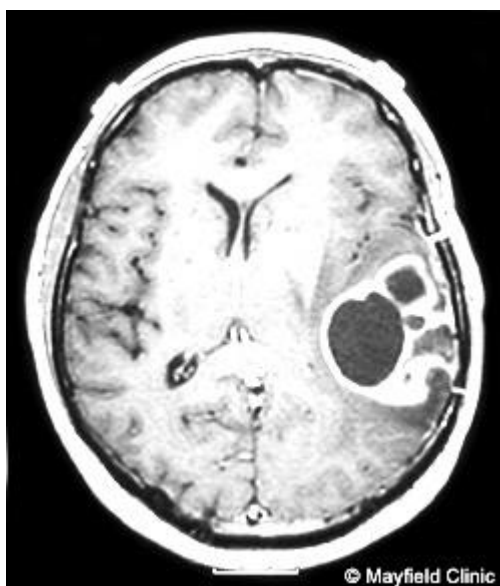Maria has been irritable, and prone to angry outbursts. She experiences crying spells, and an apparent lack of concentration. Her teachers report that she often fails to bring required materials to class and that she is easily frustrated. Tonight, at home, when unable to complete a set of math problems assigned by her teacher, she grew so angry she went to her room and smashed the mirror on her closet door. A digit-span test reveals Maria has impairment of her working memory, as she cannot recall and repeat back 4-digit sequences of numbers.

Jeff

Jeff is a 57-year-old male who recently retired after a career as a security guard. He was brought into the ER by a friend who became concerned after Jeff fell when the two of them were working together in Jeff's garage. Initial examination reveals some significant bruising on the patient's arm and torso from the fall.

Upon questioning, Jeff revealed that he had fallen several times during the past few months. He reports a numbness in his right foot and leg, which he attributed to an old work injury that is "just acting up." Simple office tests of pin-prick and pressure sensitivity revealed considerable loss of sensitivity in the foot, even though blood pressure and circulation to the limb appear to be fine.

Because no problems with the limb were identified that could explain the numbness, an MRI was ordered. It revealed the following:

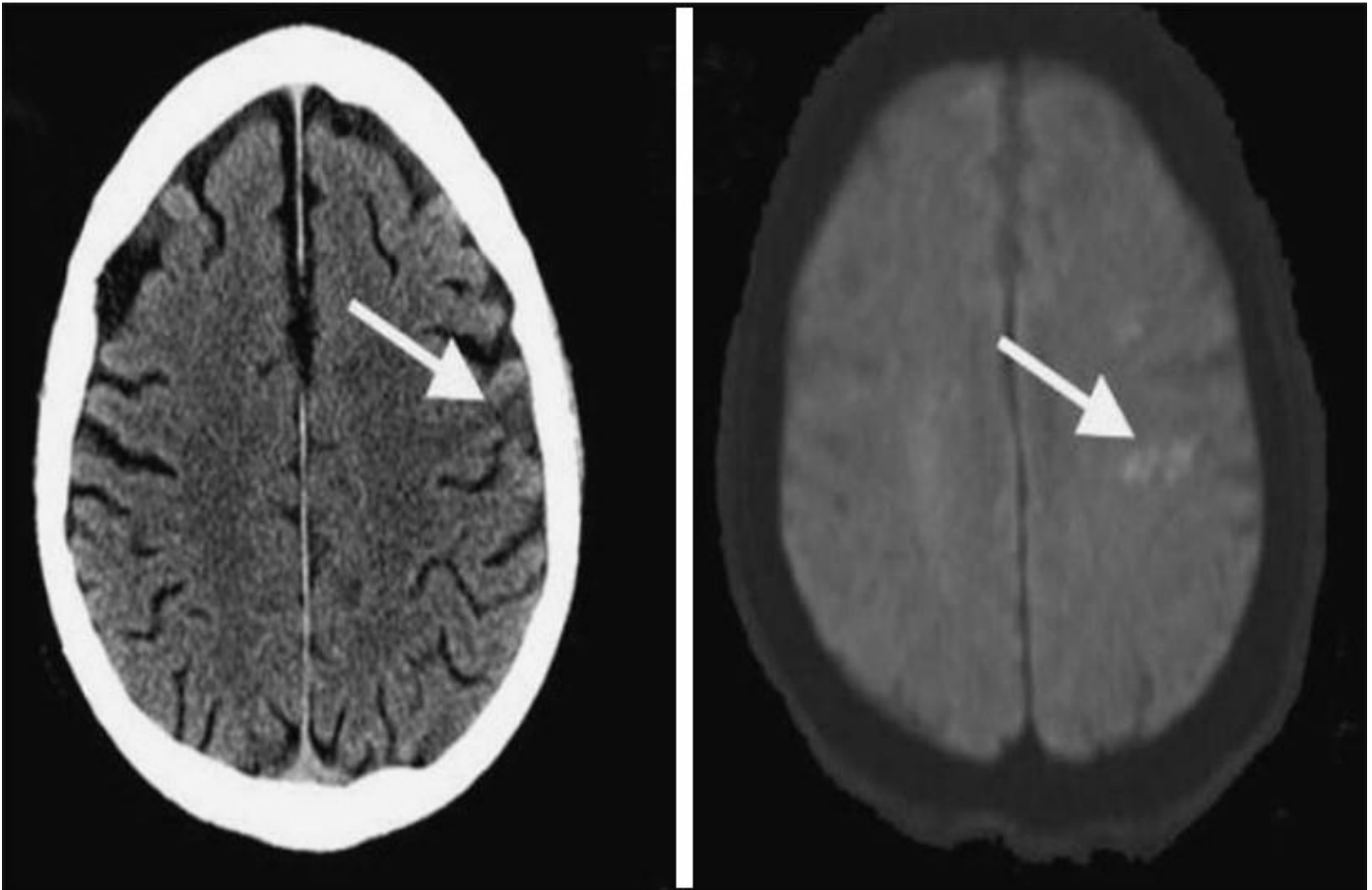


Note: You are viewing the image as if you are standing at the patient's feet. Thus, "right" and "left" as you view them are the opposite for the patient.

Ron

Ron is a 67-year-old married male who was brought to the ER by his wife, who was concerned about the sudden appearance of some concerning symptoms. Ron is a heavy smoker and has a history of high blood pressure.

Earlier in the evening, Ron complained of weakness in his right arm. His wife insisted that he go to the hospital when he started slurring his speech. As you examine him, he can nod and shake his head to answer questions and appears to understand what you are saying, but his speech is unintelligible. The weakness in his right arm has progressed to a full inability to raise that limb. He nods, however, when you ask if he can feel pressure when you squeeze his right hand. A CT scan reveals the following:

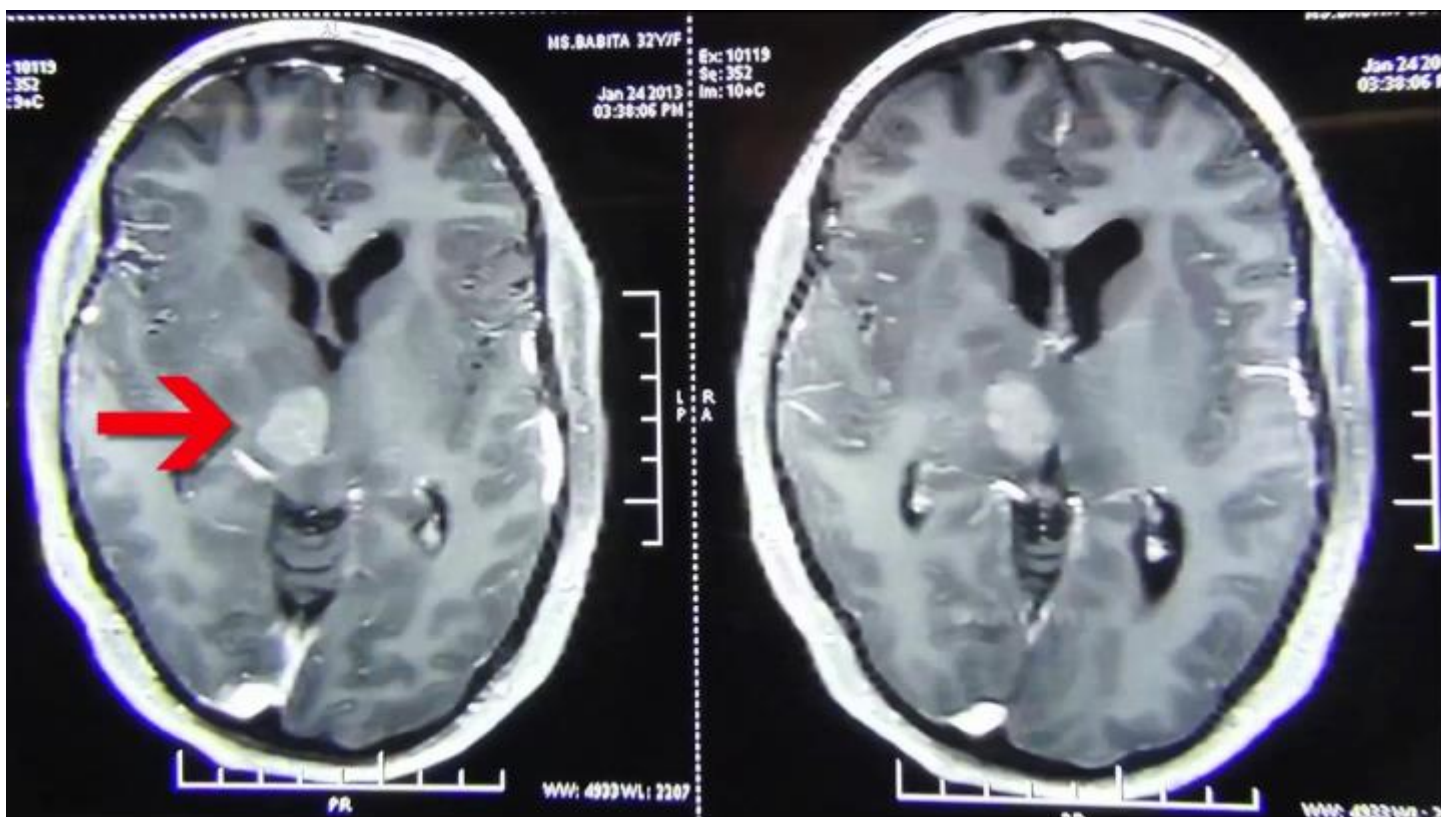


A note on reading CT scans: You are looking “up” at Ron’s brain (imagine you are at his feet). So, left and right (for him) are reverse of your view of left and right.

Betty is a 16-year-old female who has been experiencing a number of troubling symptoms. She had been feeling a good deal of fatigue lately, and recently began to experience strange sensory problems. Sometimes she would experience black spots and flashes of light in her vision. She also has been experiencing some weakness and tingling on the left side of her body.

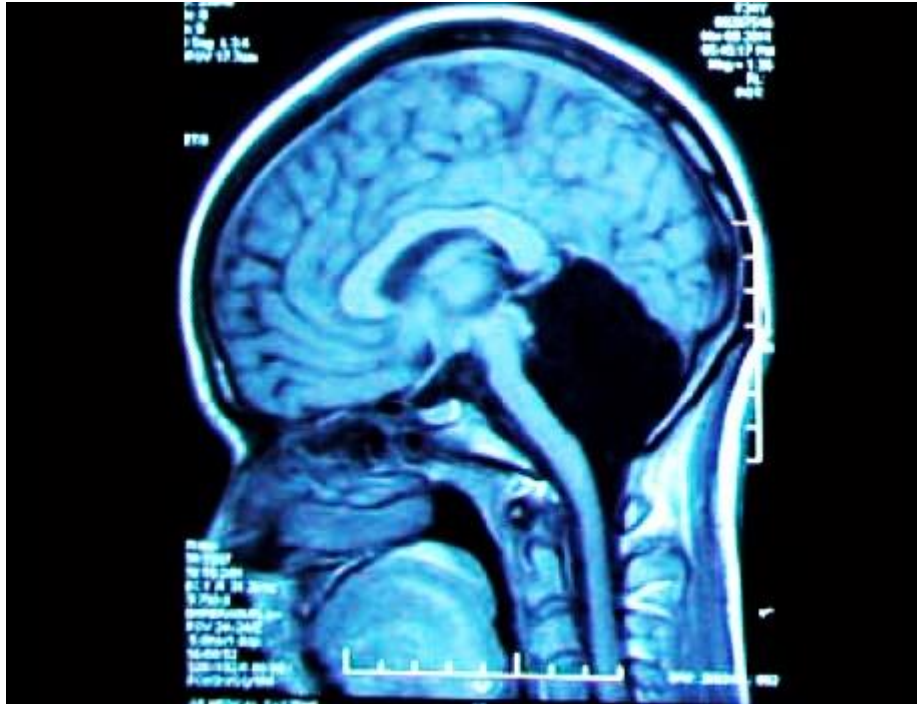
She was brought to the ER by her mother this evening, because Betty recently began to experience severe headaches and vomiting. Betty now reports disturbances in her auditory perception as well, sometimes hearing sounds that others seem not to notice.

Concerned about these sensory symptoms, you order an MRI. It reveals a growth deep in the center of her brain.



Julia

Julia is a 24-year-old woman who appeared for a non-emergency appointment with her primary care physician. She was concerned about frequent dizziness, so a series of brain scans was conducted to investigate possible sources of the problem. The CT scan below indicates what these images uncovered.



Further exploration into Julia's health history revealed that she had begun walking very late, at age 7. She has a mild intellectual impairment, but she is married and has a daughter, demonstrates normal word comprehension, and was "fully oriented" at the time of the exam (meaning, she had a normal sense of time and place).

Henry was brought to the ER via ambulance. His wife of many years described him as an intelligent businessman who headed his own company. At 52 years old, he was generally healthy and exercised regularly. However, several hours before the ER visit he reported feelings of numbness in his right hand, which soon progressed into an inability to move his entire right arm.

At present, his communication also seems to be impaired. When asked to describe an image like the one pictured below, he responded:

“First of all this is falling down, just about, and is gonna fall down and they’re both getting something to eat...but the trouble is this is gonna let go and they’re both gonna fall down...And so this is falling down and for sure there’s one they’re going to have for food and, and this didn’t come out right, the, uh, the stuff that’s uh, good for, it’s not good for you but it, but you love, um mum mum [Henry intentionally smacks lips]...and so they’ve ...see that.”

