


---

---

---

---

---

---

---

---

**Learning Objectives**

- At the completion of this educational activity, the learner will be able to:
  - Define the various acute cardiac ischemic syndromes
  - Sequence priorities of principal diagnosis in persons admitted for acute cardiac syndromes
  - Recognize the potential of documentation gaps between CDI and the providers regarding the meaning of clinical terms and the ICD-10-CM disease classification system
  - Apply lessons learned to common clinical scenarios

---

---

---


---

---

---

---

---




---

---

---

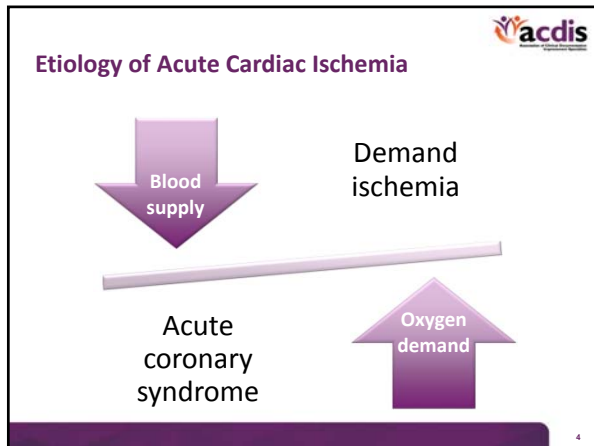
---

---

---

---

---




---

---

---

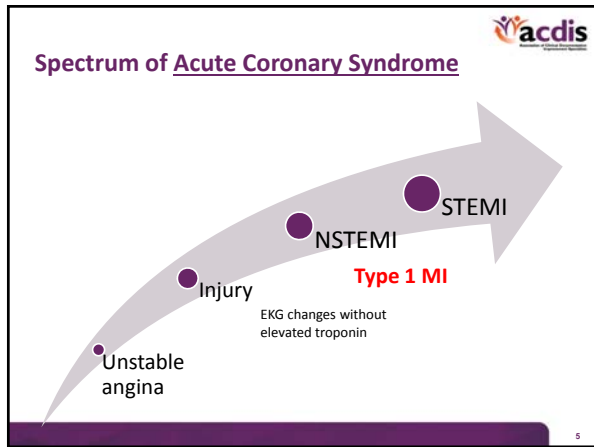
---

---

---

---

---




---

---

---

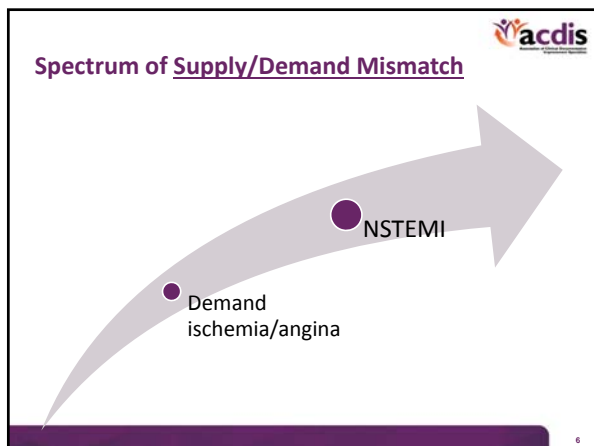
---

---

---

---

---




---

---

---


---

---

---

---

---



**Definition of Myocardial Infarction**

*Circulation. 2012; 126:2020-2035*

---

---

---


---

---

---

---

---



**Clinical Definition of Acute MI**

**“Cardiac biomarkers (troponin)”\*\***

**AND**

**Symptoms**

**OR**

**New EKG findings**

**OR**

**Imaging studies**

\*\* Biomarkers not required in defining AMI in setting of sudden cardiac death (Type 3)

---

---

---


---

---

---

---

---



**Clinical Definition of Acute MI**

<p><b>Cardiac biomarkers</b></p> <ul style="list-style-type: none"> <li>• Detection of rise and/or fall in biomarkers (preferably, troponin) with at least one value outside the normal range</li> <li>• The degree of change will be determined by the setting in which the AMI occurred</li> <li>• AMI associated with sudden cardiac death (type 3) can be made without biomarker determination</li> </ul>	<p><b>Symptoms</b></p> <ul style="list-style-type: none"> <li>• Angina types of pain (arm, jaw)</li> <li>• Angina equivalents (SOB, fatigue)</li> <li>• Syncope</li> <li>• Flash pulmonary edema</li> <li>• Cardiac arrest</li> </ul>
---	---

---

---

---


---

---

---

---

---



### Clinical Definition of Acute MI

<p><b>New EKG changes</b></p> <ul style="list-style-type: none"> <li>• STEMI</li> <li>• NSTEMI</li> <li>• New LBBB</li> <li>• Pathological Q waves</li> </ul>	<p><b>Imaging/autopsy</b></p> <ul style="list-style-type: none"> <li>• Scans (technetium, thallium) showing new loss of viable myocardium (not scar)</li> <li>• New regional wall abnormality of ventricle</li> <li>• Identification of coronary thrombus on catheterization or at autopsy</li> <li>• Identify a PCI complication (i.e., dissection)</li> </ul>
---	---

10

---

---

---


---

---

---

---

---



### Types of Myocardial Infarction

- 1 • Acute primary coronary artery event with acute luminal compromise (plaque rupture and thrombosis).
- 2 • Supply/demand mismatch; typically NSTEMI.
- 3 • Associated with sudden death without biomarkers. Based on EKG changes and presence of ischemic symptoms only.

11

---

---

---


---

---

---

---

---



### Types of Myocardial Infarction

- 4a • PCI-related AMI; troponin elevation must exceed 5x above normal range.
- 4b • Due to stent thrombosis; stent thrombosis must be seen by angiography or autopsy.
- 5 • CABG related; at least one troponin has to be 10x above normal range; LBBB or Q waves or new occlusion of native vessel or graft.

12

---

---

---

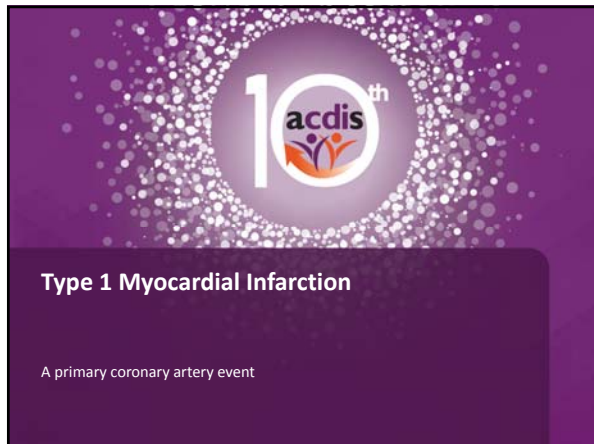---

---

---

---

---



---

---

---


---

---

---

---

---

**Type 1 MI: NSTEMI** 

- Non-ST elevation myocardial infarction (NSTEMI):
  - Myocardial infarction due to plaque rupture and subsequent coronary thrombosis
  - Subtotal occlusion leads to unstable ischemic symptoms and ECG changes (ST depression and T-wave inversions)
  - Distinguished from unstable angina by the presence of elevated cardiac biomarkers (CK, troponin, CKMB)

14

---

---

---


---

---

---

---

---

**Type 1 MI: NSTEMI** 

- Patients with NSTEMI due to ACS are treated with standard ACS therapy and taken for urgent left heart catheterization with 48 hours
- Left heart catheterization often shows severe stenosis or subtotal occlusion in one or more major branches
- This may be fixed with PCI or CABG
- Occasionally, a culprit vessel is not discovered and the patient is treated medically

15

---

---

---


---

---


---

---

---



**Type 1 MI: NSTEMI**



16

---

---

---


---

---


---

---

---



**Type 1 MI: NSTEMI**



17

---

---

---


---

---

---

---

---



**Type 1 MI: STEMI**

- ST-elevation myocardial infarction (STEMI)
  - Plaque rupture resulting in vessel occlusion
  - Cardiac biomarkers are elevated, usually significantly higher than they are for NSTEMI
  - Distinguished from NSTEMI by the presence of ST elevation on the ECG
  - Requires emergent revascularization, classically with PCI, though if PCI not available within 2 hours then patients may receive thrombolysis
  - Emergent CABG is exceedingly rare

18

---

---

---

---

---

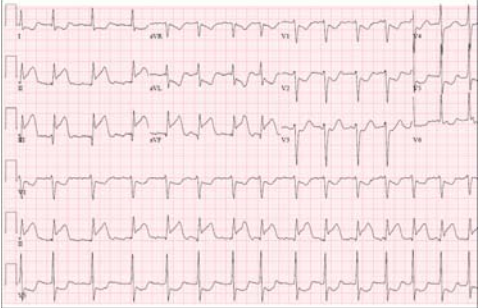
---

---

---

**acdis**

**Type 1 MI: STEMI**



19

---

---

---

---

---


---

---

---

**acdis**

**Type 1 MI: STEMI**



20

---

---

---

---

---

---

---

---



**10<sup>th</sup> acdis**

**Type 2 Myocardial Infarction**

Supply vs. demand

---

---

---


---

---

---

---

---



### Causes of Supply-Demand Mismatch

- Hypotension
  - Bleeding
  - Sepsis
- Tachycardia
  - Afib
  - SVT
- Hypoxia
  - COPD
  - Pneumonia
- Ventricular strain
  - CHF
  - Hypertension
  - Valvular heart disease
  - Pulmonary embolism (right ventricle)

22

---

---

---


---

---

---

---

---



### Type 2 Myocardial Infarction

- Type 2 MIs are NSTEMI types.
- Patients are often not being treated with usual ACS medications such as heparin or lovenox.
- Heart catheterization is not routinely performed. If performed, it is usually not urgent and may not show significant coronary disease.

23

---

---

---


---

---

---

---

---



### Takotsubo Cardiomyopathy

- “Stress-induced cardiomyopathy” or “broken heart syndrome”
- There is controversy regarding the cause, but most believe it is due to catecholamine surge causing microvascular ischemia/infarction
- Usually initiated by physical, emotional, and mental stress
- Has also been linked to certain medications: SNRI

24

---

---

---

---

---

---

---

---



**Takotsubo Cardiomyopathy**

- Patients present with symptoms suggesting ACS
- ECG may show ST elevation or depression
- Cardiac biomarkers are usually elevated
- Left heart catheterization shows normal coronary arteries
- Left ventriculogram typically shows apical ballooning, though other patterns can exist

25

---

---

---

---


---

---

---

---

**Takotsubo Cardiomyopathy**



26

---

---

---

---

---

---

---

---

**10<sup>th</sup> acdis**

**Acute Cardiac Ischemic Syndromes**

Impact of documentation on outcomes

---

---

---


---

---

---

---

---



### Diagnosis Specification Impact

	AMI (disch. alive)	Ischemia w/o MI		Stent/graft complication
		Demand	ACS/USA	
W/O cath DRGs	280-282	311	311	314-316 or 280-282
W cath DRGs	280-282	286-287	286-287	286-287 or 280-282
ODx	MCC	CC	CC	CC
30-day AMI mortality readmission	Yes			No
Episode AMI payment	Yes			Yes, if AMI is an ODX
HCC	186	187	187	NA

28

---

---

---

---

---

---

---


---

---

---

---

---

- 
- ### Documentation Points
- **Define** the acute ischemic syndrome and its POA status (don't forget 4 weeks for AMI).
  - What is the **etiology** of the acute ischemic syndrome?
  - When or where was any invasive cardiovascular **procedure** performed?
- 29

---

---

---

---

---

---

---


---

---

---

---

---



### Define Acute Ischemic Syndrome

<p><b>Ischemia w/o infarction</b></p> <p>Unstable angina (USA)</p> <ul style="list-style-type: none"> <li>- Crescendo/accelerated/worsening</li> <li>- Pre-infarction</li> <li>- New onset (de novo)</li> <li>- Intermediate coronary syndrome</li> </ul> <p>Acute coronary syndrome**</p> <p>Demand ischemia**</p>	<p><b>Ischemia with infarction</b></p> <p>NSTEMI</p> <ul style="list-style-type: none"> <li>- Subendocardial</li> <li>- Non-Q wave</li> <li>- Non-transmural</li> </ul> <p>STEMI</p> <ul style="list-style-type: none"> <li>- Q wave</li> <li>- Transmural</li> </ul> <p><b>Acute MI</b> is used for first 4 weeks</p> <p><b>Subsequent MI</b> is a new acute MI within the 4-week period</p>
---	---

30

---

---

---

---

---

---

---


---

---

---

---

---



### Etiology of Occlusive Ischemic Syndromes

- Unstable angina
- Acute coronary syndrome
- All acute MI types except Type 2

**\*\*\* End-stent stenosis** has to be clarified with physician if stenosis is within the stent or in the native vessel

**Coronary artery disease**

- Progression of coronary artery disease in native artery or bypass grafts
- Acute thrombus in native artery

**Complication of graft/stent**

- Acute thrombus
- In-stent restenosis\*\*\*
- Occlusion or stenosis of unspecified etiology

31

---

---

---

---

---


---

---

---

---

---



### Sequencing of Acute MI as PDx

**Use acute MI as PDx if:**

- Cause unspecified
- Due to clot or thrombus in a native artery
- Due to native coronary artery disease or occlusion of coronary graft by progression of CAD

32

---

---

---

---

---


---

---

---

---

---



### Sequencing of Acute MI as PDx

**Use acute MI as ODx if:**

- Due to thrombus within a coronary graft
- Due to thrombus of a stent
- Due to fibrodysplasia of graft or stent (not atherosclerosis)
- Due to graft or in-stent stenosis of undetermined cause

**Use the complication code as the PDx and list the acute MI as an ODx, which could possibly act as an MCC, if an intervention is performed.**

33

---

---

---

---

---


---

---

---

---

---



**Case #1**

- 76 BF presented with chest pain and SOB. EKG showed ST depression and chest x-ray revealed pulmonary edema. There was a rise in troponins. Patient received multiple doses of IV Lasix. Cardiac cath revealed no coronary disease and normal EF. Patient was discharged on carvedilol and lisinopril. Patient was diagnosed as acute HFpEF and demand ischemia.
- Option 1:
  - Ac. NSTEMI – PDx (query)
  - Acute diastolic HF – ODx 1
  - MS-DRG 280
  - Patient would be in cohort for AMI for 30-day mortality/readmission
  - Payment bundle AMI
- Option 2:
  - Acute diastolic HF – PDx
  - Ac. NSTEMI MI – ODx 1
  - MS-DRG 282
  - Cohort for 30-day mortality and readmission for CHF
  - Payment bundle for AMI

34

---

---

---

---

---


---

---

---

---

---



**Case #2**

- Patient presents with acute onset of chest pain and transient elevation of troponin. EKG demonstrated ST elevation across anterior leads. Heart catheterization revealed a 90% in-stent restenosis (“ISR”) of LAD and a 95% occlusion of the native circumflex. Both lesions were dilated and DES placed. Patient was discharged on Plavix, aspirin, carvedilol, and atorvastatin.
- Option 1:
  - Ac. STEMI – PDx (query)
  - MS-DRG 247
  - Patient would be in cohort for AMI for 30-day mortality/readmission
  - Payment bundle AMI
- Option 2:
  - In-stent restenosis – PDx
  - Ac. STEMI MI – ODx 1
  - MS-DRG 246
  - Payment bundle for AMI

35

---

---

---

---

---


---

---

---

---

---



**Case #3**

- Patient presents in atrial fibrillation with rapid ventricular response (HR 180) associated with chest pressure and SOB. The EKG revealed some atrial fibrillation with inverted T waves but no ST elevation. Troponins remained normal. Patient was treated with IV cardizem and returned to sinus rhythm. Patient had a EKG with scan done, revealing no ischemia. Patient was discharged on oral amiodarone and carvedilol. Final diagnosis was new-onset atrial fibrillation and demand ischemia.
- Option 1:
  - Atrial fibrillation – PDx
  - Demand ischemia – ODx 1
  - MS-DRG 309
- Option 2:
  - Demand ischemia – PDx
  - Ac. atrial fibrillation – ODx 1
  - MS-DRG 311

36

---

---

---

---

---


---

---

---

---

---



**Case #4**

- A 56 female patient presents very SOB and with severe chest pain following an argument with her spouse. EKG showed T-wave inversion without ST elevation; Chest x-ray demonstrated pulmonary edema; troponins show a significant rise; cardiac catheterization showed apical ballooning and normal coronary arteries. Patient was treated with IV Lasix and placed on beta blockers. Final diagnosis was Takotsubo syndrome with acute systolic heart failure transient and acute type 2 MI.
- What should be the principal diagnosis?

- Option 1:
  - Takotsubo syndrome – PDx
  - Ac. systolic HF – ODx 1
  - MS-DRG 286
- Option 2:
  - Ac. systolic CHF – PDx
  - Takotsubo syndrome – ODx 1
  - MS-DRG 287
- Option 3: ?????
  - Acute type 2 MI – PDx
  - Takotsubo syndrome – ODx 1
  - Ac. systolic HF – ODx 2
  - MS-DRG 280

37

---

---

---

---

---

---

---


---

---

---

---

---



**Thank you. Questions?**

*Garry.Huff@Enjoincdi.com*

In order to receive your continuing education certificate(s) for this program, you must complete the online evaluation. The link can be found in the continuing education section at the front of the program guide.

---

---

---

---

---

---

---

---

---

---

---

---