



## Review

## Diffusion tensor imaging in attention deficit/hyperactivity disorder: A systematic review and meta-analysis

Hanneke van Ewijk<sup>a,\*</sup>, Dirk J. Heslenfeld<sup>a,b</sup>, Marcel P. Zwiers<sup>c</sup>, Jan K. Buitelaar<sup>c,d</sup>, Jaap Oosterlaan<sup>a</sup>

<sup>a</sup> Department of Clinical Neuropsychology, VU University Amsterdam, The Netherlands

<sup>b</sup> Department of Cognitive Psychology, VU University Amsterdam, The Netherlands

<sup>c</sup> Department of Cognitive Neuroscience, Donders Institute for Brain, Cognition and Behavior, Radboud University Nijmegen Medical Center, Nijmegen, The Netherlands

<sup>d</sup> Karakter, Child and Adolescent Psychiatry University Center Nijmegen, Nijmegen, The Netherlands

## ARTICLE INFO

## Article history:

Received 23 November 2011

Received in revised form 11 January 2012

Accepted 17 January 2012

## Keywords:

ADHD

DTI

DWI

White matter

Structural connectivity

Anisotropy

Mean Diffusivity

ALE

GingerALE

## ABSTRACT

Diffusion tensor imaging (DTI) allows in vivo examination of the microstructural integrity of white matter brain tissue. A systematic review and quantitative meta-analysis using GingerALE were undertaken to compare current DTI findings in patients with ADHD and healthy controls to further unravel the neurobiological underpinnings of the disorder. Online databases were searched for DTI studies comparing white matter integrity between ADHD patients and healthy controls. Fifteen studies met inclusion criteria. Alterations in white matter integrity were found in widespread areas, most consistently so in the right anterior corona radiata, right forceps minor, bilateral internal capsule, and left cerebellum, areas previously implicated in the pathophysiology of the disorder. Current literature is critically discussed in terms of its important methodological limitations and challenges, and guidelines for future DTI research are provided. While more research is needed, DTI proves to be a promising technique, providing new prospects and challenges for future research into the pathophysiology of ADHD.

© 2012 Elsevier Ltd. All rights reserved.

## Contents

1. Introduction.....	1094
2. Methods.....	1095
2.1. Study selection.....	1095
2.2. Narrative review.....	1095
2.3. Meta-analysis: activation likelihood estimation.....	1096
3. Results.....	1096
3.1. Narrative review.....	1096
3.1.1. ROI studies.....	1096
3.1.2. VBA studies.....	1100
3.1.3. Associations with behavioural and cognitive measures.....	1101
3.2. ALE meta-analysis.....	1101
4. Discussion.....	1102
4.1. Summary.....	1102
4.2. Limitations of current literature.....	1103
4.3. The future of DTI research in ADHD.....	1104
4.4. Conclusion.....	1104
References.....	1105

\* Corresponding author at: VU University Amsterdam, Faculty of Psychology and Education, Department of Clinical Neuropsychology, van der Boechorststraat 1, 1081 BT Amsterdam, The Netherlands. Tel.: +31 020 587 8770; fax: +31 020 598 8971.

E-mail address: [h.van.ewijk@psy.vu.nl](mailto:h.van.ewijk@psy.vu.nl) (H. van Ewijk).

## 1. Introduction

Attention deficit hyperactivity disorder (ADHD) is the most common childhood psychiatric disorder, affecting 5.3% of school-age children and 4.4% of adults worldwide (Biederman et al., 2000; Kessler et al., 2006). Up to 80% of the variance in the clinical phenotype might be explained by heritable factors (Albayrak et al., 2008; Poelmans et al., 2011). Apart from behavioural symptoms, patients also show a variety of deficits in executive functions such as response inhibition and working memory, and in motivational functions including the ability to deal with delay and sensitivity to reward (Krain and Castellanos, 2006). Although the exact aetiology and neurobiological substrate of ADHD remain unclear, converging evidence suggests that abnormalities in brain structure as well as functioning might play an important role in the pathophysiology of the disorder. Amongst many theories regarding the neurobiological basis of ADHD, the prevailing hypothesis identifies the fronto-striatal-cerebellar neurocircuitry as a probable underlying substrate of the cognitive and behavioural problems observed in the disorder (Bush et al., 2005; Durston and Konrad, 2007; Makris et al., 2009).

Over the past few decades, the use of magnetic resonance imaging (MRI) has proven to be a useful tool in ADHD research, providing high-resolution in vivo images of the brain. Structural MRI (sMRI) has frequently been used to compare brain volumes of ADHD patients and healthy controls. Such volumetric studies have consistently shown an overall reduction in total cerebral volume of about 3–8% with medium effect sizes ( $.30 < d < .64$ ) in children as well as adults with ADHD, particularly in the right hemisphere (Castellanos et al., 2002; Krain and Castellanos, 2006; Mostofsky et al., 2002; Seidman et al., 2005). Findings regarding more specific lobar or regional volume reductions have so far been inconsistent for the temporal and parietal lobe (Castellanos et al., 2002; Filipek et al., 1997; Sowell et al., 2003), whereas occipital and frontal lobe volumes have more consistently been reported to be smaller in ADHD patients (Castellanos and Acosta, 2004; Castellanos et al., 2002; Durston et al., 2004; Kates et al., 2002; Seidman et al., 2005, 2006; Sowell et al., 2003). Studies into cortical thickness have also found striking differences between ADHD patients and healthy controls. (Batty et al., 2010; Makris et al., 2007; Narr et al., 2009; Shaw et al., 2006, 2007, 2009). However, negative findings exist (Wolosin et al., 2009) and differences in scanning and analysis procedures make it difficult to draw robust conclusions.

While most sMRI studies focus on cortical grey matter (GM) or specific subcortical structures, the role of white matter (WM) is still underexplored. The few studies that investigated WM volume in patients with ADHD have consistently reported an overall reduction of total cerebral WM as well as mostly bilateral reductions in all four lobes (Castellanos et al., 2002; Filipek et al., 1997; Kates et al., 2002; McAlonan et al., 2007; Mostofsky et al., 2002). Interestingly, effect sizes for volume reductions in total brain as well as lobar volumes seem to be larger in WM than GM, with GM effect sizes between .27 and .35, and WM effect sizes ranging from .30 to .64 (Castellanos et al., 2002), implicating an important role of WM deficits in the pathophysiology of ADHD. After more specific subparcellation of the brain, most WM volume reductions appear to localize to the inferior longitudinal fasciculi (connecting the temporal lobe with the cerebellum) and occipitofrontal fasciculi (connecting frontal and occipital lobes) (McAlonan et al., 2007). Volume reductions in specific WM structures such as the corpus callosum and the cerebellum have also been implicated in the pathophysiology of the disorder, suggesting that WM abnormalities might, at least partly, underlie the disturbed connectivity in the fronto-striatal-cerebellar neurocircuitry in ADHD patients (Castellanos et al., 2002; Durston et al., 2004; Hill et al., 2003; Hynd et al., 1991; Seidman et al., 2005; Valera et al., 2007). Interestingly,

Durston et al. (2004) reported volume reductions in left occipital WM not only in children with ADHD, but also in their unaffected siblings, suggesting that these abnormalities might be related to an increased familial risk for the disorder. A differential effect was demonstrated in right cerebellar volume, which was found to be reduced in children with ADHD, but not in their unaffected siblings, suggesting that cerebellar volume reduction may be more directly related to the pathophysiology of the disorder. This hypothesis is further supported by the apparent relationship between cerebellar volume and ADHD symptomatology; patients with a worse clinical outcome have shown a relative developmental volume loss as compared to control subjects and ADHD patients with better clinical outcome (Mackie et al., 2007). It should be noted, however, that the relationship between WM volume and WM pathology is poorly established (Canu et al., 2010; Fjell et al., 2008; Hugenschmidt et al., 2008), and that these volumetric differences may well be caused by pathological processes in GM.

During recent years, the focus of neuroimaging research into ADHD has shifted towards a connectivity approach, studying functional and structural connections between brain regions, rather than focusing on regional deficits. In this approach, the perspective on the pathophysiology of ADHD shifts from local functional and structural deficits to dysfunctions of distributed network organization. Functional connectivity studies that investigate interactions between different brain regions during a cognitive task are so far limited in ADHD research. The few studies available show fairly heterogeneous results, but generally implicate a variety of alterations in ADHD, including decreased fronto-parietal connectivity, consistent with a delay of maturation in children with ADHD (Konrad and Eickhoff, 2010; Liston et al., 2011). Resting state studies focus on the Default Mode Network (DMN), comprised of midline structures including the posterior cingulate cortex and ventromedial prefrontal cortex, typically active during introspective, task-free processes. Studies investigating the DMN in ADHD generally implicate reduced functional connectivity between these structures in ADHD patients, as well as a weaker than normal correlation with the anterior cingulate cortex, consistent with a failure to suppress DMN activity during tasks requiring cognitive control (Fair et al., 2010; Konrad and Eickhoff, 2010; Liston et al., 2011).

In studying structural connectivity in the brain, i.e. examining white matter tracts connecting cortical brain regions and subcortical structures, diffusion tensor imaging (DTI) plays an important role. DTI has been found to be a very valuable tool for providing specific indices of neuropathology (Alexander et al., 2007), and is increasingly being used in studying the neurobiology of psychiatric disorders. Over the past decade, the use of DTI has emerged quickly in ADHD research, allowing examination of the integrity of WM tracts in vivo at a microstructural level. DTI is an MRI technique, in which the local diffusion coefficient of water is modelled as a function of direction using a so-called self-diffusion tensor (Basser et al., 1994). This means that the probability distribution of diffusing water molecules follows a multivariate (3D) Gaussian distribution. The key element of DTI is that this distribution (i.e. its size and the orientation of the main directions) is determined by the microscopic hindrances and restrictions that the water molecules experience when diffusing through tissue. Thus by fitting the diffusion tensor model to the MRI data, DTI can provide a quantitative estimate of the displacement and direction of diffusion of water molecules for every voxel in the brain. In pure water or grey matter, the diffusion coefficient will be the same in every direction (isotropic), but in white matter this coefficient can be different for different directions (anisotropic), i.e. much larger along the direction of axon bundles than perpendicular to it.

One commonly used DTI measure is Mean Diffusivity (MD), which is the first order statistic (mean) of the diffusion coefficients over the tensor's main directions. The MD can give immediate

information on changes in the interstitial space (i.e. the empty space between brain structures), such as following an ischemic accident (Mintorovitch et al., 1991; Moseley et al., 1990) or inflammation (Tievsky et al., 1999). A second commonly reported measure is the fractional anisotropy (FA), which is the second order statistic of the diffusion coefficients over these same directions. FA values can range from 0 in regions with free diffusion (fully isotropic), to 1 (fully anisotropic) in regions with strongly restricted movement direction, such as within myelinated axons (Alexander et al., 2007; Beaulieu, 2002). A recent study showed, by correlating DTI parameters with histology measures of the fimbria-fornix in epilepsy patients, that FA strongly correlated with cumulative axonal membrane circumference ( $r = .71$ ), and less strongly with axonal density and myelin thickness ( $r = .5$  and  $r = -.5$ , respectively, which did not remain significant after correction for multiple comparisons) (Concha et al., 2010). While greater axonal integrity and organization is commonly thought to be reflected by higher FA due to greater directional coherence of diffusion, interpretation of FA remains somewhat ambiguous as it also depends on other factors, most notably the presence of subvoxel fibre crossings and axonal density in the regions examined. While FA is generally found to decrease in regions of crossing fibre tracts (due to the greater directionality of water molecule movement), in a single fibre bundle, decreased FA might represent less restricted movement due to deficient axonal integrity or myelination. Taken together, MD and FA provide measures of the direction and extent of diffusion of water in the brain, indicative of the organization and orientation of WM tracts and myelination.

A different pair of DTI measures is set out by decomposing the diffusion coefficients into a component in the axon's principal diffusion direction (the main axis with the largest diffusion coefficient) and a component averaged over the perpendicular directions. These are respectively referred to as axial and radial diffusivity and may provide more specific insight into the neurobiological nature of axonal abnormalities (assuming linear anisotropy; see Ennis and Kindlmann, 2006), thus benefiting more accurate interpretation of DTI findings (Alexander et al., 2007). For instance, a reduction in FA could be due to a reduction in axial diffusivity or an increase in radial diffusivity, or a combination of both. While decreases in axial diffusivity are thought to be indicative of axonal damage or degeneration, increases in radial diffusivity with minimal changes in axial diffusivity are thought to result from increased freedom of cross-fibre diffusion and thus are likely to represent decreased myelination (Alexander et al., 2007; Song et al., 2002). Decreases in radial diffusivity are mostly observed in areas with a lower degree of neuronal branching (Suzuki et al., 2003). Another, less frequently used measure is the *mode of anisotropy*, as proposed by Ennis and Kindlmann (Douaud et al., 2011; Ennis and Kindlmann, 2006). Using the ratio between diffusivity in the principal and perpendicular directions, the mode of anisotropy provides a continuous measure of the shape of the tensor, indicating either a relatively large contribution of the tensor in the principal direction (leading to a linear shape of the tensor, representing regions in which one fibre bundle predominates,  $\text{mode} = 1$ ) or a relatively large contribution of the perpendicular directions (planar shape, representing regions with crossing fibres, or 'kissing fibres',  $\text{mode} = -1$ ). Consequently, this measure can provide us with important clues regarding how to interpret the anisotropy measures, in terms of the underlying anatomy.

In the investigation of these DTI measures, two main analysis methods can be employed: voxel-based analysis (VBA) and region-of-interest analysis (ROI). While ROI analyses allow a powerful examination of specific areas based on existing hypotheses, these analyses are limited in their scope of exploring abnormalities throughout the whole brain. Comparability among ROI studies can be limited, since choice and placement of ROIs are subjective.

Factors like the atlas choice and whether the ROI is drawn on individual or group average maps (possibly leading to differential partial volume effects) contribute to heterogeneity among ROI studies and thus limit the comparability of results between studies. Moreover, ROI analyses average signal intensities across a cluster of voxels, discarding all information on complex patterns that may be present within the cluster. In cases where the expected abnormalities are diffuse rather than localized, or in cases where there are no hypotheses about specific brain regions, VBA is a useful exploratory alternative. VBA allows for whole-brain analysis, thus providing a complete overview of white matter integrity in the brain. However, VBA results do depend on selection of the template space and the choice and quality of normalisation and interpolation techniques (Bookstein, 2001; Sage et al., 2009; Van Hecke et al., 2011; Zhang et al., 2007). In addition, VBA group comparisons may be affected by small, residual differences in local anatomy between groups, and they need correction for multiple statistical comparisons. Due to these factors, combined with the limited reference to underlying anatomical properties (e.g. neuronal branching or crossing and 'kissing fibres', Douaud et al., 2011), VBA results can be difficult to interpret or to compare between studies.

Altogether, given the abnormalities in WM volume in patients with ADHD, together with the sensitivity of DTI to detect subtle changes in WM integrity, DTI can provide us with a useful technique to investigate the integrity of white matter tracts at the microstructural level, and shed new light on the pathophysiology of brain WM in these patients. However, pertinent studies published so far are greatly heterogeneous in terms of sample characteristics, analysis techniques and processing parameters. The aim of the present paper is to systematically review DTI studies of ADHD patients and to provide a more comprehensive account of WM abnormalities in ADHD. By adding a quantitative MRI meta-analysis using GingerALE (Eickhoff et al., 2009; Laird et al., 2005), we aimed to identify regions that were most robustly found to demonstrate abnormal WM integrity in ADHD patients across studies.

## 2. Methods

### 2.1. Study selection

This review included all empirical studies that met the following inclusion and exclusion criteria. Studies *included* had to: (1) Report on comparisons between ADHD patients and healthy control subjects concerning measures of diffusion weighted imaging of brain white matter; (2) Be published before June 2011 in peer-reviewed English language journals; (3) Include a group of ADHD patients, in which ADHD was the primary focus of investigation, and a group of healthy controls; (4) Studies, or analyses within studies, in which participants were explicitly recruited to have multiple combined Axis I diagnoses were *excluded*.

Online searches were performed in the databases EMBASE, PubMed, PsychInfo, and Web Of Science, using the search terms ADHD, MRI, diffusion weighted imaging (DWI), diffusion tensor imaging (DTI), white matter, diffusion, tensor, (fractional) anisotropy, and equivalent terms. References of all selected articles were checked for further papers suitable for inclusion. Fifteen articles were retrieved that met our inclusion and exclusion criteria and were then systematically reviewed.

### 2.2. Narrative review

Results of the reviewed studies will be discussed in three sections. First, results will be discussed of studies that investigated specific ROIs based on prior hypotheses. Subsequently, we will discuss the results of VBA studies, investigating the full brain. Finally, a

short overview will be provided of associations between DTI measures and functional outcomes in terms of ADHD symptomatology and neurocognitive functions in the reviewed studies.

### 2.3. Meta-analysis: activation likelihood estimation

In order to analyse and visualise concurrence in reported clusters of abnormal FA across studies, an *activation likelihood estimation* (ALE) meta-analysis was carried out using the Brainmap GingerALE software package (Eickhoff et al., 2009; Laird et al., 2005). The coordinates of the reported voxels of each study are treated as a probability distribution, creating an ALE distribution map (Turkeltaub et al., 2002). The ALE map is then subjected to Gaussian smoothing and each voxel is tested against a null distribution map. In the revised algorithm used in this meta-analysis (GingerALE), the width of the Gaussian smoothing kernel is determined for each study separately by the number of participants, thereby weighting each study by its sample size, and the resulting ALE map is corrected for multiple comparisons.

Suitable for analysis with ALE was a sub selection of VBA studies included in our review, subject to additional inclusion criteria. ROI studies were excluded from the meta-analysis in order to avoid a bias towards the ROIs chosen by the investigators, and because of the lack of information on specific coordinates of peak voxels. Studies included in the meta-analysis had to: (1) Report  $x/y/z$  coordinates for clusters of altered WM; (2) Report  $x/y/z$  coordinates in either Talairach or Montreal Neurological Institute (MNI) space.

Studies included in the meta-analysis are marked with an asterisk in Table 1. FA measures of all included studies were used in the meta-analysis. MD measures were only reported in 3 of the included studies, and were excluded because conducting an ALE meta-analysis on this limited number of studies would lead to unreliable results.

All coordinates originally reported in MNI space were normalised to Talairach space using Lancaster's Transform (Lancaster et al., 2007); coordinates which had already been transformed to Talairach space using Brett's formulation (Brett, 1999) were converted back to MNI coordinates and then transformed into Talairach space using Lancaster's Transform. The resulting ALE map was thresholded at  $p < .05$  using a false discovery rate (FDR) correction for multiple comparisons and a minimum cluster size of 100 mm<sup>3</sup>. The ALE map was overlaid onto a Talairach anatomical template for visualisation purposes.

## 3. Results

### 3.1. Narrative review

Study characteristics and results of reviewed studies are summarized in Table 1.

#### 3.1.1. ROI studies

A total of seven studies investigating specific ROIs have been published. A large heterogeneity was observed in chosen regions and methodology; while 3 studies have focused on specific WM regions (typically delineated manually), others seem to have done exploratory analyses on several main WM tracts throughout the brain. Investigated tracts were typically extracted from a WM anatomical atlas (e.g. Mori et al., 2004; Wakana et al., 2004), and superimposed on either individual or group average FA maps.

Because of the major role of the basal ganglia in the pathophysiology of ADHD, one study chose the *caudate nucleus*, *globus pallidus/putamen*, and the *thalamus* as their regions of interest, and hypothesized that children with ADHD would have abnormal diffusion properties in these areas, particularly in the caudate nucleus, as the centre of fronto-striatal networks (Silk et al., 2009a). The

authors compared FA in the basal ganglia of boys with ADHD combined subtype (ADHD-C) and healthy controls, aged 8–18 years. No significant group differences were found for either FA or MD in any of the ROIs. When looking at developmental trajectories of FA, the authors found an increase with age within the whole-brain volume and the putamen and thalamus ROIs for both groups. However, the caudate nucleus showed different developmental trajectories for ADHD patients and healthy controls. The control group showed the expected increase of FA with age only in the early adolescence group (11–14 years), suggesting that the developmental increase of FA may slow or end during mid to late adolescence. ADHD patients however, showed an increase of FA across the whole age range (up to 18 years), suggesting a steady, but slower development of WM in the caudate nucleus in ADHD patients, catching up to FA levels similar to those of typically developing children during late adolescence. More specific eigenvalue analyses in the caudate nucleus demonstrated that the increase in FA with age in both groups was mainly due to a decrease in radial diffusivity with little change in axial diffusivity, most likely reflecting the development of myelination.

Another specific WM structure that has been investigated based on theoretical grounds is the *cerebellum*, because of its structural disturbances in ADHD, as well as its role in motor control, several cognitive processes, and affective processes (Bechtel et al., 2009). In this study, FA was compared between boys with ADHD and healthy controls, aged 9–14 years. Decreased anisotropy was found for the ADHD group in the right middle cerebellar peduncle, a fibre bundle composed of afferent fibres as part of the corticopontocerebellar tract, connecting the sensory and motor areas of the cortex with the pons and cerebellum. No FA differences were found within the cerebellum.

One study investigated the *corpus callosum*, because of its role in connecting cortical areas disturbed in ADHD (Cao et al., 2010). The authors combined sMRI and DTI to investigate the entire corpus callosum, as well as seven subdivisions, between boys with ADHD and healthy controls, aged 11–16 years. Decreased FA was only observed for ADHD patients in the isthmus, and not in any other subdivision or the entire corpus callosum.

Consistent with these results, another study also failed to find FA differences in the entire corpus callosum between children with ADHD and healthy controls, mean age 12 (Hamilton et al., 2008). This study selected nine large fibre tracts as ROIs: the *corpus callosum*, *cingulum* (a bundle of association fibres passing from the cingulate gyrus to the entorhinal cortex, encircling the corpus callosum), *corticospinal tract*, *fornix* (a fibre bundle between the hippocampus and the mammillary bodies and septal nuclei), *optic radiation* (relaying visual information from the thalamus to the visual cortex), *superior longitudinal fasciculus* (a long bidirectional bundle connecting all four lobes), *uncinate fasciculus* (located between the temporal and orbitofrontal lobes), and the *superior and inferior occipitofrontal fasciculi* (passing backwards from the frontal lobe along the caudate nucleus, radiating into the temporal and occipital lobes). Lower FA was demonstrated for ADHD patients in the corticospinal tract and superior longitudinal fasciculus. Removal of medicated patients did not change the results.

Decreased FA in the superior longitudinal fasciculus is consistent with another study examining the superior longitudinal fasciculus-II; the major component of the superior longitudinal fasciculus, originating in the caudal-inferior parietal cortex and terminating in the dorsolateral prefrontal cortex (Makris et al., 2008). The authors studied WM integrity in adults with childhood-onset ADHD, aged 37–46, and demographically matched healthy controls. All 12 patients were diagnosed with childhood-onset ADHD of any subtype, 5 of whom continued to meet adulthood criteria for the disorder. Selected ROIs were the *superior longitudinal fasciculus-II* and *cingulum*, based on their role in attention and executive functioning, as well as the *fornix*, used as a control ROI. FA decreases

**Table 1**  
Summary of study characteristics and results.

Study	Subjects	Subtypes	Gender (% male)	Age: range or M (SD)	Exclusion criteria	Analysis method	DTI measures	Regions examined	Positive findings in patients	Negative findings in patients
Hamilton et al. (2008)	17 ADHD, 16 NC	Any	100	12 (2.3)	Nonstimulant psychotropic medication, syndromes as fragile X, tuberous sclerosis, or generalized resistance to thyroid hormone.	ROI, correlation analyses	FA	CG, CC, corticospinal tract, fornix, optic radiations, SLF, UF, superior and inferior FOF	FA: ADHD < NC in corticospinal tract, SLF.	ADHD = NC in CG, CC, fornix, optic radiations, UF, superior and inferior FOF. No correlations between hyperactivity scores and FA.
Makris et al. (2008)	12 ADHD, 17 NC	Any (childhood diagnosis)	58	37–46	IQ < 75, sensory-motor handicaps, psychosis, neurological disorders, medical illnesses impairing neurocognitive function, substance abuse or dependence	ROI	FA	CG, SLF-II, fornix, forebrain	ADHD < NC in R CG and R SLF-II. Higher leftward asymmetry of FA in CG.	ADHD = NC for FA in fornix. ADHD = NC for FA in entire forebrain. Equal symmetry index for SLF-II
Bechtel et al. (2009)	14 ADHD, 12 NC	ADHD-I (9), ADHD-C (12)	100	9–14	Developmental disorder, neurological disorder, abnormal intelligence, genetic disorder	ROI	FA	Cerebellum	ADHD < NC for R middle cerebellar peduncle	ADHD = NC within cerebellum
Pavuluri et al. (2009)	13 ADHD, 15 NC	Unknown	92	13.4 (3.0)	Axis I DSM-IV disorder, neurological trauma or symptoms, speech or hearing difficulties, IQ < 70, substance abuse	ROI	FA, ADC, rFCI	Anterior, posterior and super region of IC, ACR, ILF, SLF, CG, splenium of CC	FA: ADHD ≤ NC in ACR, anterior/superior IC. R-FCI: ADHD < NC in anterior/superior IC, splenium of CC. ADC: ADHD > NC in ACR, anterior/posterior/superior IC, CG, ILF, SLF, splenium of CC.	FA: ADHD = NC in anterior IC, SLF, ILF, CG, splenium of CC. R-FCI: ADHD = NC in ACR, posterior IC, SLF, ILF, CG
Silk et al. (2009a)	15 ADHD, 15 NC	ADHD-C	100	8–18	Medical, neurological or psychiatric disorders	ROI	FA	Basal ganglia (CN, putamen/globus pallidus, thalamus)	Increase of FA in CN with age in ADHD group, not in control group	ADHD = NC increase w/age in putamen and thalamus. ADHD = NC for FA in all ROIs

Table 1 (Continued)

Study	Subjects	Subtypes	Gender (% male)	Age: range or M (SD)	Exclusion criteria	Analysis method	DTI measures	Regions examined	Positive findings in patients	Negative findings in patients
Cao et al. (2010)	28 ADHD, 27 NC	ADHD-I, ADHD-C	100	11–16	Left handedness, head trauma, neurological illness, serious physical disease, IQ < 85, born preterm (< 33 weeks)	ROI	FA	Corpus callosum	ADHD < NC in isthmus of CC.	ADHD = NC in all subdivisions of the CC except the isthmus. ADHD = NC for total CC.
Peterson et al. (2011) <sup>a</sup>	16 ADHD, 16 NC	Any	69% m	9–14	IQ < 80, history of speech/language disorder or basic word recognition difficulties, evidence of visual or hearing impairment, or history of other neurological or significant psychiatric disorder	VBA, ROI, correlation analyses	FA	Body/splenium/genu of the CC, ACR, posterior corona radiata, SLF, sagittal stratum, anterior/posterior IC, CG, superior FOF	VBA (FA): ADHD > NC in right superior frontal gyrus and posterior thalamic radiation, and L dorsal posterior CG, lingual gyrus, and parahippocampal gyrus. ROI: ADHD < NC in left sagittal stratum. Correlations: FA in L sagittal stratum/ADHD symptom severity	FA: no regions where ADHD < NC. Correlations: No FA/symptom severity correlations in ROIs other than L sagittal stratum
Ashtari et al. (2005) <sup>a</sup>	18 ADHD, 15 NC	ADHD-C	67	7–11	IQ < 70, psychotropic medication (except stimulant/atomoxetine), neurologic/endocrine disorders, Axis I psychiatric disorder, reading disability, parental history of bipolar disorder/schizophrenia	VBA, correlation analyses	FA	Frontal and cerebellar WM	FA: ADHD < NC in R premotor, R striatal, R cerebral peduncle, L middle cerebellar peduncle, L cerebellum, L parieto-occipital areas. Correlations: FA in cerebellum/attentional symptoms	No correlation between premotor, striatal, parieto-occipital areas and cerebral peduncle and symptom measures
Silk et al. (2009b) <sup>a</sup>	15 ADHD, 15 NC	ADHD-C	100	8–18	Medical, neurological, endocrine or psychiatric disorders, IQ < 80, learning disorders, substance abuse	VBA (TBSS)	FA, MD	Whole brain	ADHD > NC for R CG, L UF, L ILF, R SLF	ADHD = NC for mean MD in whole brain

Davenport et al. (2010) <sup>a</sup>	14 ADHD, 26 NC	ADHD-C	85 (ADHD)/56 (NC)	10–20	Non-fluent English speakers, color blind, premature (>4 weeks), neurological conditions, IQ < 70, family history of schizophrenia, psychoactive medication other than stimulants, pervasive development disorder	VBA	FA	Whole brain	ADHD > NC in L inferior and R superior frontal regions. ADHD < NC in left posterior fornix.	N/A
Kobel et al. (2010) <sup>a</sup>	14 ADHD, 12 NC	ADHD-C, (9) ADHD-I (5)	100	9–13	History of neurological disease	VBA	FA	Whole brain	FA: ADHD > NC in L temporo-occipital WM, ADHD < NC in L ACR and R middle cerebellar peduncle	N/A
Konrad et al. (2010) <sup>a</sup>	37 ADHD, 34 NC	ADHD-C	57	18–49	IQ < 80, non-caucasian, left-handed, drug/alcohol abuse, medical/neurological illness, other psychiatric DSM axis I or II disorder	VBA, correlation	FA, MD	Whole brain	FA and MD: ADHD < NC bilaterally in orbitomedial prefrontal WM, R anterior CG. FA: ADHD > NC bilaterally in temporal WM. Correlations: FA/attention in R SLF, MD/attention in R frontobasal WM, FA/impulsivity in frontostriatal WM including UF and R anterior thalamic radiation, MD/impulsivity in bilateral lingual gyrus.	No correlations between BADDS ADHD scores (rating scale) and DTI parameters. No correlations between peak voxels DTI and attentional/impulsivity scores TOVA.
Li et al. (2010) <sup>a</sup>	24 ADHD, 20 NC	ADHD-C, ADHD-I	92	6–16	IQ < 70, psychotropic medication, neurologic/endocrine disorders, axis I psychiatric disorder requiring medication, parental history of Axis I/II psychiatric disorder	VBA, correlation	FA	Whole brain	FA: ADHD > NC in R frontal WM, Correlations: right frontal WM/Stroop test #correct and #corrections, right frontal WM/verbal fluency #errors (negatively)	N/A

Table 1 (Continued)

Study	Subjects	Subtypes	Gender (%m)	Age	Exclusion criteria	DTI method	DTI parameters	Regions examined	Positive findings in patients	Negative findings in patients
Qiu et al. (2010) <sup>a</sup>	15 ADHD, 15 NC	ADHD-I	100	10–15	IQ < 80, history of neuropsychiatric disorder	VBA	FA	Whole brain	ADHD < NC in forceps minor, IC, corona radiata, splenium of the CC, bilateral basal ganglia	N/A
Nagel et al. (2011) <sup>a</sup>	20 ADHD, 16 NC	Any	65 (ADHD)/25 (NC)	7–9	IQ < 75, parent-reported history of neurologic disorder/insult or major medical conditions, mental retardation, autism, psychotropic medication other than stimulants	VBA (TBSS)	FA, MD	Whole brain	ADHD < NC in frontoparietal, frontolimbic, cerebellar, corona radiata, and temporo-occipital WM; MD: ADHD < NC in posterior limb of IC and frontoparietal WM; ADHD > NC in frontolimbic WM.	N/A

Note: ACR, anterior corona radiata; ADC, Apparent Diffusion Coefficient; ADHD-C, ADHD combined subtype; CC, corpus callosum; CG, cingulum; CN, caudate nucleus; FA, fractional anisotropy; FOF, fronto-occipital fasciculus; ADHD-I, ADHD inattentive subtype; IC, internal capsule; ILF, inferior longitudinal fasciculus; L, left hemisphere; MD, Mean Diffusivity; R, right hemisphere; r-FCI, regional fibre coherence index; ROI, region of interest; SLF, superior longitudinal fasciculus; TBSS, tract-based statistics; UF, uncinate fasciculus; VBA, voxel-based analysis; WM, white matter.

<sup>a</sup> Results included in ALE.

were found in ADHD subjects in both ROIs in the right hemisphere, in contrast to the control region. No significant FA differences were found in the left hemisphere. Furthermore, the authors did an exploratory analysis on FA in the most compact bundles (so-called stems) in the forebrain, but did not find significant differences between the groups. Symmetry analyses, expressing the difference of FA between corresponding regions in both hemispheres (based on Galaburda et al., 1987) showed a leftward asymmetry for the cingulum in both groups, but significantly more so in the ADHD group. The superior longitudinal fasciculus-II symmetry index did not differ between the groups.

Another study also investigated the superior longitudinal fasciculus and cingulum, as well as the inferior longitudinal fasciculus (connecting the temporal and occipital lobes), splenium of the corpus callosum (connecting occipital regions), anterior corona radiata (a WM sheet radiating from the basal ganglia and spinal cord into the cortex), and the internal capsule (a WM structure which separates the caudate nucleus from the globus pallidus and putamen), subdivided into the anterior limb, superior region, and posterior limb (Pavuluri et al., 2009). Their sample consisted of ADHD patients, mean age 13, and healthy age matched controls. Results showed decreased FA only in the anterior corona radiata and both the anterior limb and superior region of the internal capsule. Apart from FA, the authors included two less commonly used measures; the Apparent Diffusion Coefficient (ADC), a measure similar to MD, representing the magnitude of water diffusion, and regional fibre coherence index (r-FCI), a multivariate second-moment (“covariance”) measure of the first eigenvalue, representing the degree of coherence in a given fibre tract (Zhou and Leeds, 2005). Lower ADC was demonstrated in all 8 ROIs investigated for ADHD patients, and lower r-FCI values were found in the anterior limb and superior region of the internal capsule as well as the splenium of the corpus callosum.

In a recent study, eleven ROIs were chosen based on their possible relevance to functional deficits in ADHD, given their hypothesized structure–function relationships (Peterson et al., 2011): the body, splenium and genu of the corpus callosum, anterior and posterior corona radiata, anterior and posterior limb of the internal capsule, superior longitudinal fasciculus, sagittal stratum (connecting the temporal lobe to distant cortical regions, comprising parts of the corticocortical tract, optic radiation, and inferior longitudinal fasciculus), and the superior fronto-occipital fasciculus. FA was compared between children with ADHD (inattentive or combined subtype) and healthy gender-matched controls, aged 9–14. Of all regions examined, the left sagittal stratum was the only region in which FA differed between groups: Children with ADHD showed increased FA as compared to healthy controls.

### 3.1.2. VBA studies

VBA studies, exploring the whole brain for white matter abnormalities, have become increasingly popular during recent years. The first study adopting a voxelwise analysis approach to investigate white matter integrity in ADHD patients was published in 2005 (Ashtari et al., 2005). The authors compared children with ADHD-C and well-matched healthy controls, aged 7–11 years, concerning FA throughout the whole brain. Results showed decreased FA in children with ADHD in right premotor, right striatal, and left parieto-occipital areas, as well as the right cerebral peduncle, left middle cerebellar peduncle, and left cerebellum (anterior lobe).

A second VBA study adopted a slightly different approach using a tract based statistics (TBSS) method (Smith et al., 2006). TBSS is a statistical method in which a white-matter skeleton mask is used to identify and restrict analyses to the centre of major WM tracts, thus minimizing the potential misalignment problems that can arise in regular VBA analyses. The study compared children and adolescents with ADHD-C, 8–18 years, with healthy age-matched



controls on FA throughout the whole brain (Silk et al., 2009b). To minimize false positives, FA maps were thresholded and clusters were analysed with a minimum cluster size and tested at a significance level corrected for multiple comparisons. In contrast to the decreased FA generally found in ROI studies, the authors found three distinct clusters of *increased* FA in ADHD patients within right parietal–occipital regions, left inferior frontal cortex/striatum, and left inferior temporal regions (in terms of WM tracts, the authors label these regions as the cingulum, uncinata fasciculus and inferior longitudinal fasciculus, respectively). Two other clusters with a trend towards significantly *increased* FA for ADHD patients lay in the right inferior parietal region (superior longitudinal fasciculus) and left inferior frontal region (uncinate fasciculus). For most clusters, significant *increases* in axial diffusivity were found, but also *decreases* in radial diffusivity. The latter findings suggest that the greater FA found in ADHD might result from less neuronal branching in the investigated WM pathways. There were no MD differences between ADHD patients and control participants.

The largest study so far ( $N > 30$  for both groups) was conducted using a unique sample of 37 never-medicated adults with childhood-onset ADHD-C (all of whom still met criteria for ADHD-C at the time of assessment) and 34 healthy controls, aged 18–49, mean age 32 years (Konrad et al., 2010). Significant clusters of *reduced* FA were found in ADHD patients in the right anterior cingulum, as well as in bilateral orbitofrontal WM structures, including frontal parts of the inferior fronto-occipital fasciculus, parts of the anterior thalamic radiation located in the orbitofrontal cortex, and parts of the corpus callosum. Clusters of *elevated* FA were found in bilateral temporal WM in ADHD patients, including portions of the fronto-occipital fasciculus. MD was found to be *elevated* in patients in the left superior longitudinal fasciculus as well as bilaterally in orbitofrontal WM, including the inferior fronto-occipital fasciculus and uncinata fasciculus, extending into the anterior thalamic radiation.

Another study reported a comparison of patients with ADHD-C and healthy controls, aged 10–20 years on FA throughout the brain (Davenport et al., 2010). To correct for false positives, FA maps were thresholded at  $FA > 0.25$ . Clusters of *elevated* FA in ADHD patients were identified in left posterior and right superior prefrontal regions, which were considered to represent areas of the anterior corona radiata. Moreover, the left posterior fornix showed *lower* FA in ADHD patients than in healthy controls.

Consistent with previous research, again another study found alterations in frontal and cerebellar WM in children with ADHD (combined or inattentive subtype), as compared to healthy controls, all aged 9–13 (Kobel et al., 2010). ADHD patients showed *decreased* FA in the left anterior corona radiata and right middle cerebellar peduncle, as well as *increased* FA in left temporo-occipital WM.

Another study reporting altered anisotropy in frontal WM compared children and young adolescents with ADHD to healthy, well-matched controls, aged 6–16 years (Li et al., 2010). Three clusters of *increased* FA were found in different areas of right frontal WM. While clusters were described in terms of  $x/y/z$  coordinates only, they are likely to represent fibres of the anterior and superior corona radiata.

One study examined WM integrity in ADHD patients with only the inattentive subtype (ADHD-I) and healthy well-matched controls, aged 10–15 years (Qiu et al., 2010). FA maps were thresholded at  $FA > 0.15$ . Relatively large clusters of *decreased* FA were found for ADHD-I patients in the forceps minor, internal capsule, corona radiata, splenium of the corpus callosum, and bilateral basal ganglia.

One whole-brain analysis was conducted in the same sample in which ROI analyses were conducted, as described above (Peterson et al., 2011, see Section 3.1). Whole-brain analyses showed *increased* FA in the ADHD group in posterior

temporal–parietal WM and more specifically in the right superior frontal gyrus, posterior thalamic radiation, left dorsal posterior cingulum, lingual gyrus, and hippocampal gyrus.

A recent VBA study using TBSS compared young children with ADHD (all subtypes, 7–9 years) with well-matched healthy controls on measures of FA and MD, and conducted additional radial/axial diffusivity analyses in order to examine the cause of FA/MD differences more specifically (Nagel et al., 2011). To correct for false positives, cluster size thresholding was used ( $FA > .02$ ), as well as a significance level corrected for multiple comparisons. The authors reported *decreased* FA in frontoparietal, frontolimbic, and cerebellar structures, as well as in the corona radiata and temporo-occipital WM, as compared with controls. Additionally, *lower* MD was found in the posterior internal capsule and frontoparietal WM, and greater MD in frontolimbic WM. Although FA/MD differences were due to a combination of differences in both axial and radial diffusivity between groups, differences were most apparent in frontolimbic WM, in which the ADHD group showed *increased* radial diffusivity. These results suggest that especially the later maturing frontolimbic pathways were abnormal in children with ADHD, seemingly due to decreased or delayed myelination of these areas.

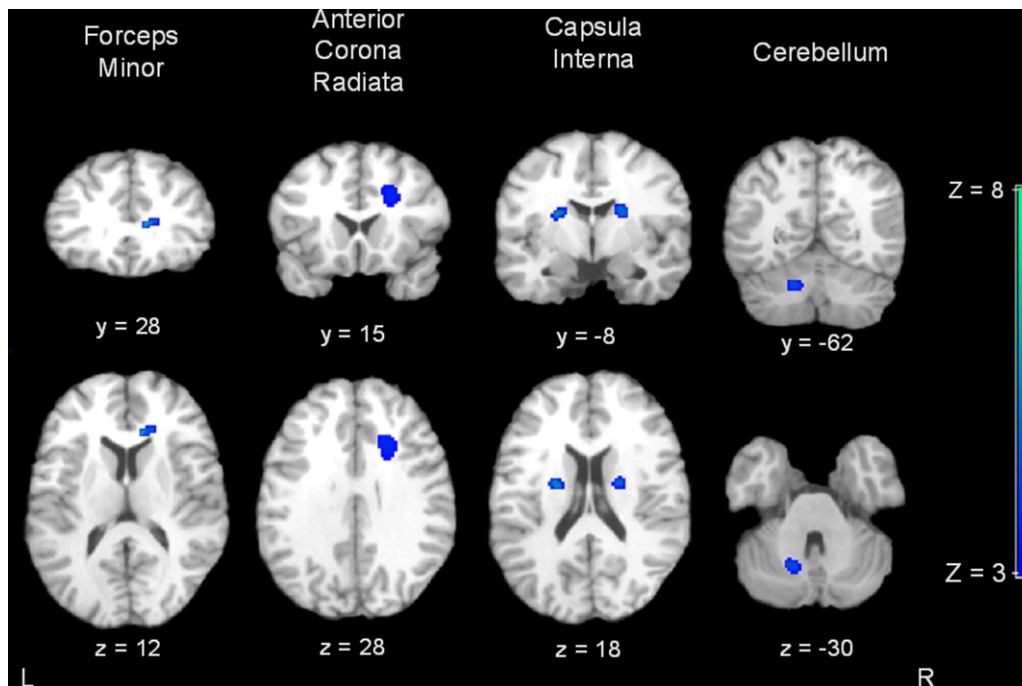
### 3.1.3. Associations with behavioural and cognitive measures

To investigate the functional implications of WM abnormalities in ADHD, five of the reviewed studies investigated the association between behavioural symptoms of ADHD and DTI measures. One study demonstrated that decreases in cerebellar FA parallel increases in parent rated inattentive symptoms in children with ADHD (large effect size) (Ashtari et al., 2005). Another study found a positive association (large effect size) between FA in the left sagittal stratum and total parent- and teacher rated ADHD symptomatology (Peterson et al., 2011), and a third study found associations between a broad range of FA clusters and ADHD symptoms, most significantly so with the inattentive subscale (effect sizes unknown) (Nagel et al., 2011). In contrast, two studies did not find any behavioural correlates of DTI measures; one study failed to find significant associations between FA in any of their ROIs and parent ratings of hyperactivity in children with ADHD (Hamilton et al., 2008), while another study did not find any significant associations between FA/MD and self-reported ADHD symptoms in their sample of adults with a childhood and current ADHD diagnosis (Konrad et al., 2010).

Some other interesting associations have been found between WM integrity and cognitive measures known to be disturbed in ADHD. One study showed that in their sample of never-medicated adults with ADHD, measures of attentional focus correlated positively with FA parameters in the right superior longitudinal fasciculus, and negatively with MD in the same area (effect sizes unknown) (Konrad et al., 2010). Moreover, measures of impulsivity negatively correlated with FA in right orbitofrontal fibre tracts, and positively correlated with MD in the lingual gyrus (bilaterally). Examining correlations between right frontal FA and different cognitive measures, another study demonstrated significant positive associations with a measure of interference control for ADHD patients as well as healthy controls (large effect sizes). Moreover, negative associations were found between right frontal FA and verbal fluency (ADHD), and hyperactivity (controls) (Li et al., 2010).

### 3.2. ALE meta-analysis

Nine VBA studies were included in the meta-analysis (see Table 1) with a total of 173 ADHD patients and 169 healthy control subjects (ages ranging from 7 to 49 years), providing 53 foci of increased or decreased FA in patients. The ALE analysis revealed 5 significant clusters, representing areas of altered FA in patients



**Fig. 1.** Results of the ALE meta-analysis showing clusters with significant ALE maxima ( $Z > 3$ ;  $p_{\text{corrected}} < 0.05$ ) superimposed on a structural scan in Talairach space. Top row: coronal view, bottom row: axial view. L = left, R = right.

with ADHD that were most consistently reported across the VBA studies (results are summarised in Table 2 and visualised in Fig. 1).

The largest cluster ( $1584 \text{ mm}^3$ ) was located in the right anterior corona radiata, likely containing fibres from the superior longitudinal fasciculus, with five foci inside this cluster. A second cluster was found in the left cerebellar WM, containing two foci ( $296 \text{ mm}^3$ ). Two clusters were bilaterally located in the internal capsule ( $200$  and  $288 \text{ mm}^3$ ), each containing two foci. The smallest significant cluster was located in the right forceps minor, close to the genu of the corpus callosum ( $152 \text{ mm}^3$ ) and also contained two foci.

## 4. Discussion

### 4.1. Summary

Results of reviewed studies provide clear evidence of disturbed white matter integrity in children, adolescents and adults with ADHD. The seven ROI studies demonstrated deficits in several selected WM regions and tracts, including the inferior and superior longitudinal fasciculus, anterior corona radiata, corticospinal tract, cingulum, corpus callosum, internal capsule, caudate nucleus, and cerebellum. Nine studies using voxelwise whole-brain analyses confirmed WM alterations in these regions, and also found differences in the uncinate fasciculus, forceps minor, areas within

the basal ganglia, and widespread differences in the frontal, temporal, parietal and occipital lobes.

In our meta-analysis, five clusters were reliably identified as being reported across studies, located in the right anterior corona radiata (likely containing fibres from the superior longitudinal fasciculus), forceps minor close to the genu of the corpus callosum, right and left internal capsule, and left cerebellar WM. While only 4 out of 9 papers contributed directly to the significant clusters from our ALE meta-analysis (Davenport et al., 2010; Li et al., 2010; Nagel et al., 2011; Qiu et al., 2010), some of the remaining studies found clusters of altered FA close to the same regions, but not close enough to be located inside ALE clusters. After increasing the inclusion range to a distance of 20 mm from the centre of each cluster, clusters were supported by 6 out of 9 papers, with 4–8 foci contributing to each cluster. It is interesting to note that two of the ALE clusters were located within the limbic system, an area in which two studies demonstrated a delay in the development of myelination in ADHD patients (Nagel et al., 2011; Silk et al., 2009a). Studies investigating adolescents or adults might have failed to find group differences in these areas due to the fact that in their samples, myelination of these areas had already caught up in ADHD patients.

It is difficult, if not impossible, to draw firm conclusions regarding clusters that were reported in VBA studies, but *not* proven significant in our meta-analysis. These clusters may be the result

**Table 2**  
Activation likelihood estimation results of white matter abnormalities in ADHD patients.

Cluster #	Volume ( $\text{mm}^3$ )	ALE value ( $\times 10^{-3}$ ) <sup>a</sup>	Talairach coordinates <sup>b</sup>			Label <sup>c</sup>
			x	y	z	
1	152	9.029	14	28	12	R Forceps Minor
2	1584	15.797	20	15	30	R Anterior Corona Radiata
3	200	9.673	-21	-8	18	L Internal Capsule
4	288	11.107	19	-8	19	R Internal Capsule
5	296	11.355	-14	-62	-30	L Cerebellum

<sup>a</sup> Peak activation likelihood estimate within cluster.

<sup>b</sup> Weighted centre of mass of the cluster.

<sup>c</sup> L, left hemisphere; R, right hemisphere.

of differences between studies in terms of sample characteristics, scanning methodology, small misalignments due to eddy currents or residual head motion, processing parameters or analysis techniques. Some may be due to false positives; others may be meaningful clusters of disturbed WM in ADHD, in need of replication in future research. Some studies found altered FA/MD in other parts of tracts or regions in which the ALE clusters were located. For example, altered WM integrity was demonstrated in the superior longitudinal fasciculus (Hamilton et al., 2008; Makris et al., 2008; Pavuluri et al., 2009; Silk et al., 2009a), anterior corona radiata (Kobel et al., 2010; Pavuluri et al., 2009), cerebellum (Ashtari et al., 2005; Bechtel et al., 2009; Kobel et al., 2010), and areas in or close to the internal capsule (Nagel et al., 2011; Pavuluri et al., 2009; Silk et al., 2009a). It is possible that, as DTI research into ADHD grows, more clusters in similar regions will be found, and the ALE clusters will expand, containing entire WM tracts instead of local areas.

Some of the regions in which the meta-analysis showed significant clusters of altered WM, were also investigated in ROI studies. While some ALE clusters were confirmed by ROI analyses, including WM alterations in the anterior corona radiata, internal capsule and cerebellum (Ashtari et al., 2005; Bechtel et al., 2009; Pavuluri et al., 2009), other studies did not support ALE findings in the anterior corona radiata, internal capsule and genu of the corpus callosum (Cao et al., 2010; Peterson et al., 2011). Divergent findings are likely due to differences in template or atlas selection and processing and analysis parameters. It is also possible that, by averaging DTI measures over a larger area, ROI studies have missed the specific peak voxels of the clusters found by ALE.

In general, it is interesting to note that all clusters of altered WM in ROI studies showed *decreased* anisotropy in ADHD patients, whereas whole-brain studies have identified *decreases* as well as *increases* in FA. Decreased FA in patients is likely to result from axonal damage, or can be found in areas with decreased or delayed myelination. Elevated FA represents greater directional coherence of diffusion and is therefore associated with less neuronal branching in patients. The fact that whole-brain studies have identified increased as well as decreased FA (as opposed to ROI studies, in which only decreased FA has been reported), might be a result of including more regions with large amounts of fibre crossings in these studies. Three whole-brain studies decomposed FA into axial and radial components in order to investigate the exact nature of the WM alterations observed in ADHD. One study reported that the increased FA they found in children and adolescents with ADHD resulted from greater axial and lower radial diffusivity along the WM tracts they examined, suggesting relative axonal intactness, but a decrease in neuronal branching in these areas (Silk et al., 2009b). In very young children with ADHD, increased radial diffusivity was demonstrated in frontolimbic areas, suggesting delayed myelin development in these regions (Nagel et al., 2011). The fact that the authors used a sample of pre-adolescent children might explain the fact that these differences were not found in other samples with older participants. This hypothesis is supported by the finding that WM development of the caudate nucleus shows a differential developmental trajectory for children and adolescents with ADHD as compared to healthy controls, which catches up during late adolescence (Silk et al., 2009a), consistent with earlier findings from sMRI (Castellanos et al., 2002).

Taken together, our meta-analysis shows five clusters of disturbed WM in ADHD patients, located in WM tracts subserving the fronto-striatal-cerebellar neurocircuitry. These results are consistent with previous findings from other neuroimaging modalities, and extend current literature by showing that the deficiencies observed in ADHD patients in these networks might, at least partly, originate from disturbed microstructural connectivity.

#### 4.2. Limitations of current literature

Despite the promising results of the reviewed studies, several important limitations impede the interpretation of the studies. First, while the effect of gender and IQ on WM integrity is still largely unclear, both factors have been suggested to influence DTI measures (Bava et al., 2011; Chiang et al., 2009). More conservative group matching can prevent important group differences to lead to false positives and negatives in future studies.

Secondly, at a statistical level, large heterogeneity is observed in statistical corrections and thresholding. Only three studies seem to have corrected their results for multiple comparisons and Type I errors (Cao et al., 2010; Nagel et al., 2011; Silk et al., 2009b). Especially in whole-brain analyses it is highly advised to use thresholded FA maps, a minimum cluster size, and significance levels corrected for multiple comparisons, in order to minimize the chance of false positives (Chumbley et al., 2010; Chumbley and Friston, 2009; Nichols and Hayasaka, 2003; Peterson, 2003). Since the majority of the whole-brain studies applied uncorrected statistics, these results must be interpreted with great caution.

A third complicating factor in analysing DTI data is head motion during scanning. It is known that head motion is difficult to correct for, and negatively influences scanning results by producing a positive bias in FA and MD measures (Ling et al., 2011; Rohde et al., 2004; Tijssen et al., 2009). Apart from the fact that head motion causes artefacts in DTI data, the problem increases with group comparisons in which one of the groups is more prone to (head) movement than the other, e.g. in children and ADHD research. Despite the importance of this issue, only half of the reviewed studies applied head motion correction to their data, and only one study checked for group differences in head motion (Nagel et al., 2011). Three studies corrected for rigid body movement during scanning, and 5 studies corrected for simple movement using eddy current correction, leaving 7 studies uncorrected for head movement. This induces a large risk for false group differences (regarding increased FA or MD) in several of the reviewed studies.

Several factors play an important role in the comparability of results between studies, one of the most important being the heterogeneity of age groups. The large changes in brain structure and functioning during typical development, combined with the fact that children with ADHD seem to show a delayed trajectory of brain development, raises the issue whether differences in WM integrity can reliably be studied cross-sectionally in a specific age group. It also raises the question whether multiple studies with different age groups can be compared reliably and whether findings can be generalized to different developmental stages. To avoid these issues, it is important to extensively replicate findings in separate age groups on the one hand and keep a possible developmental delay in mind while interpreting such results, and on the other hand conduct longitudinal studies in order to resolve the issue of a possible developmental delay in WM integrity in ADHD.

Other factors that might influence differences in findings between studies include medication status, diagnostic methods, ADHD subtypes, and matching criteria (e.g. gender, IQ). Even though none of the studies so far have specifically addressed the issue of medication effects on white matter *integrity*, it has been suggested that white matter *volume* is susceptible to stimulant medication (Castellanos et al., 2002). Of the reviewed studies, only one study solely used medication naïve patients, therefore controlling for possible medication effects (Konrad et al., 2010). One study controlled for volumetric differences in the WM structure examined, and found no significant association between FA and volume measures in the corpus callosum (Cao et al., 2010).

A lack of adequate diagnostic methods is another factor that could possibly have led to false negatives and thus can compromise comparability between studies. While ADHD diagnostics are best

performed using a combination of a clinical interview combined with questionnaires filled in by different informants, e.g. parent and teacher ratings (Charach et al., 2009; Muller et al., 2011; Valo and Tannock, 2010), many of the reviewed studies based their diagnosis on questionnaires only, and/or used only one informant. One study used an adult sample with a childhood diagnosis, in which more than half of the ADHD patients did no longer meet the criteria for the disorder (Makris et al., 2008). This raises the question whether these patients with 'remitted' ADHD are likely to show the same brain abnormalities as do 'persistent' ADHD patients, and whether or not these findings can be compared and generalized to all ADHD patients. Inconsistencies in diagnostics are very likely to have led to differences between studies, and could also explain part of the inconsistencies between findings.

#### 4.3. The future of DTI research in ADHD

Despite the fact that reviewed studies confirm the hypothesis of widespread alterations in white matter integrity in patients with ADHD, reviewing these studies also highlights important limitations in current literature, and produces several questions and challenges for future research. Given the large risk of Type I and II errors in current literature, due to several limitations as discussed above, more research is needed in order to replicate findings and draw firmer conclusions. For example, further research can provide us with more insight into the influence of specific sample characteristics (including medication use, gender, and ADHD subtypes) on DTI measures, allowing us to choose our samples more carefully.

In future research, particular attention should be paid to the interpretation of DTI findings. While most studies demonstrated differences in DTI measures between ADHD and control participants, most authors solely summarize their findings, without providing solid interpretations. Future research will benefit from interpreting increases or decreases in DTI parameters on a neurobiological level (i.e. what does an increase or decrease in a specific area mean?), linking this information to functional implications (i.e. what consequences do these WM alterations have for neurocognitive and behavioural functioning), and ultimately embed the results in current literature and hypotheses regarding the aetiology of ADHD. While radial/axial diffusivity analyses of eigenvalues are a first attempt to provide us with more insight into the exact underlying neurobiological mechanisms, none of the reviewed studies have used the *mode of anisotropy* (the ratio between diffusivity in the principal and perpendicular directions), which could have given more insight into this issue. Another technique that could provide more insight into the anatomical correlates of DTI parameters is Magnetization Transfer (MT) imaging, an imaging modality that is highly sensitive to myelin (Engelbrecht et al., 1998; Kobel et al., 2010; Wozniak and Lim, 2006), yielding parameters such as the MT ratio (MTR) and 'MT saturation', a novel semiquantitative parameter for MT proposed by Helms et al. (2010). Using a combination of DTI and MT measures, findings can be interpreted more robustly in terms of confirming or contradicting demyelination as a cause of altered DTI parameters (such as in Mandl et al., 2010). Future studies could possibly benefit from using more advanced diffusion imaging techniques (beyond the conventional tensor model; see Alexander, 2005 for a review) and alternative techniques (such as MT), ultimately leading to a better understanding of the specific microstructural alterations in the ADHD brain.

Future studies will also benefit from investigating the possible neurocognitive and behavioural correlates of DTI measures, providing us with more insight into the functional repercussions of WM abnormalities in ADHD patients. While current results suggest a possible differential effect of alterations in distinct WM pathways on symptoms of inattention and hyperactivity (Ashtari et al., 2005; Hamilton et al., 2008; Konrad et al., 2010; Li et al., 2010; Peterson

et al., 2011), these findings are in need of replication. Additionally, direct group comparisons on DTI measures between groups with different ADHD subtypes will provide us with more insight into the differential neurobiological underpinnings of these subtypes.

Interesting challenges for future DTI research in ADHD also include more fundamental questions, including whether WM abnormalities are the (partial) cause of neurocognitive and behavioural symptoms observed in ADHD, or rather a result. Moreover, more knowledge about the development of WM tracts in ADHD will add insight into the issue whether brain abnormalities in ADHD are a developmental delay compared to healthy controls, or a more general and persistent deficit.

As the number and quality of DTI studies in ADHD rises, it will be valuable to evaluate the sensitivity and specificity of DTI measures to abnormalities in the ADHD brain, as compared to typically developing children. While it is known that DTI is highly sensitive to subtle WM changes in the human brain, so far, little is known about its sensitivity to abnormalities specifically in the ADHD brain, as compared to different modalities like sMRI, fMRI and resting state scans. In order to evaluate the usefulness of DTI in ADHD research, it is important to investigate the contribution of DTI as a stand-alone technique as opposed to earlier established neuroimaging methods, as well as in combination with these techniques. DTI has also been speculated to be highly reliable in early diagnostic prediction of autism (Ingalhalikar et al., 2011) and differentiation between schizophrenia and healthy controls (Ardekani et al., 2011). These findings implicate a possibly important role of this technique in the future of ADHD detection and differentiation as well.

One last difficult but important challenge in future research is to relate DTI findings to genetic factors. While some studies have started to investigate the relationship between DTI measures and cognitive and behavioural measures, the possible genetic underpinnings of WM abnormalities are still under investigated. Available literature shows that WM volume and architecture as measured by sMRI and DTI are highly heritable (Hulshoff Pol et al., 2006; Jahanshad et al., 2010; Pfefferbaum et al., 2001), suggesting strong genetic influences on WM development. However, to our knowledge, influences of specific ADHD risk genes on WM integrity in the ADHD brain have not been investigated so far. Between the high heritability of the disorder and the large variations in neurocognitive and behavioural functioning, DTI could very well provide us with an important new endophenotype of ADHD, bringing us one step closer to a more complete picture of the genetic underpinnings of ADHD.

#### 4.4. Conclusion

In this paper, we have pointed out a variety of important limitations of the reviewed studies. The use of DTI in ADHD research is still a new developing field, and has so far produced a large heterogeneity in methodology and results, impeding the comparability and generalizability of findings. However, despite these limitations, reviewing current literature has provided us with a fairly consistent image of specific abnormalities in white matter integrity in patients with ADHD. Altered WM integrity was most evident in the right anterior corona radiata (possibly also containing fibres from the superior longitudinal fasciculus), right forceps minor close to the corpus callosum, bilateral internal capsule, and left cerebellum, consistent with previous research using other neuroimaging modalities. Despite the methodological and statistical challenges we are facing in future research, DTI proves to be a very useful and promising technique in investigating the neurobiological underpinnings of the disorder, providing us with new prospects and challenges for future research into the neurobiological basis of the disorder.

## References

- Albayrak, O., Friedel, S., Schimmelmann, B.G., Hinney, A., Hebebrand, J., 2008. Genetic aspects in attention-deficit/hyperactivity disorder. *J. Neural Transm.* 115, 305–315.
- Alexander, A.L., Lee, J.E., Lazar, M., Field, A.S., 2007. Diffusion tensor imaging of the brain. *Neurotherapeutics* 4, 316–329.
- Alexander, D.C., 2005. Multiple-fiber reconstruction algorithms for diffusion MRI. *Ann. N.Y. Acad. Sci.* 1064, 113–133.
- Ardekani, B.A., Tabesh, A., Sevy, S., Robinson, D.G., Bilder, R.M., Szeszko, P.R., 2011. Diffusion tensor imaging reliably differentiates patients with schizophrenia from healthy volunteers. *Hum. Brain Mapp.* 32, 1–9.
- Ashtari, M., Kumra, S., Bhaskar, S.L., Clarke, T., Thaden, E., Cervellone, K.L., Rhinewine, J., Kane, J.M., Adelman, A., Milanaik, R., Maytal, J., Diamond, A., Szeszko, P., Ardekani, B.A., 2005. Attention-deficit/hyperactivity disorder: a preliminary diffusion tensor imaging study. *Biol. Psychiatry* 57, 448–455.
- Basser, P.J., Mattiello, J., LeBihan, D., 1994. Estimation of the effective self-diffusion tensor from the NMR spin echo. *J. Magn. Reson. B* 103, 247–254.
- Batty, M.J., Liddle, E.B., Pitiot, A., Toro, R., Groom, M.J., Scerif, G., Liotti, M., Liddle, P.F., Paus, T., Hollis, C., 2010. Cortical gray matter in attention-deficit/hyperactivity disorder: a structural magnetic resonance imaging study. *J. Am. Acad. Child Adolesc. Psychiatry* 49, 229–238.
- Bava, S., Boucquey, V., Goldenberg, D., Thayer, R.E., Ward, M., Jacobus, J., Tapert, S.F., 2011. Sex differences in adolescent white matter architecture. *Brain Res.* 1375, 41–48.
- Beaulieu, C., 2002. The basis of anisotropic water diffusion in the nervous system – a technical review. *NMR Biomed.* 15, 435–455.
- Bechtel, N., Kobel, M., Penner, I.K., Klarhofer, M., Scheffler, K., Opwis, K., Weber, P., 2009. Decreased fractional anisotropy in the middle cerebellar peduncle in children with epilepsy and/or attention deficit/hyperactivity disorder: a preliminary study. *Epilepsy Behav.* 15, 294–298.
- Biederman, J., Mick, E., Faraone, S.V., 2000. Age-dependent decline of symptoms of attention deficit hyperactivity disorder: impact of remission definition and symptom type. *Am. J. Psychiatry* 157, 816–818.
- Bookstein, F.L., 2001. Voxel-based morphometry should not be used with imperfectly registered images. *Neuroimage* 14, 1454–1462.
- Brett, M., 1999. The MNI Brain and the Talairach Atlas.
- Bush, G., Valera, E.M., Seidman, L.J., 2005. Functional neuroimaging of attention-deficit/hyperactivity disorder: a review and suggested future directions. *Biol. Psychiatry* 57, 1273–1284.
- Canu, E., McLaren, D.G., Fitzgerald, M.E., Bendlin, B.B., Zoccali, G., Alessandrini, F., Pizzini, F.B., Ricciardi, G.K., Beltramello, A., Johnson, S.C., Frisoni, G.B., 2010. Microstructural diffusion changes are independent of macrostructural volume loss in moderate to severe Alzheimer's disease. *J. Alzheimers Dis.* 19, 963–976.
- Cao, Q., Sun, L., Gong, G., Lv, Y., Cao, X., Shuai, L., Zhu, C., Zang, Y., Wang, Y., 2010. The macrostructural and microstructural abnormalities of corpus callosum in children with attention deficit/hyperactivity disorder: a combined morphometric and diffusion tensor MRI study. *Brain Res.* 1310, 172–180.
- Castellanos, F.X., Acosta, M.T., 2004. The neuroanatomy of attention deficit/hyperactivity disorder. *Rev. Neurol.* 38 (Suppl. 1), S131–S136.
- Castellanos, F.X., Lee, P.P., Sharp, W., Jeffries, N.O., Greenstein, D.K., Clasen, L.S., Blumenthal, J.D., James, R.S., Ebens, C.L., Walter, J.M., Zijdenbos, A., Evans, A.C., Giedd, J.N., Rapoport, J.L., 2002. Developmental trajectories of brain volume abnormalities in children and adolescents with attention-deficit/hyperactivity disorder. *JAMA* 288, 1740–1748.
- Charach, A., Chen, S., Hogg-Johnson, S., Schachar, R.J., 2009. Using the Conners' Teacher Rating Scale-Revised in school children referred for assessment. *Can. J. Psychiatry* 54, 232–241.
- Chiang, M.C., Barysheva, M., Shattuck, D.W., Lee, A.D., Madsen, S.K., Avedissian, C., Klunder, A.D., Toga, A.W., McMahon, K.L., de Zubicaray, G.I., Wright, M.J., Srivastava, A., Balov, N., Thompson, P.M., 2009. Genetics of brain fiber architecture and intellectual performance. *J. Neurosci.* 29, 2212–2224.
- Chumbley, J., Worsley, K., Flandin, G., Friston, K., 2010. Topological FDR for neuroimaging. *Neuroimage* 49, 3057–3064.
- Chumbley, J.R., Friston, K.J., 2009. False discovery rate revisited: FDR and topological inference using Gaussian random fields. *Neuroimage* 44, 62–70.
- Concha, L., Livy, D.J., Beaulieu, C., Wheatley, B.M., Gross, D.W., 2010. In vivo diffusion tensor imaging and histopathology of the fimbria-fornix in temporal lobe epilepsy. *J. Neurosci.* 30, 996–1002.
- Davenport, N.D., Karatekin, C., White, T., Lim, K.O., 2010. Differential fractional anisotropy abnormalities in adolescents with ADHD or schizophrenia. *Psychiatry Res.* 181, 193–198.
- Douaud, G., Jabdi, S., Behrens, T.E., Menke, R.A., Gass, A., Monsch, A.U., Rao, A., Whitcher, B., Kindlmann, G., Matthews, P.M., Smith, S., 2011. DTI measures in crossing-fibre areas: increased diffusion anisotropy reveals early white matter alteration in MCI and mild Alzheimer's disease. *Neuroimage* 55, 880–890.
- Durston, S., Hulshoff Pol, H.E., Schnack, H.G., Buitelaar, J.K., Steenhuis, M.P., Minderaa, R.B., Kahn, R.S., van Engeland, H., 2004. Magnetic resonance imaging of boys with attention-deficit/hyperactivity disorder and their unaffected siblings. *J. Am. Acad. Child Adolesc. Psychiatry* 43, 332–340.
- Durston, S., Konrad, K., 2007. Integrating genetic, psychopharmacological and neuroimaging studies: a converging methods approach to understanding the neurobiology of ADHD. *Dev. Rev.* 27, 374–395.
- Eickhoff, S.B., Laird, A.R., Grefkes, C., Wang, L.E., Zilles, K., Fox, P.T., 2009. Coordinate-based activation likelihood estimation meta-analysis of neuroimaging data: a random-effects approach based on empirical estimates of spatial uncertainty. *Hum. Brain Mapp.* 30, 2907–2926.
- Engelbrecht, V., Rassek, M., Preiss, S., Wald, C., Modder, U., 1998. Age-dependent changes in magnetization transfer contrast of white matter in the pediatric brain. *AJNR Am. J. Neuroradiol.* 19, 1923–1929.
- Ennis, D.B., Kindlmann, G., 2006. Orthogonal tensor invariants and the analysis of diffusion tensor magnetic resonance images. *Magn. Reson. Med.* 55, 136–146.
- Fair, D.A., Posner, J., Nagel, B.J., Bathula, D., Dias, T.G., Mills, K.L., Blythe, M.S., Giwa, A., Schmitt, C.F., Nigg, J.T., 2010. Atypical default network connectivity in youth with attention-deficit/hyperactivity disorder. *Biol. Psychiatry* 68, 1084–1091.
- Filipek, P.A., Semrud-Clikeman, M., Steingard, R.J., Renshaw, P.F., Kennedy, D.N., Biederman, J., 1997. Volumetric MRI analysis comparing subjects having attention-deficit hyperactivity disorder with normal controls. *Neurology* 48, 589–601.
- Fjell, A.M., Westlye, L.T., Greve, D.N., Fischl, B., Benner, T., van der Kouwe, A.J., Salat, D., Bjørnerud, A., Due-Tønnessen, P., Walhovd, K.B., 2008. The relationship between diffusion tensor imaging and volumetry as measures of white matter properties. *Neuroimage* 42, 1654–1668.
- Galaburda, A.M., Corsiglia, J., Rosen, G.D., Sherman, G.F., 1987. Planum temporale asymmetry: reappraisal since Geschwind and Levitsky. *Neuropsychologia* 25, 853–858.
- Hamilton, L.S., Levitt, J.G., O'Neill, J., Alger, J.R., Luders, E., Phillips, O.R., Caplan, R., Toga, A.W., McCracken, J., Narr, K.L., 2008. Reduced white matter integrity in attention-deficit hyperactivity disorder. *Neuroreport* 19, 1705–1708.
- Helms, G., Dathe, H., Dechent, P., 2010. Modeling the influence of TR and excitation flip angle on the magnetization transfer ratio (MTR) in human brain obtained from 3D spoiled gradient echo MRI. *Magn. Reson. Med.* 64, 177–185.
- Hill, D.E., Yeo, R.A., Campbell, R.A., Hart, B., Vigil, J., Brooks, W., 2003. Magnetic resonance imaging correlates of attention-deficit/hyperactivity disorder in children. *Neuropsychology* 17, 496–506.
- Hugenschmidt, C.E., Peiffer, A.M., Kraft, R.A., Casanova, R., Deibler, A.R., Burdette, J.H., Maldjian, J.A., Laurienti, P.J., 2008. Relating imaging indices of white matter integrity and volume in healthy older adults. *Cereb. Cortex* 18, 433–442.
- Hulshoff Pol, H.E., Schnack, H.G., Posthuma, D., Mandl, R.C., Baare, W.F., van Oel, C., van Haren, N.E., Collins, D.L., Evans, A.C., Amunts, K., Burgel, U., Zilles, K., de Geus, E., Boomsma, D.I., Kahn, R.S., 2006. Genetic contributions to human brain morphology and intelligence. *J. Neurosci.* 26, 10235–10242.
- Hynd, G.W., Semrud-Clikeman, M., Lorys, A.R., Novey, E.S., Eliopoulos, D., Lyytinen, H., 1991. Corpus callosum morphology in attention deficit-hyperactivity disorder: morphometric analysis of MRI. *J. Learn. Disabil.* 24, 141–146.
- Ingalhalikar, M., Parker, D., Bloy, L., Roberts, T.P., Verma, R., 2011. Diffusion based abnormality markers of pathology: toward learned diagnostic prediction of ASD. *Neuroimage* 57, 918–927.
- Jahanshad, N., Lee, A.D., Barysheva, M., McMahon, K.L., de Zubicaray, G.I., Martin, N.G., Wright, M.J., Toga, A.W., Thompson, P.M., 2010. Genetic influences on brain asymmetry: a DTI study of 374 twins and siblings. *Neuroimage* 52, 455–469.
- Kates, W.R., Frederikse, M., Mostofsky, S.H., Folley, B.S., Cooper, K., Mazur-Hopkins, P., Kofman, O., Singer, H.S., Denckla, M.B., Pearlson, G.D., Kaufmann, W.E., 2002. MRI parcellation of the frontal lobe in boys with attention deficit hyperactivity disorder or Tourette syndrome. *Psychiatry Res.* 116, 63–81.
- Kessler, R.C., Adler, L., Barkley, R., Biederman, J., Conners, C.K., Demler, O., Faraone, S.V., Greenhill, L.L., Howes, M.J., Secnik, K., Spencer, T., Ustun, T.B., Walters, E.E., Zaslavsky, A.M., 2006. The prevalence and correlates of adult ADHD in the United States: results from the National Comorbidity Survey Replication. *Am. J. Psychiatry* 163, 716–723.
- Kobel, M., Bechtel, N., Specht, K., Klarhofer, M., Weber, P., Scheffler, K., Opwis, K., Penner, I.K., 2010. Structural and functional imaging approaches in attention deficit/hyperactivity disorder: does the temporal lobe play a key role? *Psychiatry Res.* 183, 230–236.
- Konrad, A., Dielenheis, T.F., El Masri, D., Bayerl, M., Fehr, C., Gesierich, T., Vucurevic, G., Stoeter, P., Winterer, G., 2010. Disturbed structural connectivity is related to inattention and impulsivity in adult attention deficit hyperactivity disorder. *Eur. J. Neurosci.* 31, 912–919.
- Konrad, K., Eickhoff, S.B., 2010. Is the ADHD brain wired differently? A review on structural and functional connectivity in attention deficit hyperactivity disorder. *Hum. Brain Mapp.* 31, 904–916.
- Krain, A.L., Castellanos, F.X., 2006. Brain development and ADHD. *Clin. Psychol. Rev.* 26, 433–444.
- Laird, A.R., Fox, P.M., Price, C.J., Glahn, D.C., Uecker, A.M., Lancaster, J.L., Turkeltaub, P.E., Kochunov, P., Fox, P.T., 2005. ALE meta-analysis: controlling the false discovery rate and performing statistical contrasts. *Hum. Brain Mapp.* 25, 155–164.
- Lancaster, J.L., Tordesillas-Gutierrez, D., Martinez, M., Salinas, F., Evans, A., Zilles, K., Mazziotta, J.C., Fox, P.T., 2007. Bias between MNI and Talairach coordinates analyzed using the ICBM-152 brain template. *Hum. Brain Mapp.* 28, 1194–1205.
- Li, Q., Sun, J., Guo, L., Zang, Y., Feng, Z., Huang, X., Yang, H., Lv, Y., Huang, M., Gong, Q., 2010. Increased fractional anisotropy in white matter of the right frontal region in children with attention-deficit/hyperactivity disorder: a diffusion tensor imaging study. *Neuro Endocrinol. Lett.* 31, 747–753.
- Ling, J., Merideth, F., Caprihan, A., Pena, A., Teshiba, T., Mayer, A.R., 2011. Head injury or head motion? Assessment and quantification of motion artifacts in diffusion tensor imaging studies. 33, 50–62.
- Liston, C., Cohen, M.M., Teslovich, T., Levenson, D., Casey, B.J., 2011. Atypical prefrontal connectivity in attention-deficit/hyperactivity disorder: pathway to disease or pathological end point? *Biol. Psychiatry* 69, 1168–1177.
- Mackie, S., Shaw, P., Lenroot, R., Pierson, R., Greenstein, D.K., Nugent 3rd, T.F., Sharp, W.S., Giedd, J.N., Rapoport, J.L., 2007. Cerebellar development and

- clinical outcome in attention deficit hyperactivity disorder. *Am. J. Psychiatry* 164, 647–655.
- Makris, N., Biederman, J., Monuteaux, M.C., Seidman, L.J., 2009. Towards conceptualizing a neural systems-based anatomy of attention-deficit/hyperactivity disorder. *Dev. Neurosci.* 31, 36–49.
- Makris, N., Biederman, J., Valera, E.M., Bush, G., Kaiser, J., Kennedy, D.N., Caviness, V.S., Faraone, S.V., Seidman, L.J., 2007. Cortical thinning of the attention and executive function networks in adults with attention-deficit/hyperactivity disorder. *Cereb. Cortex* 17, 1364–1375.
- Makris, N., Buka, S.L., Biederman, J., Papadimitriou, G.M., Hodge, S.M., Valera, E.M., Brown, A.B., Bush, G., Monuteaux, M.C., Caviness, V.S., Kennedy, D.N., Seidman, L.J., 2008. Attention and executive systems abnormalities in adults with childhood ADHD: a DT-MRI study of connections. *Cereb. Cortex* 18, 1210–1220.
- Mandl, R.C., Schnack, H.G., Luigjes, J., van den Heuvel, M.P., Cahn, W., Kahn, R.S., Hulshoff Pol, H.E., 2010. Tract-based analysis of magnetization transfer ratio and diffusion tensor imaging of the frontal and frontotemporal connections in schizophrenia. *Schizophr. Bull.* 36, 778–787.
- McAlonan, G.M., Cheung, V., Cheung, C., Chua, S.E., Murphy, D.G., Suckling, J., Tai, K.S., Yip, L.K., Leung, P., Ho, T.P., 2007. Mapping brain structure in attention deficit-hyperactivity disorder: a voxel-based MRI study of regional grey and white matter volume. *Psychiatry Res.* 154, 171–180.
- Mintorovitch, J., Moseley, M., Chileuitt, L., Shimizu, H., Cohen, Y., Weinstein, P., 1991. Comparison of diffusion and T2 weighted MRI for the early detection of cerebral ischemia and reperfusion in rats. *Magn. Reson. Med.* 18, 39–50.
- Mori, S., Wakana, S., Van Zijl, P.C.M., 2004. *MRI Atlas of Human White Matter*, 1st ed. Elsevier, Amsterdam, The Netherlands; San Diego, CA.
- Moseley, M., Cohen, Y., Kucharczyk, J., Mintorovitch, J., Asgari, H., Wendland, M., Tsuruda, J., Norman, D., 1990. Diffusion-weighted MR imaging of anisotropic water diffusion in cat central nervous system. *Radiology* 176, 439.
- Mostofsky, S.H., Cooper, K.L., Kates, W.R., Denckla, M.B., Kaufmann, W.E., 2002. Smaller prefrontal and premotor volumes in boys with attention-deficit/hyperactivity disorder. *Biol. Psychiatry* 52, 785–794.
- Muller, U.C., Asherson, P., Banaschewski, T., Buitelaar, J.K., Ebstein, R.P., Eisenberg, J., Gill, M., Manor, I., Miranda, A., Oades, R.D., Roeyers, H., Rothenberger, A., Sergeant, J.A., Sonuga-Barke, E.J., Thompson, M., Faraone, S.V., Steinhausen, H.C., 2011. The impact of study design and diagnostic approach in a large multi-centre ADHD study. Part 2: dimensional measures of psychopathology and intelligence. *BMC Psychiatry* 11, 55.
- Nagel, B.J., Bathula, D., Herting, M., Schmitt, C., Kroenke, C.D., Fair, D., Nigg, J.T., 2011. Altered white matter microstructure in children with attention-deficit/hyperactivity disorder. *J. Am. Acad. Child Adolesc. Psychiatry* 50, 283–292.
- Narr, K.L., Woods, R.P., Lin, J., Kim, J., Phillips, O.R., Del'Homme, M., Caplan, R., Toga, A.W., McCracken, J.T., Levitt, J.G., 2009. Widespread cortical thinning is a robust anatomical marker for attention-deficit/hyperactivity disorder. *J. Am. Acad. Child Adolesc. Psychiatry* 48, 1014–1022.
- Nichols, T., Hayasaka, S., 2003. Controlling the familywise error rate in functional neuroimaging: a comparative review. *Stat. Methods Med. Res.* 12, 419–446.
- Pavuluri, M.N., Yang, S., Kamineni, K., Passarotti, A.M., Srinivasan, G., Harral, E.M., Sweeney, J.A., Zhou, X.J., 2009. Diffusion tensor imaging study of white matter fiber tracts in pediatric bipolar disorder and attention-deficit/hyperactivity disorder. *Biol. Psychiatry* 65, 586–593.
- Peterson, B.S., 2003. Conceptual, methodological, and statistical challenges in brain imaging studies of developmentally based psychopathologies. *Dev. Psychopathol.* 15, 811–832.
- Peterson, D.J., Ryan, M., Rimrodt, S.L., Cutting, L.E., Denckla, M.B., Kaufmann, W.E., Mahone, E.M., 2011. Increased regional fractional anisotropy in highly screened attention-deficit hyperactivity disorder (ADHD). *J. Child Neurol.* 26, 1296–1302.
- Pfefferbaum, A., Sullivan, E.V., Carmelli, D., 2001. Genetic regulation of regional microstructure of the corpus callosum in late life. *Neuroreport* 12, 1677–1681.
- Poelmans, G., Pauls, D.L., Buitelaar, J.K., Franke, B., 2011. Integrated genome-wide association study findings: identification of a neurodevelopmental network for attention deficit hyperactivity disorder. *Am. J. Psychiatry* 168, 365–377.
- Qiu, M.G., Ye, Z., Li, Q.Y., Liu, G.J., Xie, B., Wang, J., 2010. Changes of brain structure and function in ADHD children. *Brain Topogr.* 24, 243–252.
- Rohde, G.K., Barnett, A.S., Bassar, P.J., Marengo, S., Pierpaoli, C., 2004. Comprehensive approach for correction of motion and distortion in diffusion-weighted MRI. *Magn. Reson. Med.* 51, 103–114.
- Sage, C.A., Van Hecke, W., Peeters, R., Sijbers, J., Robberecht, W., Parizel, P., Marchal, G., Leemans, A., Sunaert, S., 2009. Quantitative diffusion tensor imaging in amyotrophic lateral sclerosis: revisited. *Hum. Brain Mapp.* 30, 3657–3675.
- Seidman, L.J., Valera, E.M., Makris, N., 2005. Structural brain imaging of attention-deficit/hyperactivity disorder. *Biol. Psychiatry* 57, 1263–1272.
- Seidman, L.J., Valera, E.M., Makris, N., Monuteaux, M.C., Boriell, D.L., Kelkar, K., Kennedy, D.N., Caviness, V.S., Bush, G., Alcardi, M., Faraone, S.V., Biederman, J., 2006. Dorsolateral prefrontal and anterior cingulate cortex volumetric abnormalities in adults with attention-deficit/hyperactivity disorder identified by magnetic resonance imaging. *Biol. Psychiatry* 60, 1071–1080.
- Shaw, P., Eckstrand, K., Sharp, W., Blumenthal, J., Lerch, J.P., Greenstein, D., Clasen, L., Evans, A., Giedd, J., Rapoport, J.L., 2007. Attention-deficit/hyperactivity disorder is characterized by a delay in cortical maturation. *Proc. Natl. Acad. Sci. U.S.A.* 104, 19649–19654.
- Shaw, P., Lalonde, F., Lepage, C., Rabin, C., Eckstrand, K., Sharp, W., Greenstein, D., Evans, A., Giedd, J.N., Rapoport, J., 2009. Development of cortical asymmetry in typically developing children and its disruption in attention-deficit/hyperactivity disorder. *Arch. Gen. Psychiatry* 66, 888–896.
- Shaw, P., Lerch, J., Greenstein, D., Sharp, W., Clasen, L., Evans, A., Giedd, J., Castellanos, F.X., Rapoport, J., 2006. Longitudinal mapping of cortical thickness and clinical outcome in children and adolescents with attention-deficit/hyperactivity disorder. *Arch. Gen. Psychiatry* 63, 540–549.
- Silk, T.J., Vance, A., Rinehart, N., Bradshaw, J.L., Cunnington, R., 2009a. Structural development of the basal ganglia in attention deficit hyperactivity disorder: a diffusion tensor imaging study. *Psychiatry Res.* 172, 220–225.
- Silk, T.J., Vance, A., Rinehart, N., Bradshaw, J.L., Cunnington, R., 2009b. White-matter abnormalities in attention deficit hyperactivity disorder: a diffusion tensor imaging study. *Hum. Brain Mapp.* 30, 2757–2765.
- Smith, S.M., Jenkinson, M., Johansen-Berg, H., Rueckert, D., Nichols, T.E., Mackay, C.E., Watkins, K.E., Ciccarelli, O., Cader, M.Z., Matthews, P.M., Behrens, T.E., 2006. Tract-based spatial statistics: voxelwise analysis of multi-subject diffusion data. *Neuroimage* 31, 1487–1505.
- Song, S.K., Sun, S.W., Ramsbottom, M.J., Chang, C., Russell, J., Cross, A.H., 2002. Demyelination revealed through MRI as increased radial (but unchanged axial) diffusion of water. *Neuroimage* 17, 1429–1436.
- Sowell, E.R., Thompson, P.M., Welcome, S.E., Henkenius, A.L., Toga, A.W., Peterson, B.S., 2003. Cortical abnormalities in children and adolescents with attention-deficit hyperactivity disorder. *Lancet* 362, 1699–1707.
- Suzuki, Y., Matsuzawa, H., Kwee, I.L., Nakada, T., 2003. Absolute eigenvalue diffusion tensor analysis for human brain maturation. *NMR Biomed.* 16, 257–260.
- Tievsky, A.L., Ptak, T., Farkas, J., 1999. Investigation of Apparent Diffusion Coefficient and diffusion tensor anisotropy in acute and chronic multiple sclerosis lesions. *AJNR Am. J. Neuroradiol.* 20, 1491–1499.
- Tijssen, R.H.N., Jansen, J.F.A., Backes, W.H., 2009. Assessing and minimizing the effects of noise and motion in clinical DTI at 3T. *Hum. Brain Mapp.* 30, 2641–2655.
- Turkeltaub, P.E., Eden, G.F., Jones, K.M., Zeffiro, T.A., 2002. Meta-analysis of the functional neuroanatomy of single-word reading: method and validation. *Neuroimage* 16, 765–780.
- Valera, E.M., Faraone, S.V., Murray, K.E., Seidman, L.J., 2007. Meta-analysis of structural imaging findings in attention-deficit/hyperactivity disorder. *Biol. Psychiatry* 61, 1361–1369.
- Valo, S., Tannock, R., 2010. Diagnostic instability of DSM-IV ADHD subtypes: effects of informant source, instrumentation, and methods for combining symptom reports. *J. Clin. Child Adolesc. Psychol.* 39, 749–760.
- Van Hecke, W., Leemans, A., Sage, C.A., Emsell, L., Veraart, J., Sijbers, J., Sunaert, S., Parizel, P.M., 2011. The effect of template selection on diffusion tensor voxel-based analysis results. *Neuroimage* 55, 566–573.
- Wakana, S., Jiang, H., Nagae-Poetscher, L.M., van Zijl, P.C., Mori, S., 2004. Fiber tract-based atlas of human white matter anatomy. *Radiology* 230, 77–87.
- Wolosin, S.M., Richardson, M.E., Hennessey, J.G., Denckla, M.B., Mostofsky, S.H., 2009. Abnormal cerebral cortex structure in children with ADHD. *Hum. Brain Mapp.* 30, 175–184.
- Wozniak, J.R., Lim, K.O., 2006. Advances in white matter imaging: a review of in vivo magnetic resonance methodologies and their applicability to the study of development and aging. *Neurosci. Biobehav. Rev.* 30, 762–774.
- Zhang, H., Avants, B.B., Yushkevich, P.A., Woo, J.H., Wang, S., McCluskey, L.F., Elman, L.B., Melhem, E.R., Gee, J.C., 2007. High-dimensional spatial normalization of diffusion tensor images improves the detection of white matter differences: an example study using amyotrophic lateral sclerosis. *IEEE Trans. Med. Imaging* 26, 1585–1597.
- Zhou, X.J., Leeds, N.E., 2005. Assessing glioma cell infiltration using a fiber coherence index: a DTI study. *Proc. Int. Soc. Magn. Reson. Med.* 13, 365.