

# Topical Ganciclovir for the Treatment of Adenovirus Conjunctivitis

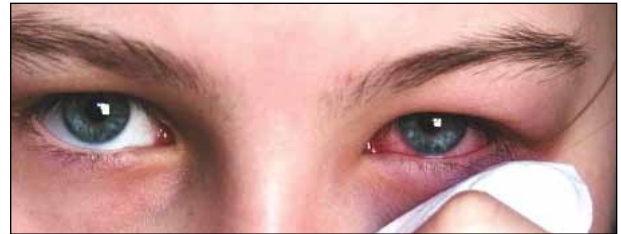If effective, topical ganciclovir treatment could limit the duration of adenoviral shedding, the development of corneal infiltrates, and the disease's spreading to the second eye.

BY JAY S. PEPOSE, MD, PhD

Patients with acute conjunctivitis commonly present to eye care professionals, pediatricians, emergency department doctors, internists, and family practice physicians. It is estimated that there are 6 to 7 million cases of acute conjunctivitis in the United States annually, representing around 1% to 2% of all office visits.

Adenoviruses are the most common cause of ocular viral infection worldwide,<sup>1,2</sup> and it is the virus type most frequently isolated from the conjunctiva.<sup>3</sup> Adenoviral conjunctivitis and keratoconjunctivitis are highly contagious and associated with significant morbidity and health care costs. Adenovirus is a nonenveloped, double-stranded DNA virus with 53 serotypes; therefore, a person's infection with one serotype may not necessarily provide immunity to another. Unlike many viruses, which are enveloped and thereby more easily inactivated (eg, herpes simplex virus [HSV], HIV), adenoviruses are quite resistant to disinfection and are long-lasting for weeks on common fomites such as towels and doorknobs.

The ocular infection generally begins unilaterally and, in many cases, spreads to both eyes. It may cause epidemics and endemics, and it is most commonly spread in the summer or winter. Epidemics are common in day care centers, schools, and the military and have been spread in the offices of eye care professionals via tonometers and other sources. Ocular viral shedding has been reported for up to 16 days. Hand-to-eye and airborne droplet infection are common means of trans-

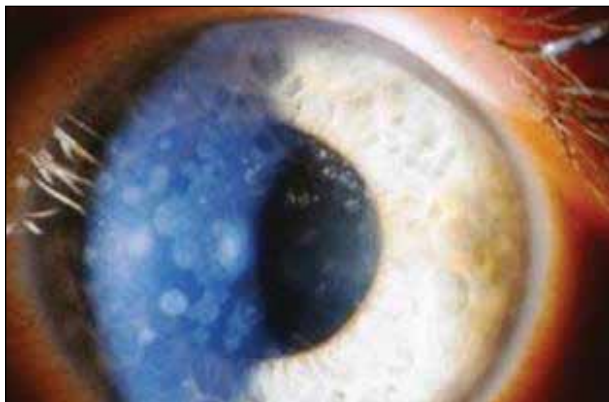


**Figure 1.** Patients with adenoviral conjunctivitis often presents with lid swelling, follicular conjunctivitis, and epiphora.

mission. Frequent hand washing, appropriate hygiene, and disinfection of fomites may help to control transmission. Recently, the US military has restarted oral vaccination against adenoviral serotypes 4 and 7 in an effort to limit respiratory spread in barracks and training facilities. Currently, however, there is no Food and Drug Administration-approved topical anti-adenoviral therapy.

## CLINICAL FEATURES

Approximately one-third of the 53 adenoviral serotypes have been isolated from cases of conjunctivitis. There are four major presentations of ocular adenovirus infection: follicular conjunctivitis (predominantly serotypes 1-11, 19); epidemic keratoconjunctivitis (predominantly serotypes 8, 19, 37, 53); acute hemorrhagic conjunctivitis (mostly serotypes 11, 19, 37); and pharyngeal conjunctival fever (mostly serotypes 3, 4, 7a, 11).



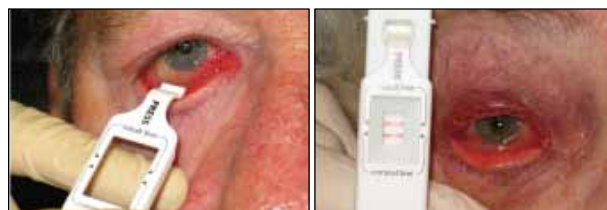**Figure 2.** Corneal infiltrates are a later finding and can be associated with photophobia, decreased BCVA, and irregular astigmatism.

Patients may develop lid swelling (Figure 1), conjunctival injection, painful conjunctival membranes, and palpable preauricular adenopathy. Subsequent subepithelial corneal infiltrates (Figure 2) can cause light sensitivity, reduced vision, and lead to irregular astigmatism. The differential diagnosis includes ocular herpes simplex, chlamydia, and enterovirus infection.

In considering the differential diagnosis of follicular conjunctivitis, it is important to appreciate that about 20% of acute follicular conjunctivitis is due to HSV. HSV conjunctivitis is less likely to have accompanying lymphadenopathy, conjunctival scarring, or pseudomembranes than adenoviral conjunctivitis. Corneal lesions with HSV generally occur earlier in onset than with adenovirus. Unlike adenoviral ocular disease, there is no seasonal component. HSV may have accompanying orofacial or lid vesicles, especially in atopic patients. Even if HSV keratoconjunctivitis is misdiagnosed as adenovirus, HSV is generally responsive to topical ganciclovir, which may represent a potential advantage if studies demonstrate clinical antiadenoviral efficacy.

### **RATIONALE FOR A CLINICAL STUDY OF TOPICAL GANCICLOVIR FOR ADENOVIRAL KERATOCONJUNCTIVITIS**

There are supporting laboratory and clinical data to warrant a clinical trial of topical ganciclovir for the treatment of patients with adenoviral keratoconjunctivitis. Several studies have shown that ganciclovir is active in vitro against adenovirus.<sup>4,5</sup> Animal studies in the cotton rat have also shown some efficacy.<sup>6</sup> In addition, Tabbara<sup>7</sup> performed a controlled, randomized, double-masked clinical study of patients with adenovirus keratoconjunctivitis and found that ganciclovir significantly reduced both the duration of disease and



**Figure 3.** The Adeno Detector Plus (Rapid Pathogen Screening) immunoassay has a self-contained collection unit to perform conjunctival scrapings for in-office detection of adenoviral antigens in approximately 10 minutes.

the incidence of subepithelial infiltrates. In this masked study of 18 patients, 0.15% ganciclovir gel (Zirgan, Bausch + Lomb) was compared with preservative-free artificial tears as a control. The investigators found that the mean time of adenovirus shedding was significantly shorter for ganciclovir-treated patients at 7.7 days in contrast to 18.5 days for those receiving artificial tears ( $P < .05$ ). In addition, subepithelial opacities developed in seven (77%) patients treated with artificial tears compared with two (22%) patients in the ganciclovir-treated group.

### **STUDY OBJECTIVES**

The purpose of the current study is to evaluate the safety and efficacy of 0.15% ganciclovir gel in patients with adenoviral keratoconjunctivitis compared with 0.3% hypromellose gel (Genteal, Novartis) used as a control. The primary outcome of the study is to determine whether topical 0.15% ganciclovir gel alone will reduce the duration of viral shedding from the ocular surface, as determined by quantitative viral isolation in A549 cell tissue culture, compared with the control 0.3% hypromellose gel.

The secondary outcomes of the study are whether topical 0.15% ganciclovir will (1) reduce the incidence and severity of second eye involvement, (2) reduce the incidence and severity of subepithelial infiltrates, (3) reduce the secondary spread to family members, friends, classmates or coworkers, (4) reduce the degree of bulbar conjunctival injection, (5) reduce ocular discomfort, and (6) be considered an effective treatment by patients.

### **INCLUSION CRITERIA AND STUDY SITES**

Because our goal is to test the antiviral effects of ganciclovir against adenovirus replication and shedding, the study is designed to capture patients early in the course of disease before the viral load is naturally declining, which may obfuscate the analysis. The inclusion criteria for the study is the presence of follicular conjunctivitis for 72 hours or less in individuals

who test positive on the Adeno Detector Plus (Rapid Pathogen Screening, Inc.) immunoassay for adenoviral antigens, which is described later. In an effort to exclude other forms of conjunctivitis, patients with a mucopurulent discharge, history of HSV conjunctivitis, or allergic conjunctivitis are not eligible for enrollment.

There are 10 US study sites, two international sites, and a coordinating center where untreated patients can be referred for free care and study medications.

### POINT OF SERVICE IN-OFFICE ASSAY FOR ADENOVIRAL CONJUNCTIVITIS

Clinical studies of conjunctivitis with laboratory confirmation indicate that it is often difficult to differentiate bacterial from viral forms of acute conjunctivitis by relying on signs or symptoms or both.<sup>8</sup> For that reason, this study utilizes a rapid immunoassay applied to conjunctival scrapings (Figure 3) that can be performed in the lane and processed by a technician. The RPS Adeno Detector Plus is a point-of-care immunoassay that has 93% sensitivity and 96% specificity. It takes approximately 10 minutes for results. The monoclonal antibodies used in the assay detect all 53 adenoviral serotypes. The device has a self-contained element used for conjunctival scraping and a binary "yes/no" readout similar to urine pregnancy tests. This assay is FDA 510(k) cleared, has a Clinical Laboratory Improvement Amendments, or CLIA, waiver, and is commercially available. It also has a unique Medicare Current Procedural Terminology or CPT code 87809qw, which more than covers the cost of the test kit.

### ROLE OF ANTIVIRAL VERSUS ANTI-INFLAMMATORY MEDICATIONS

The pathogenesis of adenoviral keratoconjunctivitis includes an early phase of viral replication followed by a host immune reaction. In some animal studies,<sup>9,10</sup> the use of a topical steroid alone resulted in prolonged adenoviral shedding, suggesting cautious, judicious use of topical steroids without antiviral coverage. Although immunity plays an important role in limiting the duration of adenoviral conjunctivitis and often leads to lesser involvement in the contralesional eye, exuberant immune responses can result in permanent structural or sight-threatening complications. Severe adenoviral conjunctivitis with formation of membranes or pseudomembranes may result in permanent scarring, and corneal subepithelial infiltrates can result in a loss of one or more lines of BCVA. If these findings are observed in the study, the ophthalmologist has the discretion of adding topical 0.5% loteprednol etabonate suspension (Lotemax, Bausch + Lomb) qid to their study medica-

tion, with tapering as per clinical course at the specialist's discretion, to serve as a rescue medication and reduce the inflammatory response.

Other ongoing antiviral studies include a new formulation of 0.4% povidone-iodine/0.1% dexamethasone (Foresight Biotherapeutics), which has proven efficacious in a rabbit model of adenoviral keratoconjunctivitis.<sup>11</sup> It will be interesting to determine whether the antiseptic action of this compound will inactivate only extracellular adenovirus or also intracellular forms of adenovirus, both of which may be important and necessary in controlling the life cycle of viral replication.

### GOALS OF TREATMENT WITH GANCICLOVIR

If proven effective, the goal of topical ganciclovir treatment is to limit the duration of adenoviral shedding, the development of corneal infiltrates (which can result in irregular astigmatism, glare, photophobia, and hyperopic shifts), and spreading to the second eye. Additional goals are to prevent the spread of disease by early and accurate diagnosis and treatment, to reduce the cost of lost days at work and school, to afford specific antiviral treatment, and to avoid the over-prescription of unnecessary, ineffective antibiotics. Accurate diagnosis and appropriate antiviral rather than antibacterial therapy should reduce the cost of treatment and diminish the development of antibiotic-associated allergies and toxicities. ■

*Jay S. Pepose, MD, PhD, is the director of the Pepose Vision Institute and a professor of clinical ophthalmology and visual sciences at the Washington University School of Medicine in St. Louis. He is a consultant to Bausch + Lomb. Dr. Pepose may be reached at (636) 728-0111; jpepose@peposevision.com.*



1. Aoki K, Kaneko H, Nobuyoshi Kitaichi N, et al. Clinical features of adenoviral conjunctivitis at the early stage of infection. *Jpn J Ophthalmol*. 2011;55:11-15.
2. Waka Saitoh-Inagawa W, Aoki K, Uchio E, et al. Ten years' surveillance of viral conjunctivitis in Sapporo, Japan. *Graefes Arch Clin Exper Ophthalmol*. 1999;237:35-38.
3. Marangon FB, Miller D, Alfonso E. Laboratory results in ocular viral diseases: implications in clinical-laboratory correlation. *Arq Bras Oftalmol*. 2007;70:189-194.
4. Naesens L, Lenaerts L, Andrei G, et al. Antiadenovirus activities of several classes of nucleoside and nucleotide analogues. *Antimicrob Agents Chemother*. 2005;49:1010-1016.
5. Crumacker CS. Ganciclovir. *N Engl J Med*. 1996;335:721-729.
6. Trousdale MD, Goldschmidt PL, Nóbrega R. Activity of ganciclovir against human adenovirus type-5 infection in cell culture and cotton rat eyes. *Cornea*. 1994;13:435-439.
7. Tabbara K, Jarade E. Ganciclovir effects in adenoviral keratoconjunctivitis. *Invest Ophthalmol Vis Sci*. 2001;3111 (suppl);S579.
8. Rietveld RP, van Weert HC, ter Riet G, Bindels PJ. Diagnostic impact of signs and symptoms in acute infectious conjunctivitis: systematic literature search. *BMJ*. 2003;327:789.
9. Romanowski EG, Yates KA, Gordon YJ. Topical corticosteroids of limited potency promote adenovirus replication in the Ad5/NZW rabbit ocular model. *Cornea*. 2002;21:289-291.
10. Romanowski EG, Yates KA, Gordon YJ. Short-term treatment with a potent topical corticosteroid on an acute ocular adenoviral infection in the New Zealand white rabbit. *Cornea*. 2001;20:657-660.
11. Clement C, Capriotti JA, Kumar M, et al. Clinical and antiviral efficacy of an ophthalmic formulation of dexamethasone povidone-iodine in a rabbit model of adenoviral keratoconjunctivitis. *Invest Ophthalmol Vis Sci*. 2011;52:339-44.