

Medial Pedicle Reduction Mammoplasty for Severe Mammary Hypertrophy

Maurice Y. Nahabedian, M.D., Bernard M. McGibbon, M.D., and Paul N. Manson, M.D.

Baltimore, Md.

Current options in reduction mammoplasty for severe mammary hypertrophy include amputation with free-nipple graft as well as the inferior pedicle and bipedicle techniques. Complications of these procedures include nipple-areola necrosis, insensitivity, and hypopigmentation. The purpose of this study was to determine whether medial pedicle reduction mammoplasty can minimize these complications. Twenty-three patients with severe mammary hypertrophy were studied. The medial pedicle successfully transposed the nipple-areola complex in 44 of 45 breasts (98 percent). Mean change in nipple position was 17.1 cm, and mean weight of tissue removed was 1604 g per breast. Nipple-areola sensation was retained in 43 of 44 breasts (98 percent) using a medial pedicle. Hypopigmentation was not observed, and central breast projection was restored in all patients. This study has demonstrated that medial pedicle reduction mammoplasty is a safe and reliable technique and should be given primary consideration in cases of severe mammary hypertrophy. (*Plast. Reconstr. Surg.* 105: 896, 2000.)

Management of severe mammary hypertrophy continues to be optimized. Common surgical options for reduction mammoplasty include amputation with free-nipple graft as well as the bipedicle and inferior pedicle techniques. All three methods are used extensively; however, there are disadvantages to each when used for severe mammary hypertrophy. Disadvantages include reduced nipple sensation, nipple-areola necrosis, hypopigmentation, and poor breast projection.¹⁻³ This study describes a new technique of reduction mammoplasty using a medially based dermal pedicle for nipple-areola transposition that effectively eliminates these complications.

The principle of the medial pedicle is derived from the superomedial technique of reduction mammoplasty described by Orlando and Guthrie.⁴ The superomedial pedicle was designed to shorten pedicle length and

broaden pedicle width as a means of enhancing blood flow and maintaining innervation to the nipple-areola complex. Numerous studies have demonstrated that the superomedial pedicle is effective in the management of mild to moderate mammary hypertrophy; however, it has not been used for severe mammary hypertrophy.⁴⁻⁷ Possible reasons include excessive pedicle length as well as torsion, twisting, and compression of the pedicle because of its limited arc of rotation.^{6,8} To eliminate this possibility, the medial pedicle was designed with a narrower base and no superior attachment, thus permitting a wider arc of rotation. This modification effectively eliminates pedicle-related complications while maintaining the advantages of the superomedial pedicle.

The purpose of this study was to assess whether medial pedicle reduction mammoplasty is as effective as inferior pedicle reduction mammoplasty and amputation mammoplasty with free-nipple graft. Attention will focus on viability and sensation of the nipple-areola complex as well as projection of the nipple and breast.

PATIENTS AND METHODS

Patients

Twenty-three patients with severe mammary hypertrophy underwent medial pedicle reduction mammoplasty between June of 1996 and December of 1998. Definitions of severe mammary hypertrophy are varied and include cup size, weight of resected breast tissue, and height of nipple elevation.⁹⁻¹¹ Inclusion for this study required a minimum distance from the nipple to the inframammary fold of 16 cm. Bilateral gigantomastia was present in 22 pa-

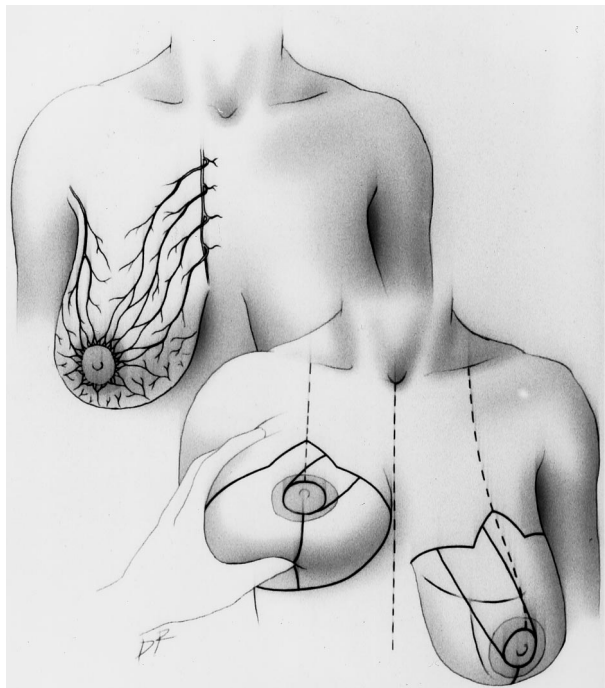


FIG. 1. (Above) The dominant internal mammary perforating vessels to the breast and nipple-areola complex. (Below) The Wise pattern and the medial pedicle.

tients and unilateral gigantomastia in 1 patient following right mastectomy for cancer. Mean age was 31 years (range, 18 to 54 years). Mean weight was 188 pounds (range, 150 to 252 pounds). Mean height was 5 feet 6 inches (range, 4 feet 10 inches to 5 feet 9 inches). Bra cup size was DD or greater in all patients. Neck

pain, back pain, and bra strap indentations were reported by all patients.

Breast measurements were obtained with the patient standing. Mean distance from the sternal notch to the nipple was 38.4 cm on the right (range, 29 to 42 cm) and 38.5 cm on the left (range, 30 to 44 cm). Mean distance from the nipple to the inframammary fold was 19.9 cm bilaterally (range, 16 to 24 cm). Mean base width of the breast was 27.1 cm on the right (range, 21 to 34 cm) and 27.8 cm on the left (range, 22 to 34 cm). The new nipple was positioned at a mean of 21.4 cm (range, 20 to 22 cm) from the sternal notch along the breast meridian. The mean change in nipple position was 17.1 cm (range, 12 to 22 cm).

Preoperative Markings

A modified Wise pattern is delineated on the breast with the patient standing (Fig. 1). The new nipple position is marked at the level of the inframammary fold along the breast meridian. The vertical limbs of the Wise pattern are 8 cm in length.

In the operating room with the patient supine, the areolar diameter is marked at 4.2 cm. The medial pedicle is defined with the base of the pedicle oriented medially, such that one-third of the total base width is along the medial vertical limb and two-thirds of the width is along the medial horizontal limb (Fig. 1). Mean base width of the medial pedicle was 9.4

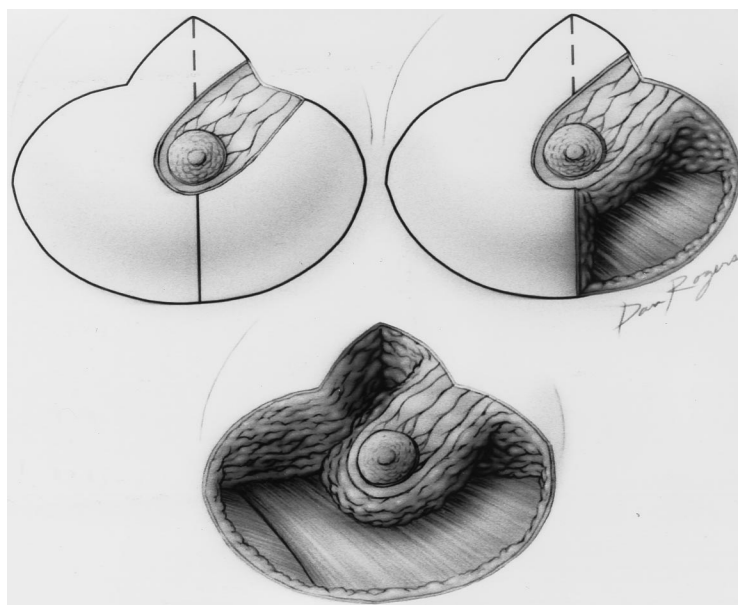


FIG. 2. (Above, left) The deepithelialized medial pedicle. (Above, right) Medial dermoglandular quadrant resection. (Below) Remaining dermoglandular segments are excised.

cm (range, 6 to 11 cm), and mean distance from the base to nipple was 14.8 cm (range, 10 to 19 cm). The distal aspect of the medial pedicle is delineated with a 1-cm margin around the nipple-areola complex to preserve the vascular plexus.

Technique

Local vasoconstriction is obtained by first infiltrating 0.25% lidocaine with epinephrine 1:200,000 along the proposed incisions (excluding the base of the medial pedicle). The medial pedicle is deepithelialized, leaving the nipple-areola complex intact (Fig. 2). Dermoglandular wedge excisions of the medial, inferior, lateral, and superolateral portions are performed. The attachments of the medial pedicle to the chest wall are maintained. Excising the lateral aspects of the pedicle facilitates pedicle rotation and positioning. The presence of bleeding is assessed at the distal aspect of the pedicle. Absence of bleeding necessitates conversion to a free-nipple graft. A temporary trifurcation suture is placed approximating the inferior corner of the medial and lateral vertical limbs of the Wise pattern to a predetermined point on the inferior horizontal limb of the Wise pattern (Fig. 3). The nipple-areola complex is rotated superiorly toward the apex of the vertical limbs. Twisting or kinking of the pedicle is avoided. The skin edges are stapled temporarily, and the patient is positioned upright to assess breast symmetry, fullness, and nipple position. The nipple-areola complex is exteriorized with its base at 4.5 cm above the inframammary fold. A single drain is placed, and the incisions are closed with interrupted dermal and continuous subcuticular sutures.

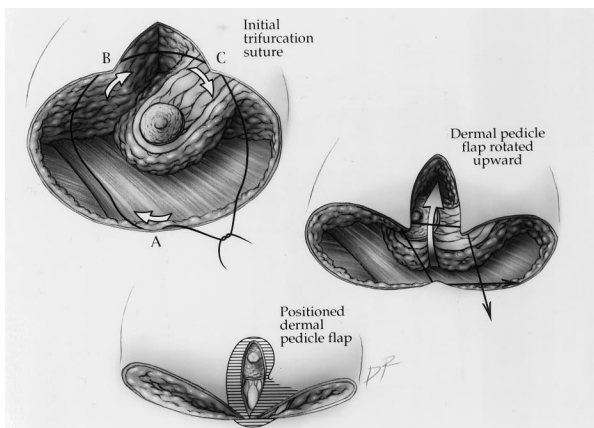


FIG. 3. (A) Trifurcation suture placement. (B) Medial dermal pedicle rotates superiorly. (C) Medial dermal pedicle positioned and suture ligated.

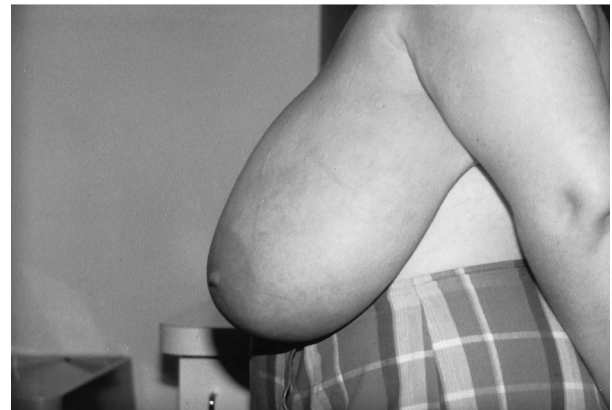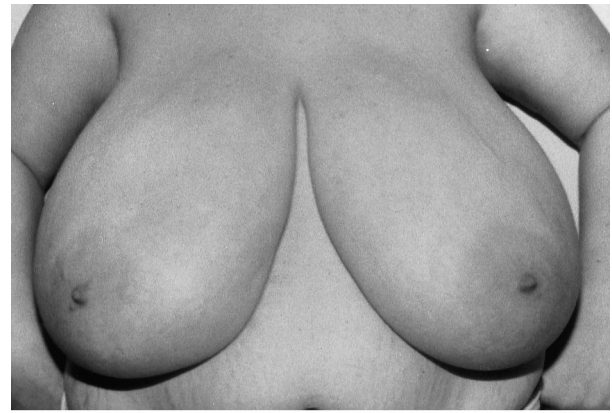


FIG. 4. (Above) Severe mammary hypertrophy with patient standing. (Below) Lateral view.

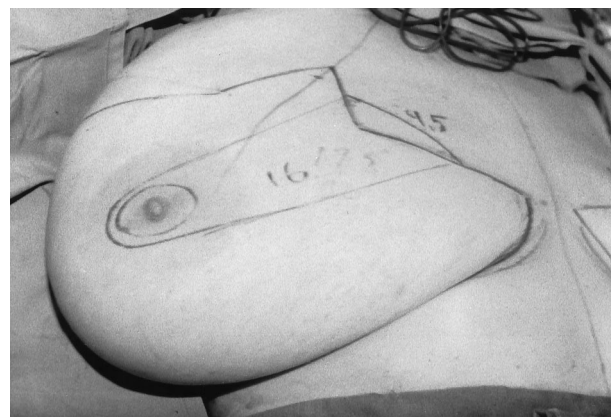


FIG. 5. Medial pedicle is delineated with patient supine. Length is 16 cm and base is 9.5 cm.

RESULTS

Reduction mammoplasty via nipple-areola transposition with a medial pedicle was attempted on 45 breasts and completed on 44 (98 percent). Free-nipple graft was necessary on one breast owing to absence of bleeding at the distal pedicle. Nipple-areola viability was maintained in all breasts following both the nipple-areola transposition and free-graft techniques. Sensation was retained in 43 of 44

breasts (98 percent) following medial pedicle reduction mammoplasty. This was assessed by light touch and patient response. Sensation did not return in the nipple-areola complex following free graft.

Mean weight of breast removed was 1580 g on the right (range, 930 to 2580 g) and 1627 g on the left (range, 970 to 2530 g). The free-nipple graft was necessary following excision of 2530 g in a breast with a medial pedicle length of 18 cm. No pedicle became kinked or twisted following rotation and positioning. Nipple-areola hypopigmentation was not observed. Breast and nipple projection was restored in all patients.

Patient satisfaction following this procedure was high. All patients reported relief of neck pain, back pain, and bra strap indentations. Loss of nipple sensation in the two patients (two breasts) was not of special concern. All patients were satisfied with nipple projection, and 22 of 23 patients reported satisfaction with breast shape. A "boxy" breast shape was noted in one patient (two breasts) requiring revision

that consisted of excising the redundant skin and fat along the medial inframammary incision.

Patient Profile

A 29-year-old woman with neck pain, back pain, and bra strap indentations was evaluated (Fig. 4). Bra size was 48 DDD, pregnancy status was gravida 2 and para 2, body weight was 220 pounds, and height was 5 feet 9 inches.

Initial marks and measurements were made with the patient standing. The sternal notch to nipple distance was 41 cm bilaterally, and the nipple to inframammary fold (inferior pedicle) distance was 26 cm bilaterally. Base width of the breast was 30 cm on the left and 29 cm on the right. The new nipple position was marked at 22 cm from the sternal notch, and the change in nipple position measured 19 cm. A modified Wise pattern was completed. Medial pedicle length with the patient standing was 18 cm bilaterally.

Secondary marks and measurements were made with the patient supine. The medial

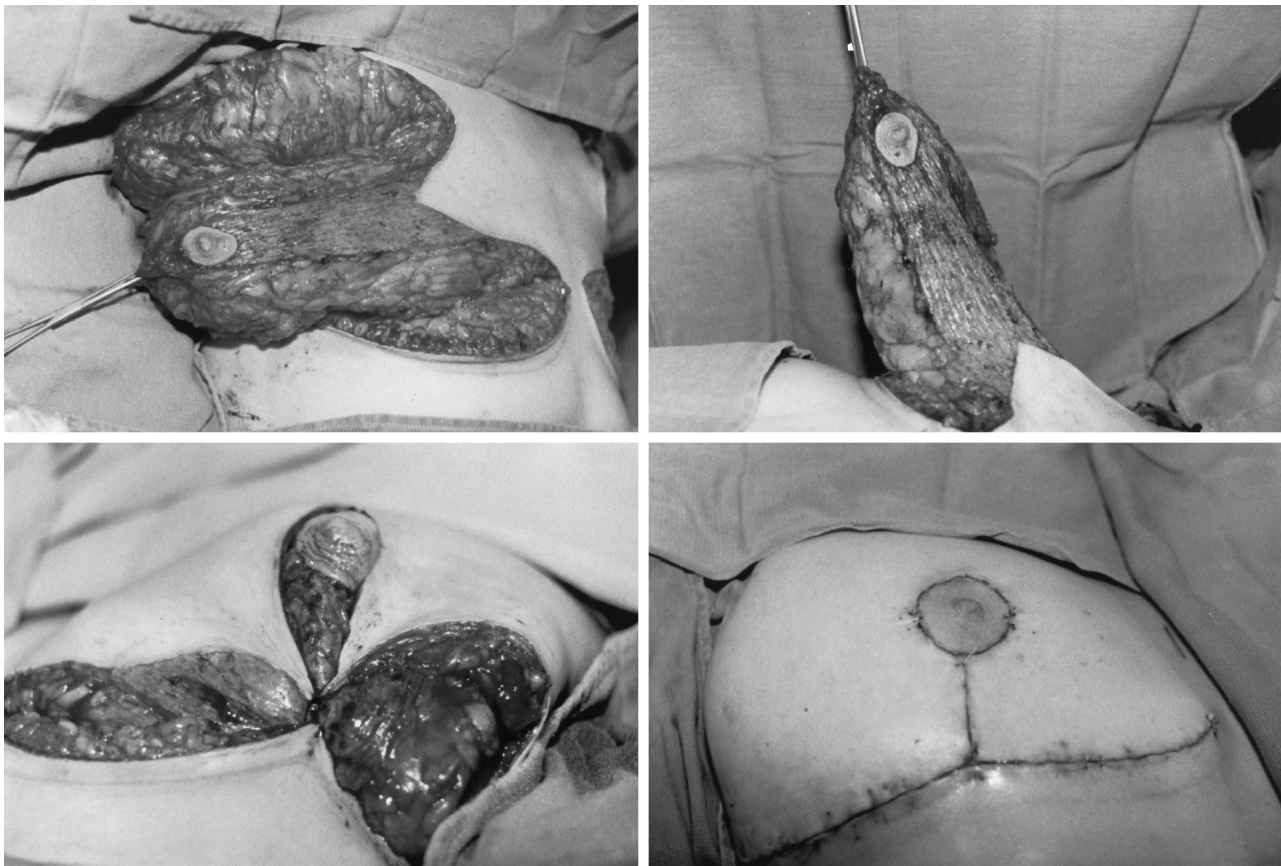


FIG. 6. (Above, left) Medial pedicle is deepithelialized and the dermoglandular excisions are completed. (Above, right) Medial pedicle is elevated. Bleeding is present at the distal edge. (Below, left) Medial pedicle is positioned and the trifurcation suture is ligated. (Below, right) The incisions are closed with a subcuticular suture. The nipple is pink and viable following the procedure.

pedicles were delineated and measured 9.5 cm at the base and 16 cm in length bilaterally (Fig. 5). The nipple to inframammary fold (inferior pedicle) distance measured 20 cm on the right and 21 cm on the left.

The operative technique is depicted in Figure 6. Postoperatively, the nipple-areola complex has remained viable and sensate bilaterally. The patient was pleased with breast shape and projection at the 2-month and 6-month follow-up evaluations (Figs. 7 and 8). Preoperative symptoms have resolved. Additional patients following medial pedicle reduction mammoplasty are illustrated in Figures 9 through 12.

DISCUSSION

This study demonstrates that medial pedicle reduction mammoplasty is a safe surgical option for severe mammary hypertrophy. Current options include amputation mammoplasty with free-nipple graft and the inferior pedicle and bipedicle techniques. The complications of these techniques, particularly the techniques with long pedicles, have led to a search for alternatives that would preserve the nipple and

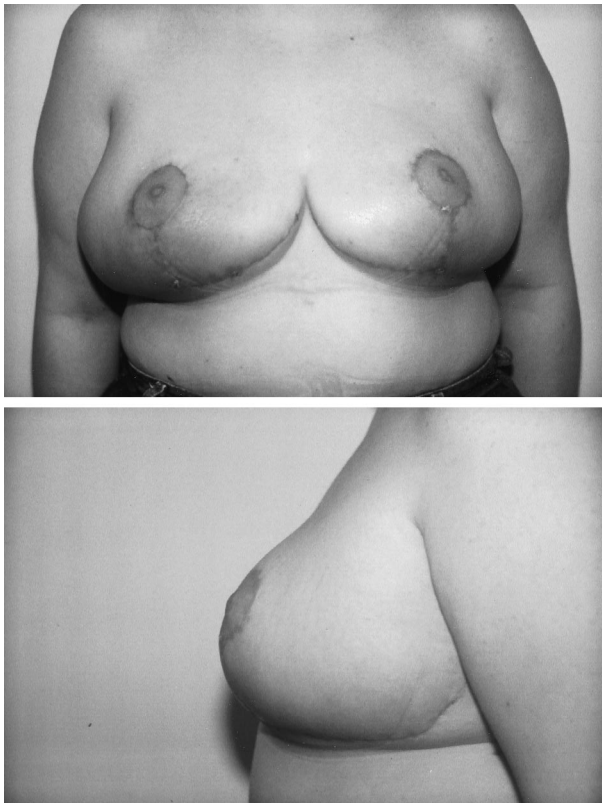


FIG. 7. (Above) The nipple-areola complex is viable and sensate at the 2-month follow-up. (Below) Lateral view demonstrating central projection of the breast.

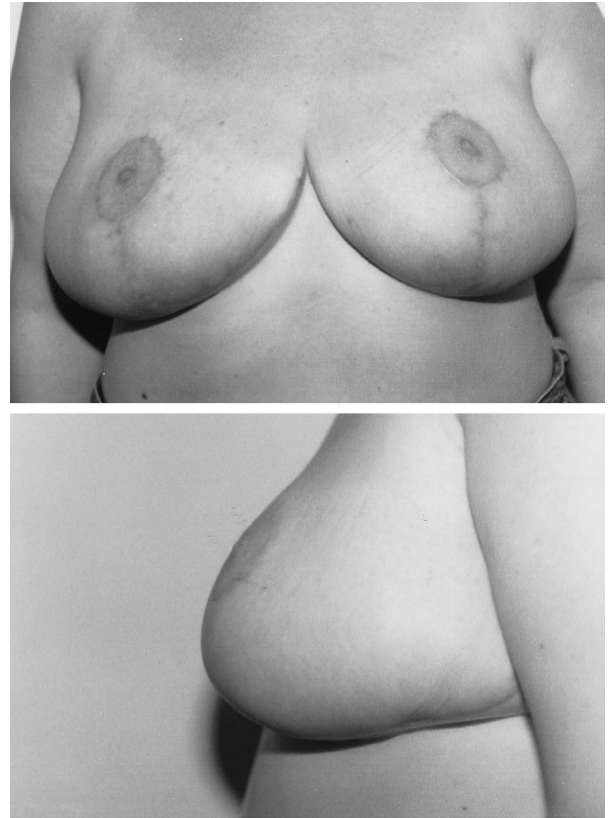


FIG. 8. (Above) Anterior view at the 6-month follow-up. The nipple appears elevated owing to mild "bottoming out" of the breast. (Below) Lateral view at the 6-month follow-up.

also permit reduction to a smaller size. Reduction mammoplasty using a medial pedicle is proposed as a procedure that solves these problems. Advantages of a medially based pedicle include reliable circulation, preservation of nipple-areola sensation, elimination of nipple-areola hypopigmentation, and enhancement of central breast projection.

The anatomic advantages of a medial pedicle are numerous. The medial pedicle derives its blood supply from the internal mammary artery and its innervation from the intercostal nerves. Studies on the vascular territories of the breast and nipple-areola complex have demonstrated the internal mammary artery to be the dominant blood supply in 70 percent of patients.¹² Studies on the innervation of the nipple-areola complex have demonstrated fine branches from both the anterior (medial) and lateral 4th, 5th, and 6th intercostal nerves.^{13,14} The orientation of the medial pedicle permits inclusion of the dominant vasculature and a portion of the central breast innervation. In addition, the pedicle permits a wider arc of rotation, thus providing flexibility in place-

ment and positioning, which minimizes complications.

The medial pedicle is a technique derived from the superomedial pedicle that was initially described by Orlando and Guthrie.⁴ In their original report of 12 patients following superomedial pedicle reduction mammoplasty, nipple-areola viability was demonstrated in 12 patients and sensitivity in 11 patients; however, it is not known whether these patients had mild, moderate, or severe mammary hypertrophy. Hauben⁵ used this technique on 78 patients, demonstrating no areolar or flap loss and preservation of sensation in 83 percent of patients after 8 months. The length of nipple transposition ranged from 4 to 15 cm with a median of 8 cm, and the weight of breast tissue excised ranged from 210 g to 1850 g per breast. Hauben stated that the superomedial pedicle technique was suitable for breasts of "moderate to rather large size."⁷ Finger et al.⁶ used this method in 291 breasts and found that resections as large as 4100 g and nipple transpositions up to 30 cm were well tolerated with nipple viability and preservation of sensation.

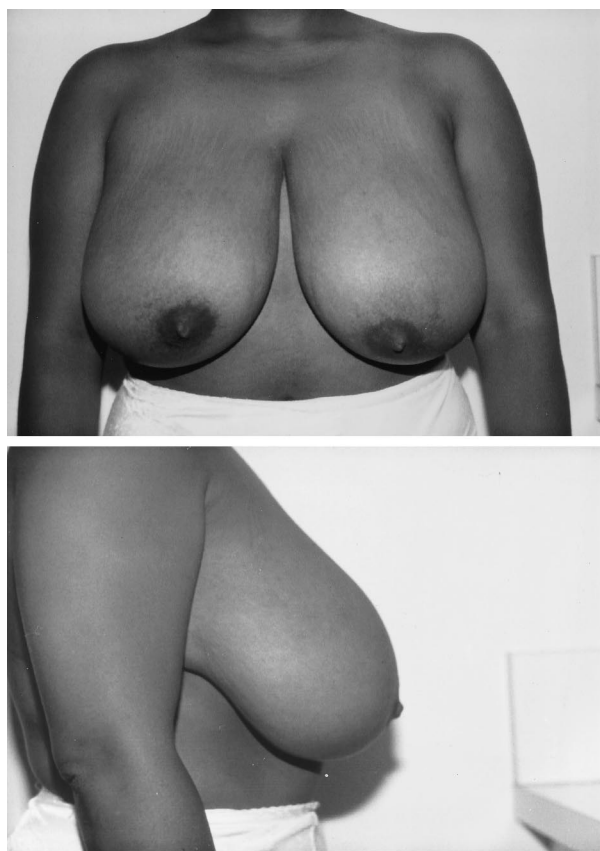


FIG. 9. (Above) Preoperative, anterior view of a 27-year-old woman with mammary hypertrophy. (Below) Lateral view.

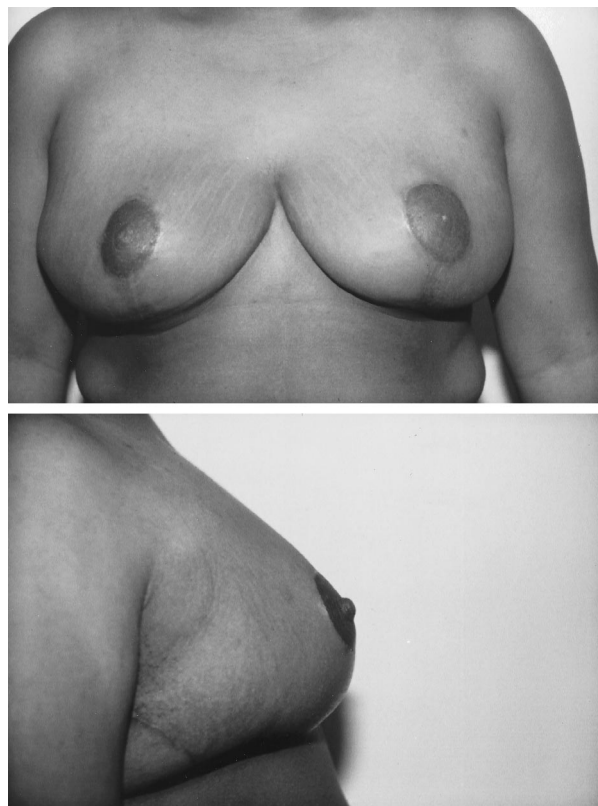


FIG. 10. (Above) Postoperative view at the 7-month follow-up. Weight of resected breast was 1250 g on the right and 1315 g on the left. The nipples have remained viable and sensate. (Below) Lateral view demonstrating good breast and nipple projection.

This study has demonstrated that the medial pedicle may minimize complications of reduction mammoplasty for severe mammary hypertrophy. Nipple-areola viability was preserved in all patients. Loss of nipple-areola sensation was infrequent with a medial pedicle, occurring in only one breast. The medial pedicle length in this patient was 19 cm, which was the longest of the 44 breasts, and the weight of tissue removed was 1905 g. In this study, loss of sensation seems to be related to pedicle length rather than weight of tissue removed, as resections of 2500 g did not result in sensory loss. Nipple-areola pigmentation was preserved in all 44 breasts (100 percent) following medial pedicle reduction mammoplasty. Patient satisfaction was high regarding breast shape, projection, and outcome.

Current techniques of breast reduction for severe mammary hypertrophy use the inferior and bipedicle as well as the amputation and free-nipple graft techniques. The literature is replete with advocates and opponents of each technique. Opponents of inferior pedicle re-

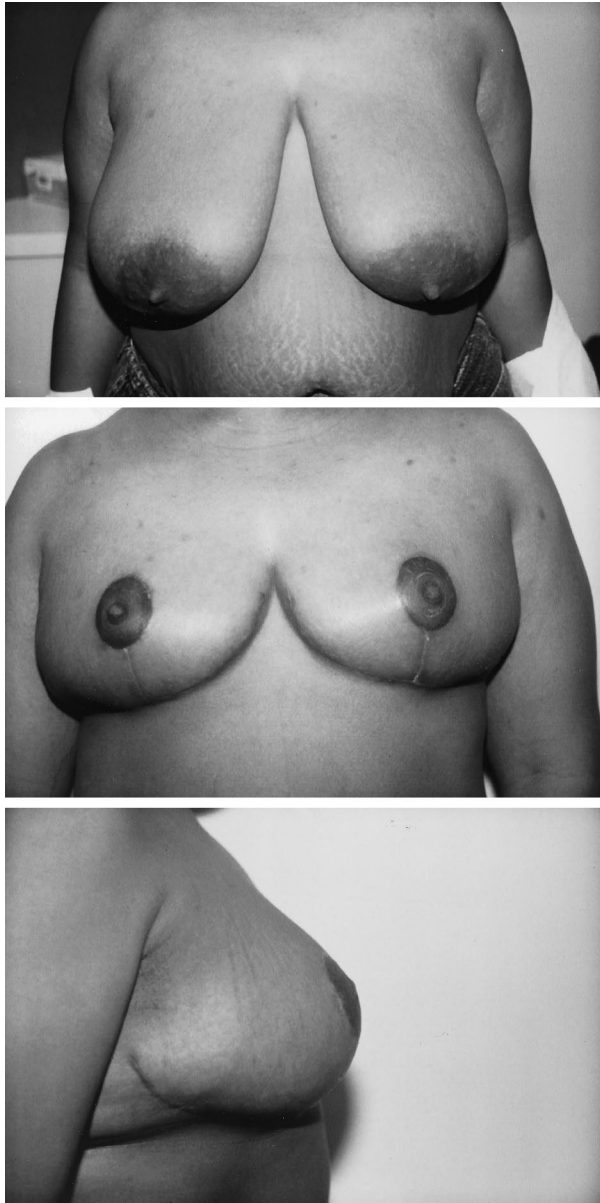


FIG. 11. (Above) Anterior view of a 26-year-old woman with mammary hypertrophy. (Center) After removal of 1230 g from each breast, the nipple-areola complex is viable and sensate at the 2-month follow-up. (Below) Lateral view at the 2-month follow-up demonstrating excellent breast and nipple projection.

duction mammoplasty for severe mammary hypertrophy state that dermal pedicle techniques in patients with a longer sternal notch to nipple distance are more susceptible to nipple-areola necrosis.^{1,15-18} Resections of greater than 1000 g per breast are more likely to result in nipple and/or fat necrosis.^{15,19} Others, however, feel that it is the pedicle length, rather than the weight of breast excised, that is the primary determinant of postoperative complications.^{4,20} Sensory deficits are also more likely

following inferior pedicle techniques.^{1,15} McKissock²¹ states that the bipedicle technique should be limited to breasts with a nipple transposition distance less than 15 cm.

Advocates of the inferior pedicle technique emphasize contrasting results. Georgiade et al.²² have demonstrated that resections of up to 2500 g per breast with mean nipple transposition distance of 18 cm are safely performed. Courtiss and Goldwyn¹¹ reported on 12 patients in whom the nipple-areola complex was elevated an average of 16 cm, and the average weight of resected tissue per breast was 1050 g. Partial areolar necrosis was observed in 1 of 24 breasts, and nipple-areola sensation was preserved in all breasts in which sensation was present preoperatively. Chang et al.¹⁰ used this technique in 24 patients with severe mammary hypertrophy who had bilateral resections totaling 3000 to 5100 g. Complications occurred in seven patients (29.2 percent). Nipple-areola necrosis was noted in one patient, and no patients had loss of sensation. Roth et al.²³ have quantified blood flow to the nipple-areola complex transposed on an inferior pedicle follow-

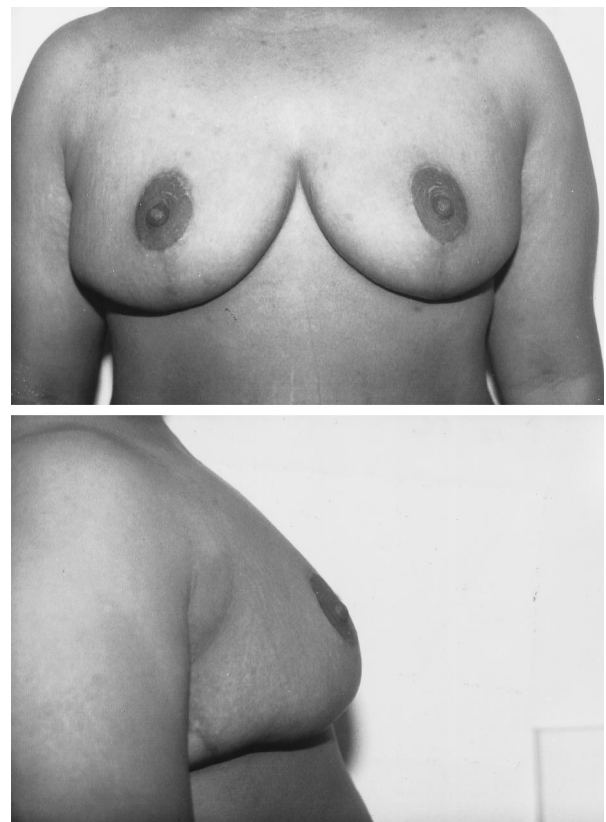


FIG. 12. At the 6-month follow-up, there has been minimal interval change in breast projection and nipple position.

ing resections exceeding 2100 g and have demonstrated an 83 percent reduction in flow.

Opponents of amputation mammoplasty with free-nipple graft cite loss of nipple sensation, poor breast projection, loss of lactation, and areolar hypopigmentation as the primary reasons.^{2,11} Advocates of amputation mammoplasty with free-nipple graft state that refinements of the technique have improved the quality.^{3,24,25} Slezak and Dellon⁹ found that pressure thresholds for the nipple, areola, and skin are reduced, and vibratory thresholds are elevated following amputation and free-nipple graft. Necrosis of the nipple-areola complex following free-nipple graft is a potential complication; however, the incidence is low.^{23,25}

The results of this study clearly demonstrate that medial pedicle reduction mammoplasty is a safe and reliable technique and should be given primary consideration in cases of severe mammary hypertrophy. The advantages of this technique are that the medial pedicle contains the primary blood supply to the breast and is shorter than the inferior pedicle in a given breast. This can optimize perfusion of the nipple-areola complex. Innervation of the nipple-areola complex is preserved, and the percentage of patients maintaining sensibility exceeds that of the inferior pedicle as well as the amputation and free-nipple graft techniques. Retention of sensation seems to be related to pedicle length rather than weight of breast tissue excised. Breast shape and projection are enhanced when compared with amputation and free-nipple graft and equivalent to that obtained with the inferior pedicle technique.

Maurice Y. Nahabedian, M.D.
Johns Hopkins Medical Institutions
601 North Caroline Street, 8152C
Baltimore, Md. 21287
maurice@welchlink.welch.jhu.edu

REFERENCES

1. Courtiss, E. H., and Goldwyn, R. M. Breast sensation before and after plastic surgery. *Plast. Reconstr. Surg.* 58: 1, 1976.
2. Townsend, P. L. G. Nipple sensation following breast reduction and free nipple transplantation. *Br. J. Plast. Surg.* 27: 308, 1974.
3. Koger, K. E., Sunde, D., Press, B. H. J., and Hovey, L. M. Reduction mammoplasty for gigantomastia using inferiorly based pedicle and free nipple transplantation. *Ann. Plast. Surg.* 33: 561, 1994.
4. Orlando, J. C., and Guthrie, R. H. The superomedial dermal pedicle for nipple transposition. *Br. J. Plast. Surg.* 28: 42, 1975.
5. Hauben, D. J. Experience and refinements with the supero-medial dermal pedicle for nipple-areola transposition in reduction mammoplasty. *Aesthetic Plast. Surg.* 8: 189, 1984.
6. Finger, R. E., Vasquez, B., Drew, G. S., and Given, K. S. Superomedial pedicle technique of reduction mammoplasty. *Plast. Reconstr. Surg.* 83: 471, 1989.
7. Hauben, D. J. Superomedial pedicle technique of reduction mammoplasty (Discussion). *Plast. Reconstr. Surg.* 83: 479, 1989.
8. van der Meulen, J. C. Superomedial pedicle technique of reduction mammoplasty (Letter). *Plast. Reconstr. Surg.* 84: 1005, 1989.
9. Slezak, S., and Dellon, A. L. Quantitation of sensibility in gigantomastia and alteration following reduction mammoplasty. *Plast. Reconstr. Surg.* 91: 1265, 1993.
10. Chang, P., Shaaban, A. F., Canady, J. W., Ricciardelli, E. J., and Cram, A. E. Reduction mammoplasty: The results of avoiding nipple-areolar amputation in cases of extreme hypertrophy. *Ann. Plast. Surg.* 37: 585, 1996.
11. Courtiss, E. H., and Goldwyn, R. M. Reduction mammoplasty by the inferior pedicle technique: An alternative to free nipple grafting for severe macromastia or extreme ptosis. *Plast. Reconstr. Surg.* 59: 500, 1977.
12. Palmer, J. H., and Taylor, G. I. The vascular territories of the anterior chest wall. *Br. J. Plast. Surg.* 39: 287, 1986.
13. Jaspars, J. J. P., Posma, A. N., van Immerseel, A. A. H., and Gittenberger-de Groot, A. C. The cutaneous innervation of the female breast and nipple-areola complex: Implications for surgery. *Br. J. Plast. Surg.* 50: 249, 1997.
14. Sarhadi, N. S., Dunn, J. S., Lee, F. D., and Soutar, D. S. An anatomical study of the nerve supply of the breast, including the nipple and areola. *Br. J. Plast. Surg.* 49: 156, 1996.
15. Dabbah, A., Lehman, J. A., Parker, M. G., Tantri, D., and Wagner, D. S. Reduction mammoplasty: An outcome analysis. *Ann. Plast. Surg.* 35: 337, 1995.
16. Hawtof, D. B., Levine, M., Kapetansky, D. I., and Pieper, D. Complications of reduction mammoplasty: Comparison of nipple areolar-graft and pedicle. *Ann. Plast. Surg.* 23: 3, 1989.
17. Ariyan, S. Reduction mammoplasty with a nipple-areola carried on a single, narrow inferior pedicle. *Ann. Plast. Surg.* 5: 167, 1980.
18. Hoopes, J. E., and Maxwell, G. P. Reduction mammoplasty: A technique to achieve the conical breast. *Ann. Plast. Surg.* 3: 106, 1979.
19. Muller, F. E. Spätergebnisse von 1,046 Mammareduktionsplastiken. *Langenbecks Arch. Chir.* 369: 273, 1986.
20. Wray, R. C., and Luce, E. A. Treatment of impending nipple necrosis following reduction mammoplasty. *Plast. Reconstr. Surg.* 68: 242, 1981.
21. McKissock, P. K. Correction of Macromastia by the Bipedicled Vertical Dermal Flap. In R. M. Goldwyn (Ed.), *Plastic and Reconstructive Surgery of the Breast*. Boston: Little, Brown, 1976. Pp. 222-225.
22. Georgiade, N. G., Serafin, D., Riefkohl, R., and Georgiade, G. S. Is there a reduction mammoplasty for "all seasons"? *Plast. Reconstr. Surg.* 63: 765, 1979.
23. Roth, A. C., Zook, E. G., Brown, R., and Zamboni, W. A. Nipple-areolar perfusion and reduction mammoplasty.

- ty: Correlation of laser Doppler readings with surgical complications. *Plast. Reconstr. Surg.* 97: 381, 1996.
24. Romano, J. J., Francel, T. J., and Hoopes, J. E. Free nipple graft reduction mammoplasty. *Ann. Plast. Surg.* 28: 271, 1992.
25. Oneal, R. M., Goldstein, J. A., Rohrich, R., Izenberg, P. H., and Pollock, R. A. Reduction mammoplasty with free nipple transplantation: Indications and technical refinements. *Ann. Plast. Surg.* 26: 117, 1991.
26. Hang-Fu, L. Subjective comparison of six different reduction mammoplasty procedures. *Aesthetic Plast. Surg.* 15: 297, 1991.