

Case Study 5: Cough, Croup, and Trip to the Emergency Room

Kim Bookout

Texas Woman's University

Case Study 3: Cough, Croup, and Trip to the Emergency Room

Subjective Data**Patient Profile****Identifying Factors**

The patient is a 3-year-old female with no history of chronic illness who presents to the primary care clinic for evaluation of a 4-day history of cough and fever. She is accompanied by her mother who is a nurse at Baylor University Medical Center.

Background Information**Chief Complaint**

The child has had a “barky, croupy, cough” for 4 days. The cough began on Sunday but worsened on Monday and Tuesdays (Day 1 and 2 of symptoms). On Tuesday (Day 2) evening the child spiked a temperature of 104 that has come down to 101-102 between doses of Tylenol and Motrin. Today, the child’s mother noticed that her upper lip is mildly swollen and the child refused to allow her mother to wipe her nose.

HPI

As stated above, the patient presented with a 4-day history of cough with onset of fever on day 2 of symptoms. The cough has a barky quality and is worse when the patient lies down. She has a decreased appetite and is taken less fluids by mouth. She has had clear nasal drainage for several days and significant nasal congestion. She was seen by her primary care physician on Day 3 of symptoms (Wednesday) and was diagnosed with croup. No medications were given or prescribed.

Past Medical History***Birth History:***

The patient was a 36-week infant born to G1 P0→1 female. She weighed 5 lbs. 15 oz. at birth and had no complications. She was breast fed as an infant.

Illnesses:

1. Hordeolum

Allergies: Penicillin

Surgeries: None

Medications:

1. Tylenol 100mg/5ml 1 teaspoon q 4 hours prn fever, pain
2. Motrin 100mg/5ml 1 teaspoon q 6 hours prn fever pain

(The above meds were alternated every 3 hours in an attempt to control the patient's fever.)

Health Maintenance:

This was the first visit by this patient to our office. By report of the patient's mother, immunizations were up-to-date and she had received routine well-child exams at 2-, 4-, 6-, 9-, 12-, 15-, 18-, 24-, and 36-month time points. She has had no developmental delays.

Social History:

The patient lives at home with her mother, father and 17-month old brother in Ennis, Texas. Her mother is a registered nurse and works in mammography in Dallas and her father works at Kwik Kar. She attends mother's day out three days per week. The patient lives in a single-family home and has adequate resources for food, clothing, etc.

Healthcare insurance is adequate and is provided through her mother's employer. The child's extended family is close and spends much time together on weekends and

holidays. Her aunt, also a nurse, lives in the Dallas area and is the reason she is visiting the office today. She is employed in this primary care office.

Family History:

The child's family history is negative for deafness, nasal allergies, asthma, tuberculosis, heart disease, hypertension, hypercholesterolemia, blood dyscrasias, liver disease, kidney disease, diabetes, alcohol abuse, drug abuse, mental illness, mental retardation, and immune diseases or conditions.

Review of Systems

General Health: Healthy, vibrant child with no chronic disease. Currently with fever, cough, congestion, and lip edema.

Skin/Hair/Nails: No excess sweating, rashes, dryness, hair loss or nail changes.

HEENT: Denies headaches. No visual disturbances. Head/nasal congestion for approximately 4-5 days. No nasal congestion at present. Stye at right lower lid since November. Consulted with ophthalmologist. Antibiotic drops prescribed and completed.

Neck/Lymph: No lumps or swelling in neck. No tender lymph nodes.

Breast: Deferred

Chest/Lungs: No dyspnea with exercise. Currently with "croupy cough" but no history of reactive airway disease.

CV: No murmur. No edema of lower extremities.

Peripheral Vascular: No changes in coloration of extremities.

GI: Appetite fair. Denies signs and symptoms of gastro esophageal reflux. No food allergies. No constipation or diarrhea.

GU: Potty trained. Occasional night-time accidents.

Endocrine: No temperature intolerance. Polyuria, polydipsia, or polyphasia.

M/S: No muscle weakness or pain. No difficulty with ambulation.

Neurological: No dizziness, fainting, or seizure activity.

Psychiatric: No anxiety. No behavioral concerns.

Objective Data

Physical Exam

Vital Signs.

Height: 34 inches *Weight:* 30 lbs *Temp:* 100.9 *Pulse:* 131

Respiratory Rate: 32 *Pulse Ox:* 100% *BP:* 84/67

General: 3 year old Caucasian female in no acute distress. Well developed and well nourished. She is dressed appropriately for weather and is well-groomed.

Skin/Hair/Nails: Skin is warm, pink, and dry. No rashes noted. No erythematous palms. Turgor brisk.

Head: Atraumatic, normocephalic Scalp with no dryness or scaling.

EENT: Pupils equal, round, and reactive to light. Sclera mildly injected. No discharge. 2-3 mm styte at R lower eyelid with no discharge. Nose with mildly edematous turbinates and congestion. Skin at nasal opening with mild erythema likely secondary to frequent use of tissues. Oral mucosa pink and moist. Tonsils red and 2-3+ with white coating. Uvula midline. Upper lip with mild edema. No oral lesions noted. No caries noted. Non-tender to palpation of lip, maxillary sinuses. TMs pearly pink/gray with good light reflex.

Neck/Lymph: Neck supple with no nuchal rigidity. Shoddy lymph nodes.

Lungs: No increased work of breathing. Lungs clear to auscultation. No wheezing or retractions. Barky cough noted throughout visit.

CV: Heart rate rapid with no murmur. S1S2 audible.

Abdomen: Soft, non-tender, non-distended. Normo-active bowel sounds. No hepatosplenomegaly. No masses.

Breasts: deferred.

M/S: Ambulatory. No hypotonia.

Extremities: Warm and well perfused. 2+ pulses. No cyanosis. No edema.

Genitalia: Deferred.

Rectal: Deferred.

Neurological: CN II-XII intact. Moves all extremities well. Strength 5/5.

Previous Lab: None.

Discussion of Findings:

This patient presents with a 4-day history of a barky cough followed by onset of fever 2 days prior to the visit. She has a red throat with tonsillar hypertrophy and a white coating on her tongue. Her scleras are injected and her nose is congested. Her upper lip has mild edema without tenderness with no oral lesions noted. She has a single 2-3mm sty on the right lower eyelid with no discharge or edema. Her lungs are clear to auscultation and she does not appear to have an increased work of breathing. She has no rash.

Assessments/Impression

1. Cough
2. Croup
3. Fever
4. Pharyngitis

Viral croup is a syndrome occurring more often in fall and early winter. It is most often caused by parainfluenza virus serotypes. Other organisms responsible for croup are respiratory

syncytial virus, human metapneumovirus, influenza, adenovirus, and *Mycoplasma pneumoniae*.

Fever is usually absent or low-grade but may be high-grade. In the absence of stridor, croup may be treated with Dexamethasone, 0.6mg/kg as a single dose. Symptoms resolve within 3 to 6 hours of administration of glucocorticoids (Hay, Levin, Sondheimer, & Deterding, 2009).

Differential Diagnosis:

1. Pneumonia
2. Strep pharyngitis
3. Viral illness (influenza, etc.)

Chronic Diagnosis:

1. Sty (hordeolum)

Plan

Laboratory Tests:

1. Rapid strep (Negative)
2. Influenza A & B (Deferred. Due to the length of time of symptoms, and age of the patient, anti-viral treatment is not warranted in this patient.)

Diagnostic Tests:

1. Chest radiograph (bronchial wall thickening with viral pattern in airway)

Health Maintenance:

Up to date

Medications: (Continue current medication for sty.)

1. Dexamethasone 0.6mg/kg PO x i.
2. Zithromax 100/5 7ml PO qd x i day then 3.5ml PO qd x 4d.
3. Xopenex 0.63mg per nebulizer qid prn cough
4. Motrin 5ml PO q 6-8hrs prn fever

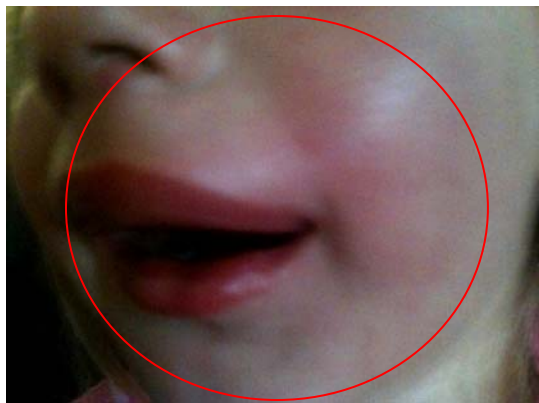Education:

Discussed rationale for treatment with mom. Instructed mom in the use of Dexamethasone for the treatment of croup. Symptom control of croup should begin approximately 3-6 hours following administration of dexamethasone and last for approximately 72 hours. Instructed mom in signs and symptoms of worsening. Instructed to continue current medication for sty. Will follow up in 2 days if no improvement in symptoms.

Referral: None.

Follow-up and Continuity of Care:

The patient's mother called the following morning. The patient's lip was markedly edematous and the edema was spreading superiorly toward eye. See Figure 1 below.



Due to the rapid spread of edema and erythema, the patient was referred to the emergency center at Children's Medical Center, Legacy campus in Plano. The patient was seen in the emergency room and a CT scan was ordered. A submaxillary abscess was noted.

Otolaryngology consult was ordered. The Ear/Nose/Throat (ENT) specialist recommended surgical intervention to drain the abscess. The patient was admitted to the hospital and a course of intravenous antibiotics was initiated with Vancomycin. Surgical intervention was performed. A small incision was made at the upper left gumline and the abscess was drained. Cultures were sent. Initial growth isolated 3 organisms. The patient was released for home on post-op day 2. The patient proceeded to improve and post-

operative care was continued by the patient's parents. See Figure 2 for a photo of postoperative day three.



The patient continued her post-operative course of antibiotics using PO medications. Her cough continued to improve. She will follow up with the ENT as recommended.

Discussion:

Croup and cough. Viral croup is the most common cause of airway obstruction in children. In children ages 6 months to 6 years it occurs as often as 6 cases per 100 children. Hospitalizations related to croup account for almost \$56 million in the United States (Knutson & Aring, 2004). Croup is caused most frequently (almost 75% of all cases) by parainfluenza viruses with the remaining cases caused by adenovirus, respiratory syncytial virus, rhinovirus, enteroviruses, and influenza A and B (Knutson & Aring). *Mycoplasma pneumonia* has been isolated on occasion in children who present with mild croup. Differential diagnoses for viral croup include spasmodic croup (which is difficult to distinguish), bacterial tracheitis, acute laryngeal fracture, burns, foreign body, neoplasm, peri-tonsillar abscess, vocal cord paralysis, and laryngomalacia.

Diagnosis is made clinically from symptom evaluation. Clinicians may wish to obtain radiographs to confirm a diagnosis of croup but, only 50 percent of patients with croup show the classic steeple sign on the films. (See Figure 3 for radiograph example.)

Figure 3. Steeple sign.

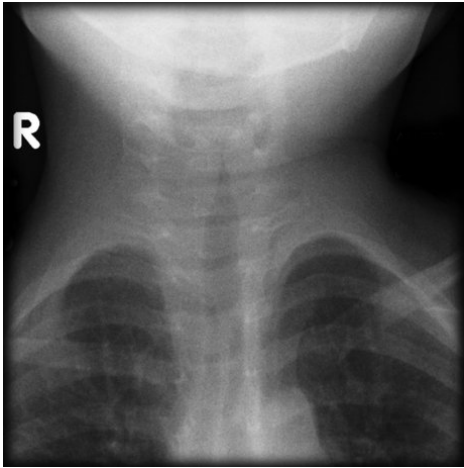


Photo credit: http://upload.wikimedia.org/wikipedia/commons/1/12/Croup_steeple_sign.jpg

The most important aspect of the management of croup is centered around airway management. Outpatient treatment of croup with oral (PO) dexamethasone versus intramuscular (IM) dexamethasone was evaluated by Rittichier and Ledwith (2000). The researchers studied 277 patients who were patients in an emergency center with the diagnosis of croup. Children were randomized into two groups. One group received dexamethasone PO while the other received dexamethasone IM. Each were dosed at 0.6mg/kg. No significant difference was detected and neither group required further intervention. Thus, the researchers concluded that a single dose was beneficial in outpatient management. This protocol has been adopted by most pediatric care providers. If stridor is present with croup, nebulized racemic epinephrine is the standard treatment (Knutson & Aring, 2004). Since stridor was not present in this patient, no further discussion will be conducted.

Bronchiolitis. Treatment of bronchiolitis remains controversial in the literature (American Academy of Pediatrics, 2006; Zorc, 2008). This controversy is, in part, related to the wide variation in presentation as well as response to therapy. In a recent study of outpatient primary care visits, Mansbach et al. (2007) found that 52% of outpatients were prescribed

bronchodilators while 23% were prescribed antibiotics. An additional 7.1% were prescribed inhaled corticosteroids despite a lack of evidence for efficacy (Mansbach et al.). The authors further found that 2% of the outpatients treated for bronchiolitis required hospitalization due to severity of illness while greater than 50% were managed with follow-up visits in the primary care setting. Although antibiotics are not generally recommended for use with bronchiolitis, they continue to be used in young infants due to concern over the possibility of bacterial infection (American Academy of Pediatrics). Inhaled bronchodilators and inhaled corticosteroids are also not routinely utilized in the management of bronchiolitis unless the infant demonstrates objective improvement following a trial of medication (American Academy of Pediatrics). Prognosis for infants with bronchiolitis is good for most infants although some concern exists regarding long-term compromise of lung compliance following infection in children younger than one year of age. In older children, however, bronchiolitis does not appear to have any long-term sequelae with regard to lung compliance.

Submaxillary abscess. A paucity of literature exists to support the plan of care related specifically to submaxillary abscess. As with skin abscess or soft tissue abscess, the gold standard for treatment is incision and drainage along with a course of systemic antibiotics (Hay et al., 2009). *Staphylococcus aureus* is the most common pathogen isolated from skin infections (Silverberg & Block, 2008). *S. aureus* is commonly carried in the nasal passages of children. A prevalence of 42% has been reported in the literature (Silverberg & Block). In addition, there has been an increase in cases of community acquired (CA) *S. aureus* in recent years in children (Silverberg & Block). Not only has CA-*S. aureus* increased but also there has been an increase in Methicillin-resistant-*S. aureus* (MRSA) (Newland & Kearns, 2008).

The goal of treatment for children with abscesses is to eliminate the causative factor (e.g. *S. aureus*). Cultures or swab samples from abscesses provide valuable information with respect to identification of the organism as well as sensitivity to antimicrobials. Empiric treatment is often initiated in outpatient treatment with trimethoprim-sulfamethoxazole (TMP-SMX). This treatment is ineffective in some strains of *Staphylococcus* so providers must adjust treatment accordingly.

Vancomycin continues to be the antimicrobial of choice for the treatment of MRSA for inpatient populations while clindamycin is utilized more commonly in the outpatient setting (Newland & Kearns, 2008). Skin and soft tissue infections with MRSA are the most common forms of bacterial infection encountered by pediatric care providers (Hay et al., 2009; Newland & Kearns, 2008; Silverberg & Block, 2008). The presentation of the patient in this case study was markedly different than the presentation of the majority of children with skin and soft tissue infections related to MRSA.

References

American Academy of *Pediatrics*. (2006). Diagnosis and management of bronchiolitis.

Pediatrics, *118*, 1774-1793.

Hay, W. W., Levin, M. J., Sondheimer, J. M., & Deterding, R. R. (Eds.). (2009). *Current*

diagnosis & treatment: Pediatrics (19th ed.). New York: McGraw Hill.

Knutson, D., & Aring, A. (2004, February 1). Viral croup. *American Family Physician*, *69*, 535-

540.

Mansbach, J., Pelletier, A., & Camargo, C. (2007). US outpatient office visits for bronchiolitis,

1993-2004. *Ambulatory Pediatrics*, *7*, 304-307.

Newland, J., & Kearns, G. (2008). Treatment strategies for methicillin resistant staphylococcus

aureus infections in pediatrics. *Pediatric Drugs*, *10*, 367-378. doi: 1174-5878/08/0006-

0367/\$48.00/0

Rittichier, K. K., & Ledwith, C. A. (2000). Outpatient treatment of moderate croup with

dexamethasone intramuscular versus oral dosing. *Pediatrics*, *106*, 1344-1348.

Silverberg, N., & Block, S. (2008, April). Uncomplicated skin and skin structure infections in

children: Diagnosis and current treatment options in the United States. *Clinical*

Pediatrics, *47*, 211-219. doi: 10.1177/0009922807307186

Zorc, J. (2008). Bronchiolitis trial and tribulation. *Academic Emergency Medicine*, *15*, 375-376.