

# IDIOPATHIC CARDIAC HYPERTROPHY

BY

D. G. VULLIAMY

*From the Children's Department, Guy's Hospital*

Received April 21, 1947

At the beginning of the century idiopathic hypertrophy of the adult heart was commonly accepted as a diagnosis: since then a wider knowledge of the pathology has almost eliminated the term. Similarly in infants and children the disease entity known as congenital idiopathic cardiac hypertrophy is becoming rarer as more underlying causes are brought to light.

The case here described is considered worth reporting because it appears to be an example of one type of infantile cardiac enlargement in which there are no signs of congenital heart disease at birth, but a rapid onset of symptoms and signs of cardiac failure in a previously healthy child, with a gross endocardial and myocardial fibrosis as the striking finding post-mortem.

## CASE HISTORY

V. H. was admitted to Guy's Hospital under the care of Dr. R. W. B. Ellis, at the age of two years nine months. He was an only child of healthy parents and there was no family history of tuberculosis or other important illness.

At birth he was a normal full term baby weighing 9½ lb. and there was no cyanosis following delivery. Breast feeding lasted for two months and was replaced by adequate artificial feeding including added vitamin extracts. His early development was normal, and he was walking at fifteen months of age. At one year he had pneumonia following measles, since when he had suffered from recurrent bronchitic attacks.

A month before admission he had been an active, healthy child, but for three weeks he had shown signs of fatigue, listlessness, and irritability. Food was often refused and a hard dry cough became noticeable. There was no apparent loss of weight.

On admission he was severely distressed, his face was flushed but the lips were not at that time cyanosed. There was dyspnoea, venous congestion in the neck, and pitting oedema of both ankles.

The apex beat was diffuse and pulsation could be easily felt from the third to the sixth left intercostal spaces and from the mid-clavicular line out to the anterior axillary line. There was no increased cardiac dullness on percussion to the right of the sternum. A blowing systolic murmur was heard at the apex, and the blood pressure was 105/70 in both arms.

A few scattered moist râles and rhonchi were the only abnormal physical signs in the lungs. The liver was enlarged and tender, reaching almost to the level of the umbilicus, but the spleen and kidneys were not palpable. Two days after admission the oedema had increased and there was evidence of a little ascites. Cyanosis was constant and dyspnoea was increased. Venesection of 45 c.c. of blood resulted in an improvement of the general condition.

X-ray screening of the chest showed a heart greatly enlarged to the left and very slightly to the right. A film taken a few days later is reproduced in Fig. 1 (see p. 165).

A blood picture showed a slight hypochromic microcytic anaemia and a normal white

count. A glucose tolerance test, done with the object of excluding glycogen disease, was normal and showed no abnormal rise on administration of adrenalin.

The urine showed no abnormal constituents. Ten days after admission an electrocardiogram showed right axis deviation with a wide notched QRS complex (Fig. 2, see p. 165). A Mantoux test was positive to 1 : 10,000.

The subsequent course of the illness, which lasted for nearly five months, was one of partial recoveries and relapses with a general trend towards increasing cardiac failure. During the periods of relapse, in which the patient became almost moribund, there was pyrexia between 100° and 104° F., sometimes swinging in character, associated with signs of localized patchy consolidation in the lungs, particularly on the left side. White cell counts on these occasions showed a polymorph leucocytosis and blood culture was sterile. There was an apparent response to sulphadiazine, and the attacks were considered to be due to localized areas of lung collapse with superimposed infection. Therapy during the illness included digitalis, to which there was little response after the first relapse, and a course of vitamin B<sub>1</sub> as a therapeutic test for beri-beri, which also had no effect. An oxygen tent gave considerable relief during the relapses.

A telerradiogram of the chest taken seven weeks after admission is reproduced in Fig. 3 (see p. 166), and shows an increase in the root shadows and some blurring of the heart outline.

In view of the size and shape of the heart shadows and the positive Mantoux test, suggesting a possible diagnosis of tuberculous pericarditis, a diagnostic paracentesis of the pericardium was attempted during the third month. No pericardial fluid was, however, found.

An alternative diagnosis of primary mediastinal neoplasm was suggested but screening failed to give any definite confirmation.

During the following month the degree of cardiac failure gradually increased and finally a condition of generalized œdema followed by bronchopneumonia supervened and the patient died twenty-one weeks after admission.

*Autopsy.* (Dr. K. J. Randall, Pathology Department, Guy's Hospital.)

There were numerous sub-pericardial hæmorrhages beneath both visceral and parietal surfaces. The pericardial sac contained about 100 ml. of blood-stained fluid. The heart showed gross generalized enlargement, weighing 290 g. and being of adult dimensions (normal heart weight for a child of 3 years=60 g.). The greatest thickness of the left ventricular wall was 1.8 cm., the maximum normal for an adult heart being approximately 1.0 cm. Apart from this gross hypertrophy there was considerable dilatation of all the chambers so that the thickness of the contracted heart wall would have been even greater.

The myocardium was of normal colour and firm consistency. The endocardium, particularly of the left ventricle showed marked thickening of the "sugar icing" type. No congenital abnormalities of the heart or great vessels were present. The valves and coronary arteries were normal.

Pleural effusions were present on both sides and the lungs showed early suppurative pneumonia. The mediastinal lymph nodes were moderately enlarged, but there was no sign of any tuberculous focus.

The liver showed gross fatty change and chronic venous congestion. There were 500–600 ml. of straw-coloured fluid in the peritoneal cavity.

No other abnormality of any organ was found.

*On microscopical examination,* the wall of the left ventricle showed a gross diffuse thickening of the endocardium by fibrous tissue. There was penetration of the fibrous tissue into the myocardium. This fibrosis was confirmed by staining with van Gieson's stain (Fig. 4, see p. 166). No excess of glycogen was seen in sections stained by Best's carmine. There was no excessive lymphocytic infiltration of the muscle and no evidence of hyperplasia of the muscle fibres.

Apart from the terminal suppurative pneumonia in lung sections and confirmation of the fatty change and passive venous congestion in the liver, no significant abnormality was seen in any other section.

#### DISCUSSION

Kugel and Stoloff (1933) in a review of cases of so-called idiopathic cardiac hypertrophy of infancy and childhood published up to 1933, found from re-examination of the autopsy reports that out of a total of 52 cases, 17 could be regarded as pure idiopathic hypertrophy. Of the remainder, 8 had inadequate autopsy reports and 27 showed various cardiac abnormalities, amongst which endocardial thickening and increased fibrous tissue in the myocardium were common findings. Round cell infiltration of the heart muscle was mentioned as occurring in 4 cases.

In addition they reported in detail 7 new cases which they claimed might have been recorded as idiopathic hypertrophy had not careful histological examination of the heart been carried out. They all showed a similar picture, including thickening of the endocardium and patchy degeneration of muscle fibres with replacement fibrosis. Two of them showed excessive round cell infiltration, and in no case was there any abnormality of the valves or the origin of the coronary arteries. An eighth case was added to the series by one of the authors (Kugel, 1939) in which a similar pathology was found and glycogen disease was excluded by special staining.

In these eight cases, the ages ranged from three months to six and a half years, males being affected equally with females. The total length of the history varied from one day to ten weeks and in no case was there any cyanosis at birth. The main clinical features were similar to those of the case here described, namely a fairly rapid onset of symptoms in a previously healthy child, beginning with fretfulness and refusal of food, then dyspnoea, and later cyanosis leading to a death not long delayed. In one of these cases there was a previous history of pneumonia, and cough was a prominent symptom in two. Neither clinically nor at autopsy did these cases suggest a congenital origin, and the features were more consistent with a past non-specific infection involving the heart.

In other recorded cases it has been noticed that the symptoms dated from a severe lung infection (Mahon, 1936, and Lightwood and Court, 1939). In the three cases reported by Neely (1941) the hypertrophy was attributed to an interstitial pneumonitis demonstrated at autopsy. It is interesting that the histological findings in the heart were similar to those mentioned above, the hypertrophy and endocardial thickening, however, being right-sided instead of mainly left-sided, possibly due to increased resistance in the pulmonary circulation.

In one case with a mild degree of coarctation of the aorta, on the other hand, where the cardiac enlargement was considered to be much greater than could be accounted for by this lesion alone, the endocardial thickening was almost entirely left-sided (Levine, 1934). The suggestion of increased resistance in the circulation playing a part in the aetiology has also been put forward by Powers and Le Compte (1938), whose case of a child aged eight months showed enlargement of the left ventricle, apparently almost entirely due to fibrous tissue, as there was no hypertrophy of individual muscle fibres and no evidence of hyperplasia. In cases of hypertension, however, no such endocardial thickening is found.

Glycogen disease has undoubtedly been responsible for some of the reported instances of so-called idiopathic hypertrophy (Ellis, 1935), and only during the last few years has evidence of infiltration with glycogen been looked for post-mortem in such cases.

A specimen of heart muscle from a case described by Carrington and Krumbhaar in 1924 was re-examined after being kept in formalin for many years, when special staining revealed the presence of glycogen infiltration (Finklestein, 1936). It is possible, in view of the fact that the glycogen is not uniformly distributed throughout the cardiac muscle but only in certain

areas (glycogenica circumscripta) that the condition is a more-frequent cause than is at present realized (van Creveld and van der Linde, 1939).

In our case the main clinical features are typical of the majority of cases of idiopathic hypertrophy reported, except that the age of onset is slightly above the average.

Glycogen disease, vitamin B<sub>1</sub> deficiency, hypertension, gross anæmia, and congenital structural abnormalities were all excluded, and the ætiology of the condition of gross cardiac hypertrophy with endocardial and myocardial fibrosis as the main post-mortem finding, remains unexplained.

#### SUMMARY

A case of cardiac hypertrophy in a child of two and a half years is described, and the steps taken to exclude the known causes of enlargement, including glycogen disease, are recorded.

At autopsy the heart was found to be 290 g., which is almost of adult size; it showed no structural congenital abnormalities but a marked endocardial fibrosis which penetrated into the myocardium. Cases of a similar nature and some suggestions which have been put forward as to the cause of the condition are discussed.

Thanks are due to Dr. Maurice Campbell for his criticism and advice.

#### REFERENCES

- Carrington, G. L., and Krumbhaar, E. B. (1924). *Amer. J. Dis. Child.*, **27**, 449.  
 Ellis, R. W. B. (1935). *Proc. Roy. Soc. Med.*, **28**, 1330.  
 Finklestein, L. E. (1936). *Amer. J. med. Sci.*, **191**, 415.  
 Kugel, M. A., and Stoloff, E. G. (1933). *Amer. J. Dis. Child.*, **45**, 828.  
 — (1939). *Amer. Heart J.*, **17**, 602.  
 Levine, H. D. (1934). *Amer. J. Dis. Child.*, **48**, 1072.  
 Lightwood, R., and Court, S. D. M. (1939). *Proc. Roy. Soc. Med.*, **32**, 316.  
 Mahon, G. S. (1936). *Amer. Heart J.*, **12**, 608.  
 Neely, J. M. (1941). *Ann. intern. Med.*, **15**, 727.  
 Powers, G. F., and Le Compte, P. M. (1938). *J. Paediat.*, **13**, 760.  
 van Creveld, S., and van der Linde, H. M. (1939). *Arch. Dis. Childh.*, **14**, 14.

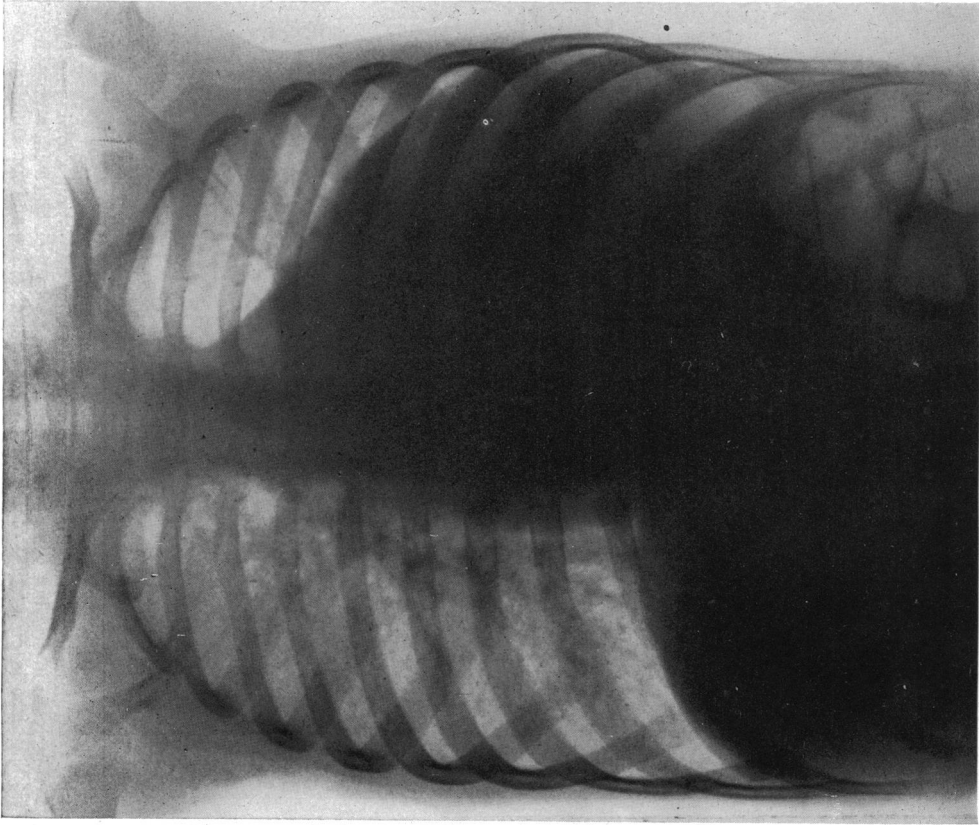


FIG. 1.—Teleroadiogram of the heart two weeks after admission, showing gross enlargement of the heart to the left and upwards, and some increase in the root shadows.

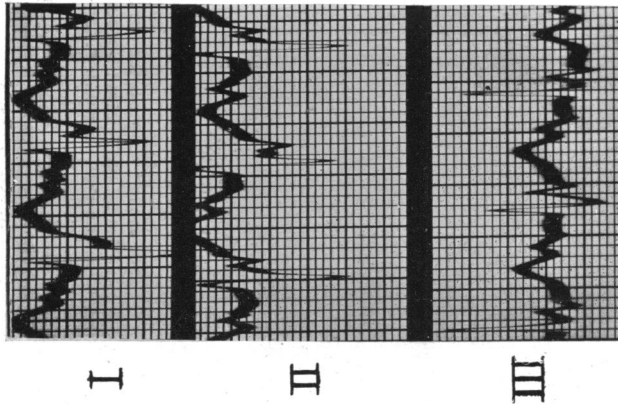


FIG. 2.—Electrocardiogram taken two days after admission, showing right axis deviation with a wide notched QRS complex.

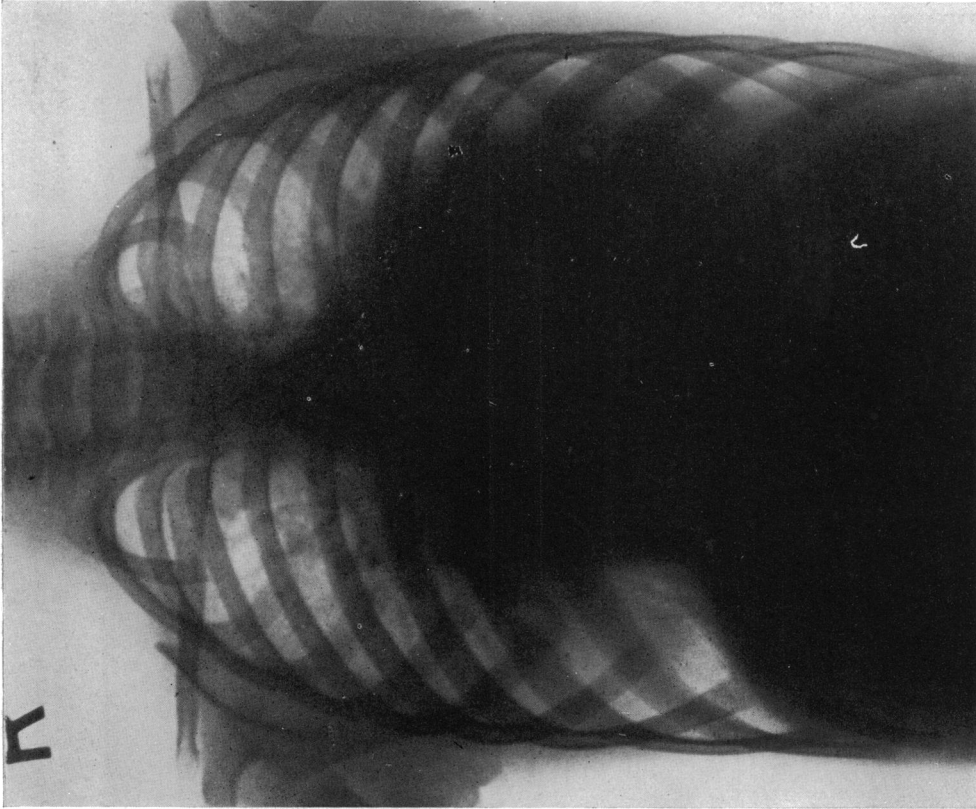


FIG. 3.—Teleradiogram of the heart seven weeks after admission, showing no further increase in size but some shifting of the heart to the right with a considerable increase in congestion of the lung fields on both sides, and some blurring of the outline of the heart.

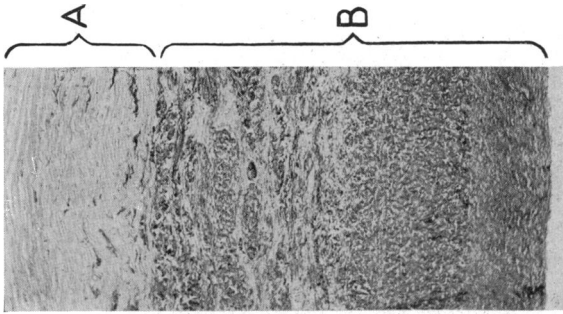


FIG. 4.—Section of endocardium of the left ventricle, the dark staining parts being fibrous tissue (van Gieson). Magnification:  $\times 46$ . (A) indicates myocardium showing fibrosis. (B) indicates endocardium with gross fibrous thickening.