

# Esophageal Strictures and Diverticula



C. Daniel Smith, MD

## KEYWORDS

- Esophageal stricture • Esophageal diverticula • Esophageal surgery
- GERD complications • Esophageal stricture management
- Esophageal diverticulectomy

## KEY POINTS

- Esophageal disease, and in particular, dysfunction of the lower esophageal sphincter (LES) manifesting as gastroesophageal reflux disease, is the most common of all gastrointestinal conditions impacting patients daily.
- Conditions leading impairment of esophageal outflow can be categorized into 2 broad categories, esophageal stricture or narrowing, and disorders of esophageal motility and LES function.
- Management focuses on the diverticulum itself, and relieving the underlying sphincter dysfunction.
- Many conditions can cause esophageal luminal narrowing or stricture; the most common are peptic, malignant, and congenital. Other causes include autoimmune, iatrogenic, medication induced, radiation induced, infectious, caustic, and idiopathic.

## INTRODUCTION

The topics of this article can best be understood in the context of impairment of esophageal outflow and its consequences. Conditions that lead to impairment of esophageal outflow can best be categorized into 2 broad categories: esophageal stricture or narrowing and disorders of esophageal motility and lower esophageal sphincter (LES) function. The consequence of esophageal stricture most often involves the immediate mechanical impact of the esophageal narrowing, and treatment focuses on relieving the stricture and control of the underlying process, which lead to the stricture. Esophageal diverticula are most commonly the result of pressurization of the esophagus above a dysfunctional sphincter that fails to open appropriately (lower esophageal and cricopharyngeal), leading to the development of a false diverticulum just proximal to the sphincter. Management focuses on the diverticulum itself, and relieving the underlying sphincter dysfunction. One type of diverticulum not related

---

Piedmont Clinic, 2795 Peachtree Road, Unit 1808, Atlanta, GA 30305, USA  
E-mail address: [cdanielsmith@icloud.com](mailto:cdanielsmith@icloud.com)

Surg Clin N Am 95 (2015) 669–681  
<http://dx.doi.org/10.1016/j.suc.2015.02.017>

[surgical.theclinics.com](http://surgical.theclinics.com)

0039-6109/15\$ – see front matter © 2015 Elsevier Inc. All rights reserved.

to esophageal motor dysfunction, a midesophageal diverticulum is also discussed in this article. In contrast with the false diverticula of the esophagus, a midesophageal diverticulum is a true diverticulum and the result of mediastinal inflammatory processes and the resulting focal traction on the esophageal wall, and is therefore not related to esophageal outflow obstruction.

Many conditions can cause esophageal luminal narrowing or stricture. The most common causes are peptic, malignant, and congenital; other causes include autoimmune, iatrogenic, medication induced, radiation induced, infectious, caustic, and idiopathic.

## **ESOPHAGEAL STRICTURE**

The term 'esophageal stricture' is reserved typically for intrinsic diseases of the esophagus causing luminal narrowing through inflammation, fibrosis, or neoplasia. Strictures are grouped typically into benign and malignant categories, with treatment varying depending on the underlying cause. Other causes of esophageal narrowing sometimes considered under the category of esophageal stricture include extrinsic compromise of the esophageal lumen by direct invasion, lymph node enlargement, or direct compression. This article focuses on the intrinsic causes of esophageal narrowing/stricture.

### ***Presentation***

---

Regardless of the nature of a stricture, the clinical presentation typically involves any or all of the following: dysphagia, food impaction, odynophagia, chest pain, and weight loss. Of these, progressive dysphagia to solids is the most common presenting symptom, with benign strictures following a more slow and insidious progression (eg, months to years), whereas dysphagia of a malignant stricture tends to progress more rapidly (eg, in weeks to months).

The clinical history may help to determine the cause of the dysphagia, although 25% of patient presenting with peptic strictures have no prior heartburn or other symptoms of gastroesophageal reflux disease (GERD). A known history of use of medications known to cause peptic ulcers or irritation, or caustic ingestion, are other examples of clinical history that might suggest the underlying cause.

### ***Diagnosis***

---

Esophagogastroduodenoscopy and contrast swallow are the mainstays of the initial workup and diagnosis for esophageal strictures. Although a contrast swallow is obtained most easily, esophagogastroduodenoscopy can provide more overall information and establish not only the diagnosis of a stricture or esophageal narrowing, but also allow visualization of the esophageal mucosa, including biopsy to establish definitively the underlying cause of the stricture. This becomes especially important in determining whether a stricture is benign or malignant. Contrast swallow may be particularly useful in defining the overall esophageal anatomy and identifying other associated pathology, such as an esophageal diverticulum. Esophageal pH testing, esophageal motility may be needed to confirm a diagnosis of GERD or an underlying esophageal motor abnormality (see Esophageal Diverticula section). Finally, when a stricture is determined to be malignant, or extrinsic pathology is thought to be the cause of esophageal narrowing, CT of the chest and abdomen is indicated to establish the cause of extrinsic narrowing and/or to stage a biopsy-proven malignant stricture. Endoscopic ultrasonography has emerged as a useful diagnostic tool to characterize the nature of a stricture and assess the stage and severity of a malignant or infiltrating

process. This has become the mainstay of staging malignant disease of the esophagus.

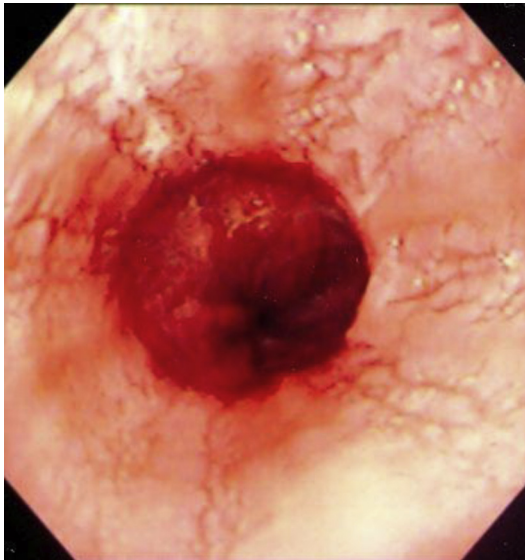
### ***Benign Esophageal Stricture***

---

Benign strictures are by far the most common, and peptic strictures account for 70% to 80% of all causes of esophageal stricture. Peptic strictures are the result of gastroesophageal reflux-induced esophagitis and scarring.<sup>1-4</sup> With this, peptic strictures usually occur in the distal esophagus within 4 cm of the squamocolumnar junction. The associated mucosal inflammation and submucosal fibrosis give an appearance of inflammation and smooth narrowing without mass effect (**Fig. 1**).

Another common cause of benign stricture is a Schotski's ring, a ringlike constriction of the distal esophagus, often described as a "bandlike" ring of constriction. The etiology of a Schotski's ring remains elusive. Theories include that (1) the ring is a pleat of redundant mucosa that forms when the esophagus for unknown reasons shortens transiently or permanently, (2) the ring is congenital, (3) the ring is a short peptic stricture related to GERD, and (4) the ring is the result of pill-induced esophagitis.

The treatment of benign stricture is dilation (see details elsewhere in this article) and management of any underlying inflammatory process.<sup>1-4</sup> The treatment of the underlying cause cannot be overemphasized.<sup>5</sup> Patients on maximum medical therapy for GERD have lower redilation rates and better resolution of dysphagia than those who are not on maximal medical GERD therapy. Twice daily dosing of a proton pump inhibitor is more effective than H2 blockers alone and for patients with breakthrough evening GERD symptoms, adding a single evening dose of an H2 blocker is indicated. This regimen is continued for at least 1 month, at which time a repeat esophagogastroduodenoscopy is undertaken to reassess. It may be necessary to repeat the dilation at that time and continue maximum medical therapy until the stricture and inflammatory process has completely resolved. At that time, medication can be tapered to a level for symptom control and an endoscopy planned for 12 months later.<sup>6</sup> For more severe strictures, this plan may be compressed to repeat endoscopy and



**Fig. 1.** Endoscopic view of severe peptic esophagitis.

dilation within 1 to 2 weeks of an initial dilation, and more frequent reassessments. Adjuncts such as steroid injections in and around the stricture have been used, especially for more chronic fibrotic strictures. Stenting (see elsewhere in this article) has little role in benign strictures unless the underlying issue with the stricture is anastomotic breakdown and leak from a recent esophageal procedure (which is beyond the scope of this article).

Surgery is indicated for peptic stricture that recurs despite maximal medical therapy, in which case an antireflux procedure is indicated, or for nondilatable fibrotic strictures, which typically requires resection and reconstruction to resolve.<sup>7</sup> One should be cautioned about using a segmental resection of the distal esophagus and esophagogastrectomy to manage a benign stricture because the majority of these patients will have severe GERD after such a procedure, leaving the patient with ongoing issues with peptic injury to the esophagus.<sup>8</sup> If a resection is needed, it is best to use an esophagojejunostomy to avoid severe GERD.

### ***Malignant Esophageal Stricture***

---

The most common cause of malignant esophageal stricture is adenocarcinoma associated with Barrett's esophagus. This is a change from decades ago when most malignant disease of the esophagus was squamous cancer associated with alcohol and tobacco use. The management of malignant stricture centers on tissue diagnosis, staging, and definitive therapy versus palliation. In contrast with benign strictures, dilation plays only a temporizing role, typically to facilitate placement of a stent or prepare for definitive therapy (resection). Stenting (see elsewhere in this article) is much more common in malignant stricture, either as permanent management for advanced disease or temporary management to allow completion of neoadjuvant therapy before undergoing resection.

### ***Management***

---

#### ***Dilation***

Esophageal dilation<sup>9</sup> for stricture involves selection of technique of dilation, use of adjuncts and endpoint.

#### ***Techniques***

Mercury-filled bougies (Maloney or Hurst dilators) are reasonable for uncomplicated strictures with an initial diameter of greater than 10 mm. These dilators are inexpensive and fluoroscopy is not needed. This is the technique used for self, at-home dilations.

Wire-guided polyvinyl bougies (Savary-Gilliard dilators) are stiff dilators appropriate for strictures 5 to 20 mm in diameter and are best suited for long, tight strictures. Fluoroscopy is typically needed to assess guidewire placement and to visualize safe passage of the dilator. Use usually requires sedation and is more traumatic on the larynx than other techniques of dilation.<sup>10</sup>

Through-the-scope balloon dilators allow visualized placement and dilation. Although more expensive, balloon dilation seems to result in safe management of more complicated and tighter strictures with fewer sessions and a lower recurrence rate.<sup>11</sup>

#### ***Adjuncts***

Intralesional steroid injection and endoscopic stricturoplasty are the 2 most commonly talked about adjuncts to stricture dilation. Although few data exist to support a mechanism of action, the first ventures to decrease the inflammatory reaction to the trauma of dilation and thereby limit the degree of restenosis after dilation. Several studies have achieved larger final luminal diameter and lower stricture recurrence with the use of

intralesional steroid.<sup>12</sup> It seems reasonable to use this in a benign stricture where dysphagia persists despite dilations and maximal medical management of GERD.

Four-quadrant stricturoplasty followed by dilation has been described for more fibrotic strictures with limited success.<sup>13</sup> Concern with stricturoplasty relates to perforation making the fibrotic strictures most appealing for this adjunct.

### ***Endpoint of Dilation***

---

How much dilation can be achieved in a single session of dilation, and what luminal diameter should be the goal remain controversial. Most would agree that gaining 1 to 2 mm of luminal diameter through 3 consecutive passes of dilators of increasing size during 1 session is a good general rule. Use of balloon dilators may allow even more increase in luminal diameter during a session. Obviously, perforation remains the concern, and balloon dilation provides real-time, direct visualization of the mechanical effects of the dilation and may allow more aggressive, safe dilation. Most patient experience complete relief of dysphagia when a luminal diameter of 40 to 54F is achieved.

### ***Stenting***

---

Stenting for esophageal structure is used most commonly for malignant strictures, either to provide permanent palliation for advanced disease or temporary palliation while a patient is treated with neoadjuvant therapy in preparation for curative resection.<sup>14,15</sup> Permanent stents are usually self-expanding metal or plastic stents, and temporary stents have the stent itself covered so as to limit tissue ingrowth, allowing the stent to be removed more easily. The details of stent design and placement are beyond the scope of this article.

### ***Surgery***

---

Finally, surgery has a primary role for a malignant stricture where staging reveals a potentially curable cancer. In this case, esophagectomy with either high thoracic or cervical esophageal anastomosis to tubularized stomach or colon interposition is preferred. Distal esophageal segmental resection with esophagogastrectomy should be avoided owing to the severe GERD that often results with the LES gone and an intrathoracic anastomosis to stomach. If it is desirable to preserve as much esophagus as possible, it is better to use jejunum for reestablishing intestinal continuity.

The role of surgery in benign stricture is largely limited to antireflux procedures to manage the GERD that is etiologic in most benign strictures. For a nondilatable benign stricture, segmental resection is reasonable so long as an esophagojejunostomy is performed rather than an esophagogastrostomy (see elsewhere in this article).

## **ESOPHAGEAL DIVERTICULA**

An esophageal diverticulum is an epithelial-lined mucosal pouch that protrudes from the esophageal lumen.<sup>16</sup> Esophageal diverticula are classified according to their location (pharyngoesophageal, midesophageal, or epiphrenic), the layers of the esophagus that accompany them (true diverticulum, which contain all layers, or false diverticulum, containing only mucosa and submucosa), or mechanism of formation (pulsion or traction; **Table 1**). Most esophageal diverticula are pulsion diverticula and are the consequence of a dysfunctional esophageal sphincter that fails to open appropriately, resulting in pressurization of the esophageal lumen forcing the mucosa and submucosa to herniate through the esophageal musculature (false diverticulum). Pharyngoesophageal and epiphrenic diverticula are pulsion diverticula. Less

Diverticulum	Location	Mechanism	Type
Pharyngoesophageal	UES	Pulsion	False
Midesophageal	Tracheal bifurcation	Traction	True
Epiphrenic	Distal esophagus	Pulsion	False

Abbreviation: UES, upper esophageal sphincter.

commonly, a periesophageal inflammatory process adheres to the esophagus and subsequently pulls the esophageal wall focally, resulting in all layers of the esophagus comprising the diverticulum (true diverticulum). Midesophageal diverticula are usually traction diverticula resulting from inflammatory changes in mediastinal lymph nodes.

### ***Pharyngoesophageal Diverticulum (Zenker's)***

In 1878, Zenker described 27 cases of pharyngoesophageal diverticulum, and thus his name is associated with this condition. This is the most common of the esophageal diverticula. Pharyngoesophageal diverticula consistently arise within the inferior pharyngeal constrictor, between the oblique fibers of the thyropharyngeus muscle and through or above the more horizontal fibers of the cricopharyngeus muscle (the upper esophageal sphincter; Fig. 2). Killian's triangle is the area of weakness through which most pharyngoesophageal diverticula protrude. These diverticula seem to be acquired owing to some degree of incoordination in the swallowing mechanism with

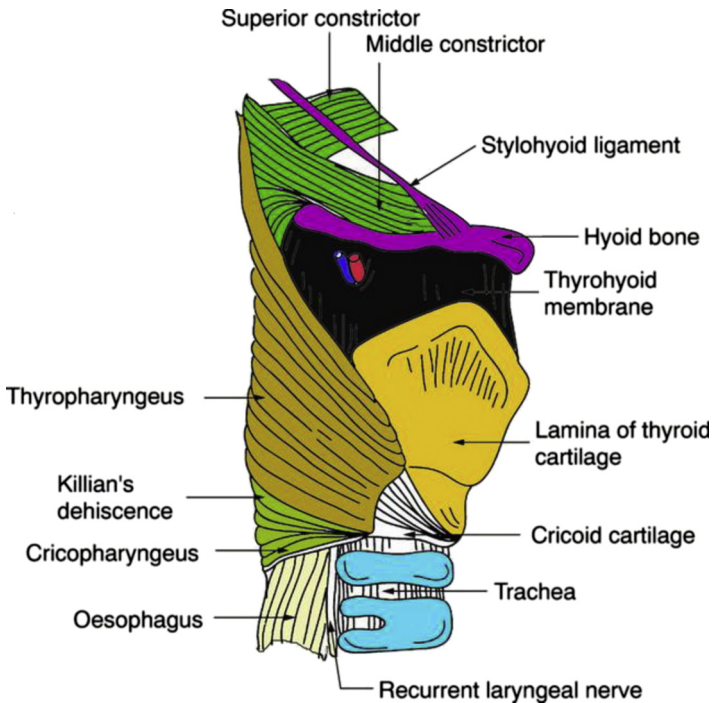


Fig. 2. Anatomy of location of pharyngoesophageal diverticula.

an abnormally high intrapharyngeal pressure leading to protrusion of esophageal mucosa and submucosa through the esophageal wall with subsequent diverticulum formation.

### **Diagnosis**

---

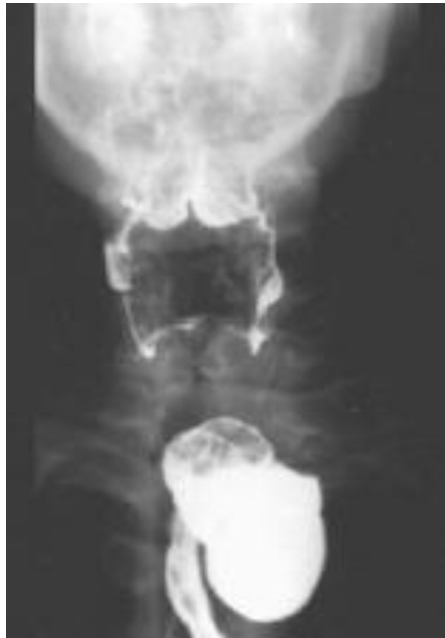The presenting symptoms of pharyngoesophageal diverticulum are usually characteristic, and consist of cervical esophageal dysphagia, regurgitation of bland undigested food, frequent aspiration, noisy deglutition (gurgling), halitosis, and voice changes. Dysphagia is present in 98% of patients, and pulmonary aspiration occurs in up to one-third of patients.

The diagnosis of pharyngoesophageal diverticulum is made easily with a barium esophagram (Fig. 3). Endoscopy, 24-hour pH monitoring, and esophageal manometry are not indicated unless some features of the symptoms or the esophagram raise suspicion of other conditions (malignancy or GERD). Although these diverticula can reach impressive sizes, it is the degree of upper esophageal sphincter dysfunction that determines the severity of symptoms, not the absolute size of the diverticulum. In most symptomatic cases, treatment is indicated regardless of the size of the diverticulum.

### **Treatment**

---

As is the case with all pulsion diverticula, proper treatment must be directed at relieving the underlying neuromotor abnormality responsible for the increased intraluminal pressure and then managing the diverticulum.<sup>17</sup> Most techniques described have used division of the cricopharyngeus muscle followed by resection, imbrication, obliteration, or fenestration of the diverticulum (Table 2). Most approaches to management agree that relief of the relative obstruction distal to the pouch through cricopharyngeal myotomy is the most important aspect of treatment. Early surgical



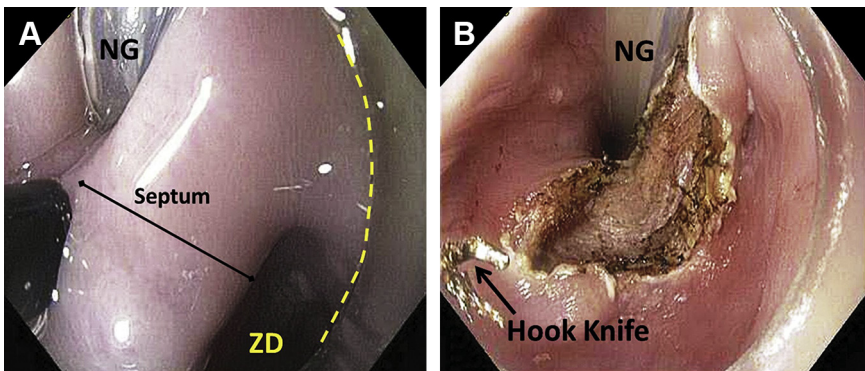
**Fig. 3.** Barium esophagram showing pharyngoesophageal diverticulum.

Treatment	Description
Endoscopic diverticulotomy	Endoscopic division of cricopharyngeus and common wall between diverticulum and esophagus (electrocautery, stapler, laser, etc)
Operative myotomy and diverticulectomy	Cricopharyngeal myotomy and excision of diverticulum
Operative myotomy and diverticulopexy	Cricopharyngeal myotomy and mobilization of sac with suture fixation of the sac above the neck of the diverticulum
Operative myotomy alone	Cricopharyngeal myotomy only

strategies using diverticulectomy only, without myotomy, had high failure rates because of esophageal leaks from the suture line, or recurrence. More recently, endoscopic management has emerged as the preferred method of managing these diverticula (ref). Dividing the septum between the esophagus and diverticulum and the cricopharyngeus muscle using either an energy device (eg, cautery, laser; Fig. 4) or a stapling device (Fig. 5) allows a minimally invasive approach that both addresses the cricopharyngeus muscle and the trapping of content in the diverticulum. The typical advanced age of many who suffer with this condition also makes the endoscopic approach appealing. Success is achieved in more than 90% of patients undergoing endoscopic management with a low morbidity and mortality. Twenty percent of patients may require 2 treatments to achieve these results.<sup>18–21</sup>

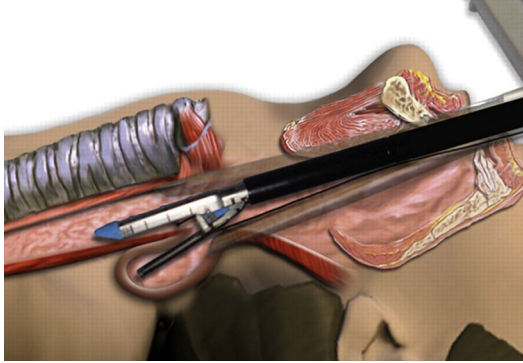
### **Midesophageal Diverticulum**

Midesophageal diverticula are rare and most commonly associated with mediastinal granulomatous disease (histoplasmosis or tuberculosis). They are thought to arise because of adhesions between inflamed mediastinal lymph nodes and the esophagus. By contraction, the adhesions exert “traction” on the esophagus with eventual localized diverticulum development. These are true diverticula with all layers of the esophagus present in the diverticulum.



**Fig. 4.** Endoscopic management of pharyngoesophageal diverticulum. Yellow dashes indicate lateral edge of diverticulum. (A) Endoscopic view before diverticulotomy. NG, nasogastric tube in esophagus; ZD, lumen of Zenker's diverticulum. (B) Completed diverticulotomy.





**Fig. 5.** Stapled endoscopic management of pharyngoesophageal diverticulum.

### ***Diagnosis/treatment***

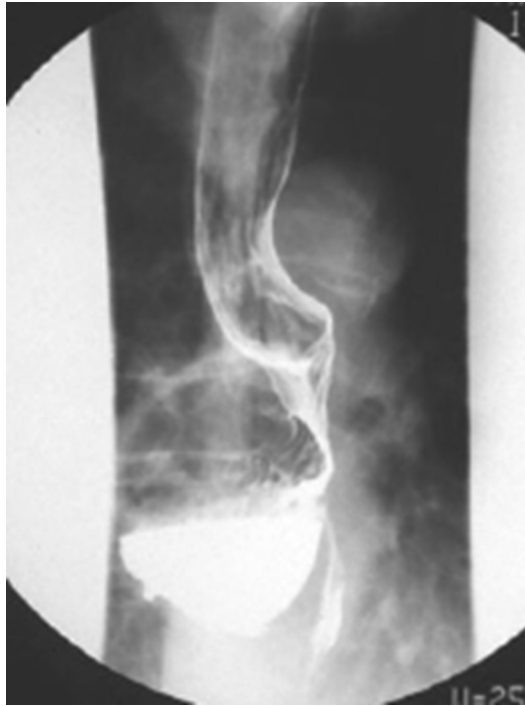A midesophageal diverticulum is typically asymptomatic and diagnosed incidentally on a barium esophagram undertaken for other reasons. When such an asymptomatic diverticulum is found, no treatment is necessary. In patients with symptoms, esophageal manometry is indicated to ensure that the LES function is normal and that there is not a pulsion diverticulum. Symptomatic diverticula require treatment. Larger diverticula usually require an accompanying resection or diverticulopexy. In the absence of a motor abnormality, diverticulectomy alone may be adequate. Many surgeons will add an esophagogastric myotomy (Heller myotomy) for any esophageal diverticulectomy to minimize the risk of staple line leak that may accompany any early postoperative esophageal lumen pressurization. Data in the literature are mixed related to the requirement of esophagogastric myotomy for true traction diverticula.<sup>22,23</sup> It is this author's preference to add an esophagogastric myotomy (Heller myotomy) myotomy to all cases where esophageal diverticulectomy is indicated (of course, not including pharyngoesophageal diverticula).

### ***Epiphrenic (Pulsion) Diverticulum***

An epiphrenic diverticulum typically occurs within the distal 10 cm of the esophagus and is a pulsion type. It is most commonly associated with esophageal motor abnormalities (achalasia, hypertensive LES, diffuse esophageal spasm, nonspecific motor disorders), but may be the result of other causes of increased esophageal pressure (eg, after fundoplication with esophageal outflow obstruction). I have managed several epiphrenic diverticula in patients who have undergone endoluminal fundoplication, in particular transoral incisionless fundoplication, where the esophageal wall has been weakened by the transmural fixation and outflow obstruction has allowed pressurization of the esophagus above and at the fundoplication with subsequent diverticulum formation.

### ***Diagnosis/treatment***

Most epiphrenic diverticula are symptomatic because of the underlying esophageal motor disorder. Diagnosis of the diverticulum is made during barium esophagram (**Fig. 6**). Manometry, esophagoscopy, and 24-hour pH testing may be necessary to diagnose associated conditions and direct specific treatments. Most epiphrenic diverticula require esophageal myotomy extending from the neck of the diverticulum



**Fig. 6.** Barium esophagram showing a large epiphrenic diverticulum.

onto the gastric cardia for a distance of 1.5 to 3.0 cm (see Myotomy for Achalasia). Diverticulectomy, fundoplication, or repair of hiatal hernia may also be necessary, depending on the size of the diverticulum or associated conditions.

#### ***Technique of midesophageal and epiphrenic diverticulectomy***

In the past, an open thoracic approach has been the preferred approach to these diverticula. Today, a laparoscopic or combined laparoscopic/thoracoscopic approach allows a minimally invasive approach to these diverticula, significantly decreasing the morbidity and mortality of management of these diverticula (ref). If the neck of the diverticulum is above the esophageal hiatus and/or the diverticulum itself is very large and extends up into the chest, the operation commences with a thoracoscopic approach. Prone thoracoscopy<sup>24</sup> significantly facilitates mobilization of the diverticulum (**Figs. 7** and **8**) and stapled transection of the neck (**Figs. 9** and **10**). Once the diverticulum is resected, the patient is flipped into the supine position for laparoscopic esophagogastric myotomy and partial fundoplication. If the neck of the diverticulum is at the level of the esophageal hiatus and the diverticulum does not extend far into the chest, an entirely laparoscopic approach may be adequate. As we have gained experience with prone thoracoscopy, we now approach most epiphrenic diverticula with the combined thoracoscopic/laparoscopic approach.

Several series have documented the feasibility of this approach.<sup>25,26</sup> We have experience in the management of more than 40 cases using laparoscopic/thoracoscopic approach. As stated, we prefer to add an esophagogastric myotomy to all cases to minimize the risk of staple line leak postoperatively.<sup>27</sup>

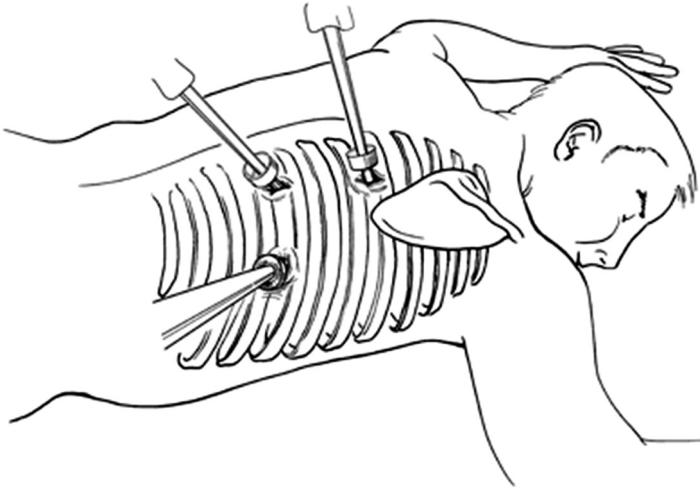


Fig. 7. Illustration of prone thoracoscopy used to approach mid- and large epiphrenic diverticula.

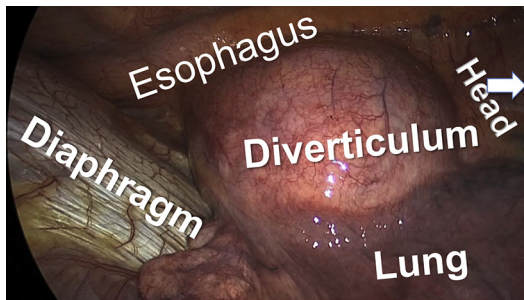


Fig. 8. Prone thoroscopic view of epiphrenic diverticulum.

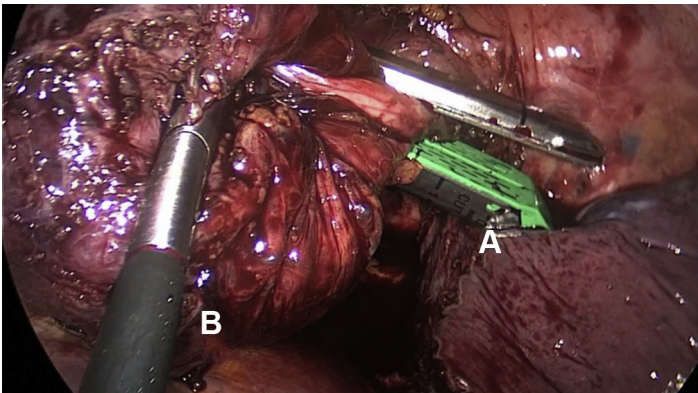
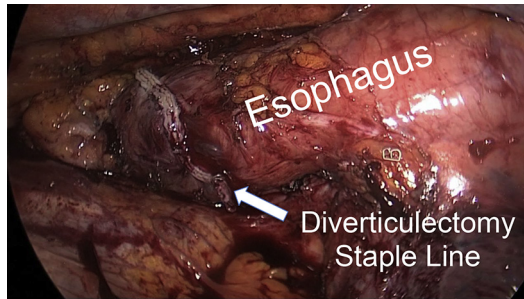


Fig. 9. Prone thoroscopic view of diverticulum neck being transected with stapler. (A) Stapler across diverticulum neck. (B) Grasper holding diverticulum.



**Fig. 10.** Completed diverticulectomy.

## REFERENCES

1. Pregun I, Hritz I, Tulassay Z, et al. Peptic esophageal stricture: medical treatment. *Dig Dis* 2009;27:31–7.
2. Pace F, Antinori S, Repici A. What is new in esophageal injury (infection, drug-induced, caustic, stricture, perforation)? *Curr Opin Gastroenterol* 2009;25:372–9.
3. Guda NM, Vakil N. Proton pump inhibitors and the time trends for esophageal dilation. *Am J Gastroenterol* 2004;99:797–800.
4. Marks RD, Richter JE, Rizzo J, et al. Omeprazole versus H<sub>2</sub>-receptor antagonists in treating patients with peptic stricture and esophagitis. *Gastroenterology* 1994; 106:907–15.
5. Dakkak M, Hoare RC, Maslin SC, et al. Oesophagitis is as important as oesophageal stricture diameter in determining dysphagia. *Gut* 1993;34:152–5.
6. Patterson DJ, Graham DY, Smith JL, et al. Natural history of benign esophageal stricture treated by dilatation. *Gastroenterology* 1983;85:346–50.
7. Smith CD. Antireflux surgery. *Surg Clin North Am* 2008;88:943–58.
8. Smith CD. Surgical therapy for gastroesophageal reflux disease: indications, evaluation, and procedures. *Gastrointest Endosc Clin N Am* 2009;19:35–48, v–vi.
9. de Wijkerslooth LR, Vleggaar FP, Siersema PD. Endoscopic management of difficult or recurrent esophageal strictures. *Am J Gastroenterol* 2011;106:2080–91 [quiz: 2092].
10. Fan Y, Song HY, Kim JH, et al. Fluoroscopically guided balloon dilation of benign esophageal strictures: incidence of esophageal rupture and its management in 589 patients. *AJR Am J Roentgenol* 2011;197:1481–6.
11. Saeed ZA, Winchester CB, Ferro PS, et al. Prospective randomized comparison of polyvinyl bougies and through-the-scope balloons for dilation of peptic strictures of the esophagus. *Gastrointest Endosc* 1995;41:189–95.
12. Ramage JI Jr, Rumalla A, Baron TH, et al. A prospective, randomized, double-blind, placebo-controlled trial of endoscopic steroid injection therapy for recalcitrant esophageal peptic strictures. *Am J Gastroenterol* 2005;100:2419–25.
13. Raijman I, Siddique I, Rachcal LT. Endoscopic stricturoplasty in the management of recurrent benign esophageal strictures. *Gastrointest Endosc* 1999; 49:AB172.
14. Sharma P, Kozarek R. Practice Parameters Committee of American College of G. Role of esophageal stents in benign and malignant diseases. *Am J Gastroenterol* 2010;105:258–73 [quiz: 274].
15. Hindy P, Hong J, Lam-Tsai Y, et al. A comprehensive review of esophageal stents. *Gastroenterol Hepatol (N Y)* 2012;8:526–34.

16. Smith CD. Esophagus. In: Norton JA, Chang AE, Lowry SF, et al, editors. *Essential practice of surgery basic science and clinical evidence*. New York: Springer - Verlag; 2003. p. 167–84.
17. Zaninotto G, Narne S, Costantini M, et al. Tailored approach to Zenker's diverticula. *Surg Endosc* 2003;17:129–33.
18. Tang SJ. Flexible endoscopic Zenker's diverticulotomy: approach that involves thinking outside the box (with videos). *Surg Endosc* 2014;28:1355–9.
19. Parker NP, Misono S. Carbon dioxide laser versus stapler-assisted endoscopic Zenker's diverticulotomy: a systematic review and meta-analysis. *Otolaryngol Head Neck Surg* 2014;150:750–3.
20. Law R, Baron TH. Transoral flexible endoscopic therapy of Zenker's diverticulum. *Dig Surg* 2013;30:393.
21. Huberty V, El Bacha S, Blero D, et al. Endoscopic treatment for Zenker's diverticulum: long-term results (with video). *Gastrointest Endosc* 2013;77:701–7.
22. Isaacs KE, Graham SA, Berney CR. Laparoscopic transhiatal approach for resection of midesophageal diverticula. *Ann Thorac Surg* 2012;94:e17–9.
23. Galata CL, Bruns CJ, Pratschke S, et al. Thoracoscopic resection of a giant mid-esophageal diverticulum. *Ann Thorac Surg* 2012;94:293–5.
24. Goldberg RF, Bowers SP, Parker M, et al. Technical and perioperative outcomes of minimally invasive esophagectomy in the prone position. *Surg Endosc* 2013;27:553–7.
25. Herbella FA, Patti MG. Modern pathophysiology and treatment of esophageal diverticula. *Langenbecks Arch Surg* 2012;397:29–35.
26. Soares RV, Montenovolo M, Pellegrini CA, et al. Laparoscopy as the initial approach for epiphrenic diverticula. *Surg Endosc* 2011;25:3740–6.
27. Melman L, Quinlan J, Robertson B, et al. Esophageal manometric characteristics and outcomes for laparoscopic esophageal diverticulectomy, myotomy, and partial fundoplication for epiphrenic diverticula. *Surg Endosc* 2009;23:1337–41.