

## Increased Right Ventricular Wall Thickness in Left Ventricular Pressure Overload: Echocardiographic Determination of Hypertrophic Response of the "Nonstressed" Ventricle

JOHN S. GOTTDIENER, MD, FACC, JUDITH A. GAY, BARRY J. MARON, MD, FACC,  
ROSS D. FLETCHER, MD, FACC

Washington, D.C.

Left ventricular hypertrophy in left ventricular pressure overload occurs in response to excessive work load imposed on the left ventricle by increased impedance to ejection. Right ventricular hypertrophy may occur in patients with these findings, but has been considered to be secondary to pulmonary hypertension. To determine the frequency of right ventricular hypertrophy and its relation to increased left ventricular wall thickness in patients with left ventricular pressure overload, right ventricular wall thickness was measured using M-mode echocardiography with two-dimensional echocardiographic guidance in 65 patients with left ventricular pressure overload; 49 patients had essential hypertension and 16 had aortic valve stenosis. These measurements were compared with data from 13 patients with "thin-walled" dilated cardiomyopathy and 20 normal subjects.

Average right ventricular wall thickness in hypertensive patients ( $7 \pm 2$  mm) and patients with aortic stenosis ( $6 \pm 2$  mm) was significantly greater than that in normal

subjects ( $4 \pm 1$  mm) and patients with dilated cardiomyopathy ( $4 \pm 1$  mm) who had normal left ventricular wall thickness, even though left ventricular mass was increased in all patient groups. Increased right ventricular wall thickness was present in 40 (80%) of 49 patients with hypertension and 10 (63%) of 16 patients with aortic stenosis. The magnitude of increase in right ventricular wall thickness was linearly correlated ( $r = 0.76$ ,  $p < 0.005$ ) with left ventricular wall thickness, but was not associated with pulmonary hypertension.

It is concluded that increased right ventricular wall thickness 1) is common in patients with left ventricular pressure overload, 2) is directly related to increases in left ventricular wall thickness, and 3) is independent of right ventricular hypertension. Therefore, undefined factors other than pressure overload may be the stimulus for increases in thickness of the ventricular walls.

(*J Am Coll Cardiol* 1985;6:550-5)

Left ventricular hypertrophy in response to pressure overload of the left ventricle has been well described in electrocardiographic and M-mode and two-dimensional echocardiographic studies (1-4). However, relatively little attention has been focused on the anatomic response of the right ventricle in patients with increased impedance to left ventricular ejection. To assess right ventricular wall thickness in patients with systolic overload of the left ventricle, we performed M-mode and two-dimensional echocardiography in patients with systemic hypertension and aortic stenosis to determine the frequency of increased right ventricular

wall thickness and its association with clinical and hemodynamic descriptors in patients with echocardiographic evidence of increased left ventricular wall thickness. Additionally we sought to compare right ventricular wall thickness in patients with "concentric" (5) left ventricular hypertrophy (thickened left ventricular walls and normal or slightly increased left ventricular cavity size) with that in patients with "eccentric" hypertrophy (normal wall thickness but increased left ventricular mass consequent to cavity dilation). Therefore, we also measured right ventricular wall thickness in patients with dilated cardiomyopathy.

From the Cardiology Section, Medical Service, Veterans Administration Medical Center, Georgetown University School of Medicine, Washington, D.C. This study was supported by the Veterans Administration, Washington, D.C. Manuscript received March 8, 1984; revised manuscript received March 27, 1985, accepted April 11, 1985.

Address for reprints: John S. Gottdiener, MD, Cardiology Section 688/151D, Veterans Administration Medical Center, 50 Irving Street, N.W. 4A106, Washington, D.C. 20422.

### Methods

**Patient selection.** *Hypertension.* Patients evaluated at the Washington Veterans Administration Medical Center from 1980 to 1983 were selected using the following criteria: sustained systolic hypertension of 140 mm Hg or greater

and the presence of left ventricular wall thickness in excess of 12 mm shown on an echocardiogram. This patient group comprised 49 men with an average age of  $60 \pm 9$  (SD) years (range 33 to 80), who before therapy had an average systolic blood pressure of  $170 \pm 30$  mm Hg (range 140 to 196). Patients were selected from individuals followed up for hypertension in the medical clinics at the Washington Veterans Administration Hospital in whom echocardiograms had been performed for definition of cardiac response to hypertension. All patients were receiving antihypertensive therapy at the time of study and had had hypertension diagnosed for at least 2 to 13 years (average 8) previously.

In 13 of the 49 patients with systemic hypertension, cardiac catheterization had been performed because of suspected coronary artery disease. Right ventricular systolic pressures were compared with the echocardiographic data in this subgroup. In addition, of the patients with systemic hypertension who did not undergo cardiac catheterization, none had evidence of pulmonary hypertension on physical examination, chest X-ray film, electrocardiogram or echocardiogram.

**Aortic stenosis.** Sixteen patients (12 men, 4 women) with aortic stenosis confirmed by the presence of 30 mm Hg or greater peak systolic gradient at cardiac catheterization were also studied. The average age of these patients was  $51 \pm 18$  years (range 17 to 77). The average peak systolic gradient for the group was  $73 \pm 33$  mm Hg (range 24 to 129) and the average left ventricular systolic pressure was  $197 \pm 24$  mm Hg (range 170 to 240). Most of these echocardiograms were obtained before routine measurement of right ventricular wall thickness from the subcostal acoustic window. Therefore, only those values obtained from the parasternal view are described.

**Dilated cardiomyopathy.** For purposes of comparison, 13 patients with dilated cardiomyopathy characterized by left ventricular dilation (end-diastolic dimension  $60 \pm 5$  mm), decreased systolic function (fractional shortening  $17 \pm 6\%$ ) and normal left ventricular wall thickness, but with increased left ventricular mass on echocardiogram were studied. The average age of these patients was  $56 \pm 6$  years (range 43 to 59) and the average systolic blood pressure was  $132 \pm 10$  mm Hg (range 110 to 150).

**Normal subjects.** Right ventricular wall thickness was also measured in 20 normal men with an average age of  $54 \pm 14$  years (range 25 to 80) who had no evidence of heart disease by history, physical examination, electrocardiogram or echocardiogram. The average systolic blood pressure for this group was  $126 \pm 14$  mm Hg (range 106 to 140).

**Echocardiography.** Two-dimensional echocardiography was performed using a Varian 3400 or Dasonics 3400R phased-array ultrasonograph with studies recorded on  $\frac{3}{4}$  inch (18 cm) cassette tape. M-mode recordings of the right

ventricular wall (6,7) were obtained by placing the M-mode cursor, during the two-dimensional imaging of the heart in both parasternal and subcostal acoustic windows, at or distal to the tips of the tricuspid valve leaflets (Fig. 1), taking particular care to avoid placing the M-mode cursor through the papillary muscles, right ventricular muscle bands or crista supraventricularis. In each case the cursor was perpendicular or near perpendicular ( $\leq 30^\circ$ ) to the right ventricular wall so that oblique sections through the wall were not measured. Adequate damping of near field echoes was ensured to allow optimal visualization of right ventricular wall epicardial and endocardial echoes. The right ventricular wall thickness was measured just before atrial systole. Measurements of the left ventricular septal and posterior wall thicknesses, and cavity dimensions were made according to techniques previously described (8). For the purpose of this study the septal and posterior wall thicknesses were averaged and expressed as the left ventricular wall thickness. Left ventricular mass was estimated by the method of Troy et al. (9).

**Statistical analysis.** Data are expressed as mean values  $\pm$  standard deviation. Intergroup comparisons were made using a one-way analysis of variance and the Student's *t* test. Linear regression was performed according to the left squares method.

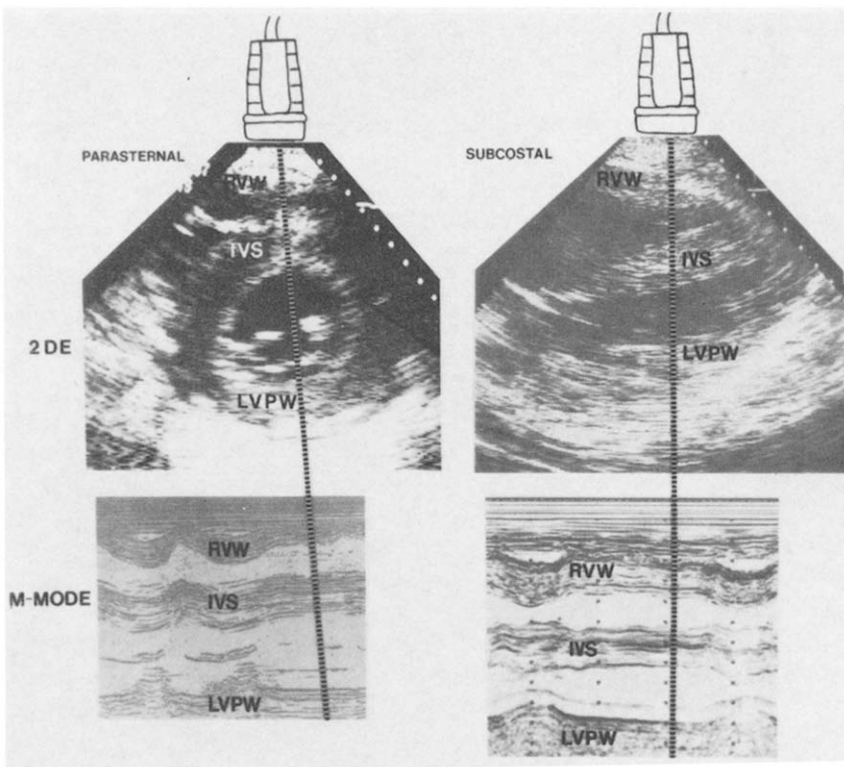
## Results

**Normal subjects.** In normal subjects (Table 1), the average right ventricular wall thickness measured from the parasternal window was  $4 \pm 1$  mm (range 3 to 5). As observed by others (7), right ventricular wall thickness measured from the subcostal window ( $6 \pm 1$  mm, range 4 to 7) was somewhat greater than that measured from the parasternal window.

**Systemic hypertension.** In patients with systemic hypertension, the average right ventricular free wall thickness measured from the parasternal view was  $7 \pm 2$  mm (range 3 to 13) and was significantly ( $p < 0.005$ ) greater than the right ventricular wall thickness in normal subjects (Fig. 2). Forty of the 49 patients with hypertension and increased left ventricular wall thickness had right ventricular wall thickness greater than that measured in any normal subject.

*In 22 evaluable patients, the right ventricular wall thickness obtained from the subcostal approach (average  $13 \pm 2$  mm, range 9 to 16) was greater than that measured from the parasternal view and provided complete separation of hypertensive patients from normal subjects (Fig. 3).*

*To test the hypothesis that increased right ventricular wall thickness in patients with systemic hypertension is related to pulmonary hypertension, right ventricular systolic pressure (average  $26 \pm 8$  mm Hg) was compared with parasternal right ventricular wall thickness (average  $7 \pm 2$  mm) determined by echocardiography (Fig. 4) in 13 pa-*



**Figure 1.** Echocardiograms illustrating position of M-mode cursor to obtain recording of right ventricular wall (RVW) thickness from two-dimensional echocardiographic (2DE) view in parasternal and subcostal positions. IVS = interventricular septum; LVPW = left ventricular posterior wall.

tients. Of these 13 patients, 8 had a right ventricular systolic pressure of 30 mm Hg or less; 7 of these 8 patients nonetheless had increased right ventricular wall thickness of 6 mm or greater (average 9, range 6 to 10). Of note, 12 of the 13 catheterized patients had a systemic left ventricular systolic pressure of 140 mm Hg or greater and increases in both left ventricular and right ventricular wall thickness. Only four of these had pulmonary hypertension, and in these four, the pulmonary artery systolic pressure was only minimally elevated (<40 mm Hg).

**Aortic stenosis.** In patients with aortic stenosis the average right ventricular free wall thickness measured from the parasternal view of  $6 \pm 2$  mm (range 2 to 9) was significantly ( $p < 0.01$ ) greater than that of  $4 \pm 1$  mm

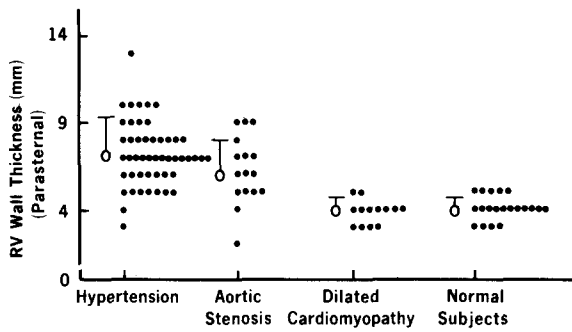
measured in normal subjects (Fig. 2). In addition, 9 (56%) of the 16 patients had right ventricular wall thickness in excess of 5 mm, the greatest value measured in any normal subject. A significant linear correlation ( $r = 0.68$ ,  $p < 0.005$ ) was observed between right and left ventricular wall thickness. However, linear regression analysis showed only a poor correlation between left ventricular systolic peak pressure (average  $197 \pm 24$  mm Hg) and left ventricular wall thickness ( $r = 0.53$ ,  $p < 0.05$ ).

Of note, 6 of the 16 patients with aortic stenosis had a right ventricular systolic pressure less than 30 mm Hg; 4 of these 6 nonetheless had substantial right ventricular wall thickening (Fig. 4) in excess of 5 mm (average 8, range 6 to 9). Eight other patients with a right ventricular pressure

**Table 1.** Results in 98 Cases

Diagnosis	No. of Pts	Age (yr)	RVWTp (mm)	RVWTs (mm)	RVSP (mm Hg)	LVSP (mm Hg)	LVWT (mm)	LVM (g)
Hypertension	49	$60 \pm 9$	$7 \pm 2^*$	$13 \pm 2^*$	$26 \pm 8^\dagger$	$170 \pm 30^*$	$17 \pm 2^*$	$445 \pm 113^*$
Aortic stenosis	16	$51 \pm 18$	$6 \pm 2^*$	—	$33 \pm 8$	$197 \pm 24^*$	$16 \pm 2^*$	$453 \pm 113^*$
Cardiomyopathy	13	$56 \pm 6$	$4 \pm 1$	$5 \pm 2$	—	$132 \pm 10$	$11 \pm 1$	$428 \pm 112^*$
Normal	20	$54 \pm 14$	$4 \pm 1$	$6 \pm 1$	—	$126 \pm 14$	$11 \pm 1$	$248 \pm 52$

\* $p < 0.01$  in comparison with normal subjects;  $^\dagger$ measured in 13 patients only. LVM = left ventricular mass; LVSP = peak left ventricular systolic pressure (estimated by cuff blood pressure in normal subjects and patients with hypertension and cardiomyopathy); LVWT = average of left ventricular septal and posterior wall thicknesses; Pts = patients; RVSP = peak right ventricular systolic pressure; RVWTp = right ventricular wall thickness measured from a parasternal window; RVWTs = right ventricular wall thickness measured from a subcostal window.



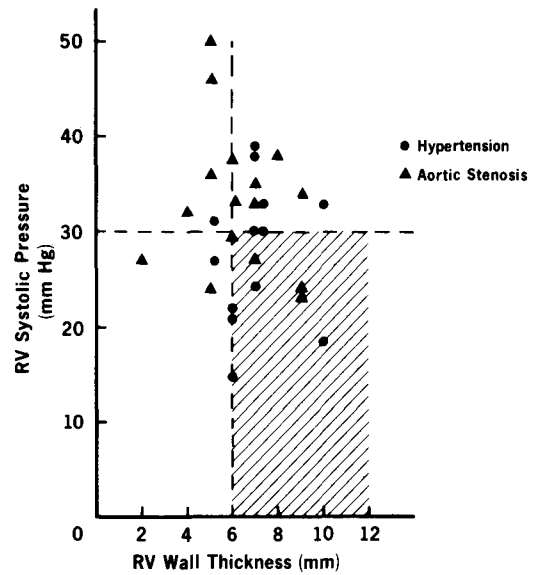
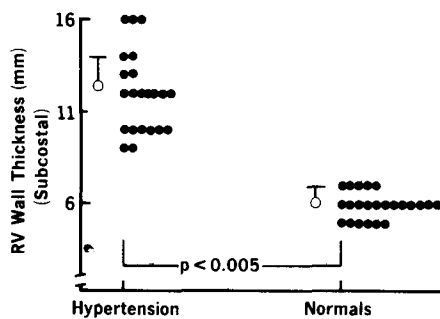
**Figure 2.** Right ventricular (RV) wall thickness obtained from the parasternal view in patients with hypertension, compared with patients with aortic stenosis, dilated cardiomyopathy and normal subjects. Right ventricular wall thickness is significantly greater in patients with hypertension or aortic stenosis than in normal subjects or patients with dilated cardiomyopathy.

of 32 to 38 mm Hg (average 34) had a right ventricular wall thickness ranging from 4 to 9 mm (average 7). In contrast, two patients with a right ventricular systolic pressure of 46 and 50 mm Hg, respectively, had a wall thickness of only 5 mm. Left ventricular mass was increased, comparable with that of patients with hypertension.

*Relation of right and left ventricular wall thickness.* The relation of right to left ventricular wall thickness for patients with aortic stenosis or hypertension and normal subjects is shown in Figure 5. There was a linear relation ( $r = 0.76$ ,  $p < 0.005$ ) between the magnitude of increase in right and left ventricular wall thickness.

**Dilated cardiomyopathy.** In patients with dilated cardiomyopathy the average right ventricular wall thickness measured from the parasternal window of  $4 \pm 1$  mm (range 3 to 5) was identical to that measured in normal subjects. Right ventricular wall thickness measured from the subcostal window (average  $5 \pm 1$  mm, range 4 to 6) also did not differ significantly from that measured in normal subjects. Although left ventricular wall thickness (average  $11 \pm 1$  mm, range 8 to 12) was normal in these patients, the estimated left ventricular mass of  $428 \pm 112$  g was substantially greater than that of normal subjects (average

**Figure 3.** Right ventricular (RV) wall thickness measured from the subcostal view is greater than that measured from the parasternal view for both normal subjects and hypertensive patients, with complete separation of groups.



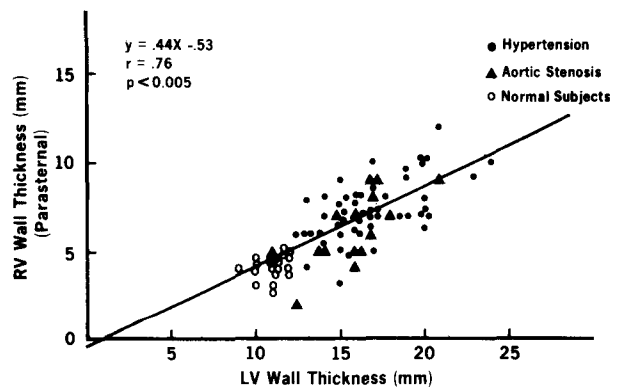
**Figure 4.** Relation of right ventricular (RV) wall thickness to right ventricular systolic pressure in 13 patients with hypertension and 16 patients with aortic stenosis. In addition to poor coefficient of correlation ( $r = 0.20$ ), note that seven of eight patients with hypertension and four of six patients with aortic stenosis with right ventricular systolic pressure of 30 mm Hg or less nonetheless had an abnormally thickened right ventricular wall.

$248 \pm 52$  g) and comparable with that in patients with aortic stenosis ( $453 \pm 113$  g) and hypertension ( $445 \pm 113$  g).

## Discussion

The results of our study indicate that increased right ventricular wall thickness is common in patients with left ventricular pressure overload who also have increased left ventricular wall thickness without cavity dilation, that is, "concentric hypertrophy," (5) on echocardiogram. In addition, the presence of increased right ventricular wall thick-

**Figure 5.** Relation of right ventricular (RV) and left ventricular (LV) wall thickness, showing significant linear correlation ( $r = 0.76$ ) in normal subjects, patients with aortic stenosis and patients with hypertension.



ness is not dependent on the occurrence of secondary pulmonary hypertension. Furthermore, the magnitude of increased right ventricular wall thickness is correlated significantly with thickness of the left ventricular wall. In contrast, patients with dilated cardiomyopathy and increased left ventricular mass, but normal left ventricular wall thickness, or "eccentric hypertrophy," (5) do not have increased right ventricular wall thickness.

Our data support those of Rubler et al. (10) in documenting increased right ventricular wall thickness by M-mode echocardiography in patients with left ventricular hypertrophy, and extend these observations by showing a lack of association between right ventricular hypertension and increased right ventricular wall thickness. In addition, we noted a significant correlation between right and left ventricular wall thickness not found by these investigators. This difference in results may be related to methodologic factors and patient selection. Our study used two-dimensional echocardiography to guide M-mode recording of the right ventricular wall, possibly enhancing our sensitivity in detection of increases in right ventricular thickness. Also, our larger patient sample (65 versus 31 patients) with greater left ventricular wall thickness (17 versus 15 mm), may, in part, account for the observed differences.

**Differences in right ventricular wall thickness measurements.** It is uncertain why right ventricular wall thickness measured from the epigastric (subcostal) window was consistently greater than that measured from the parasternal window. Obliqueness of the M-mode cursor and inclusion of papillary muscles are two factors that may produce greater apparent thickness of the right ventricular wall recorded from the subcostal window than from the parasternal window. However, the right ventricular cavity and walls are morphologically complex. While the echocardiogram records an apparently smooth, continuous interface between right ventricular wall and blood, the right ventricular wall is in fact heavily trabeculated, and muscle bands, papillary muscles and chordae tendineae may lie in proximity to the right ventricular free wall. Therefore, the echocardiographic wall thickness is not necessarily a direct anatomic representation of the actual right ventricular wall. Conceivably, dense trabeculation would likely be incorporated within the echocardiographically determined thickness of the right ventricular wall. Differences in the extent of trabeculation of the lateral aspect of the right ventricular wall, imaged from the epigastric window, and the anterior aspect of the right ventricular wall, imaged from the parasternal window, could account for the differences in echocardiographic wall thickness observed from these two positions. While attempts were made to limit the obliquity of the M-mode cursor through the right ventricular wall, this may also have contributed to exaggeration of measurements made from the subcostal position.

**Limitations of the study.** As noted, we are uncertain about the reasons for differences in right ventricular wall

measurements from the subcostal in comparison with the parasternal position; trabeculae and possibly papillary muscle in addition to free wall may have been included, particularly in right ventricular wall measurements from the subcostal position. Nonetheless, a hypertrophic response of myocardium likely includes all of its architectural components. Therefore, since the method of recording and measuring right ventricular wall thickness was the same for patients and normal subjects, the increased right ventricular wall thickness measurements in patients with concentric left ventricular hypertrophy represent a true hypertrophic response of the right ventricular myocardium.

Although our data showed no association between increased right ventricular wall thickness and the presence of pulmonary hypertension, it is possible that in some patients initial elevations of pulmonary artery pressure were lowered by antihypertensive therapy. However, of the patients with hypertension who had cardiac catheterization, most still had elevated systemic blood pressure suggesting inadequate therapy or patient noncompliance. In addition, all patients with aortic stenosis were studied before aortic valve replacement. Hence, unrelieved left ventricular overload was present in these patients despite the presence of increased left ventricular wall thickness without significant right ventricular pressure overload in most.

#### **Findings in experimentally induced hypertrophy.**

Our findings are supported by prior documentation of hypertrophy of the nonstressed ventricle in experimentally induced ventricular overload. Overloading of the left ventricle in experimental animals has been accompanied by augmented biochemical and hemodynamic function of the nonstressed right ventricle (11) and by right as well as left ventricular hypertrophy (12). Furthermore, pulmonary artery banding of dogs, in addition to producing increased right ventricular hypertrophy, results in increased mass and stiffness of the nonstressed left ventricle (13). Experimental hypertrophy may also cause increased synthesis of connective tissue in the nonstressed ventricle, as indicated by increases in the concentration and total content of hydroxyproline in both the stressed right ventricle and unstressed left ventricle of cats undergoing pulmonary artery constriction (14).

**Mechanisms.** While functional and morphologic interdependence of the ventricles appears to be well documented, the mechanism or mechanisms by which this occurs is uncertain. Elevation of right ventricular diastolic pressure in response to increased left ventricular volume (15) or mechanical transmission of stress from the left to the right ventricle through common muscle bands (16) is a possibility. Alternatively, a humoral factor may mediate both right and left ventricular hypertrophy in response to pressure overload of either ventricle, and elevation of blood pressure and cardiac hypertrophy may be secondary responses to a primary neurohumoral abnormality in patients with essential hypertension. In support of a possible role of catecholamines

as a mediator of cardiac hypertrophy has been the observation by Laks and Morady (17) that subhypertensive doses of norepinephrine induced left ventricular hypertrophy. Also, Simpson et al. (18) showed that serum from animals with left ventricular hypertrophy, isoproterenol and norepinephrine induce hypertrophy of cardiac myocytes in vitro. Furthermore, there is an increase in circulating epinephrine soon after induction of aortic stenosis in rabbits (19). This latter observation indicated that mechanically induced pressure overload of the left ventricle may result in hypertrophy by neurohumoral mediation. In humans, the reversal of left ventricular hypertrophy after pharmacologic sympathectomy without reduction of blood pressure (20) and the poor correspondence of blood pressure with left ventricular hypertrophy (21) suggest that factors other than arterial pressure may be implicated in the cardiac hypertrophy of essential hypertension (21).

**Conclusion.** The nonstressed right ventricle, in two clinical circumstances of left ventricular pressure overload associated with concentric ventricular hypertrophy, is also thickened in relation to the magnitude of left ventricular wall thickness but not in relation to systolic overload at rest. In contrast, patients with dilated cardiomyopathy who have increased left ventricular mass but no increase in left ventricular wall thickness also have no increase in right ventricular wall thickness. However, because of the right ventricular cavity dilation present in most of these patients, it is reasonable to assume that right ventricular mass is nonetheless increased. Therefore, "eccentric" (5) hypertrophy of the right ventricle probably occurs with "eccentric" left ventricular hypertrophy, as "concentric" right ventricular hypertrophy accompanies "concentric" left ventricular hypertrophy. Whatever the mechanism of increased right ventricular wall thickness in patients with hypertension and aortic stenosis, it is apparent that the stimuli that evoke a hypertrophic response of either ventricle may be complex.

We thank Mary Stevenson and Judy Easterly for their secretarial assistance in the preparation of this manuscript.

## References

1. Safar ME, Lehner JP, Vincent MI, Plainfosse MT, Simon A Ch. Echocardiographic dimensions in borderline and sustained hypertension. *Am J Cardiol* 1979;44:930-5.
2. Savage DD, Drayer J, Henry WL, et al. Echocardiographic assessment of cardiac anatomy and function in hypertensive patients. *Circulation* 1979;59:623-32.
3. Toshima H, Voga Y, Yoshioka H, Akiyoshi T, Kimura N. Echocardiographic classification of hypertensive heart disease. *Jpn Heart J* 1975;16:337-93.
4. Salcedo E, Gockowski K, Tarazi RC. Left ventricular mass and wall thickness in hypertension. Comparison of M-mode and two-dimensional echocardiography in two experimental models. *Am J Cardiol* 1979;44:936-40.
5. Bader HS. Biological significance of cardiac hypertrophy. *Am J Cardiol* 1964;14:133-8.
6. Prakash R, Lindsay P. Determination of right ventricular thickness by echocardiogram. *JAMA* 1978;239:638-40.
7. Tsuda I, Sawayama T, Kawai N, Katoh T, Nezu S, Kikawa K. Echocardiographic measurement of right ventricular wall thickness in adults by anterior approach. *Br Heart J* 1980;44:55-61.
8. Sahn DJ, DeMaria A, Vissio J, Weyman A. Recommendations regarding quantitation in M-mode echocardiography: results of a survey of echocardiographic measurements. *Circulation* 1978;82:1072-82.
9. Troy BL, Pombo J, Rackley CE. Measurement of left ventricular wall thickness and mass by echocardiography. *Circulation* 1972;45:602-11.
10. Rubler S, Halperin MS, Dolgin M, Weart CC, Spitzer M. Right ventricular wall thickness of left ventricular hypertrophy: an echocardiographic study. *J Cardiovasc Ultrasound* 1983;2:63-8.
11. Meerson FZ. Insufficiency of hypertrophied heart. *Basic Res Cardiol* 1976;71:343-54.
12. Pool PE, Piggott WJ, Seagren SC, Skelton C. Augmented right ventricular function in systemic hypertension—induced hypertrophy. *Cardiovasc Res* 1976;10:124-8.
13. Mirsky I, Laks M. Time course of changes in the mechanical properties of the canine right and left ventricles during hypertrophy caused by pressure-overload. *Circ Res* 1980;46:530-42.
14. Buccino RA, Harris E, Spann JF, Sonnenblick EH. Response of myocardial connective tissue to development of experimental hypertrophy. *Am J Physiol* 1969;246:425-7.
15. Bove AA, Santamore WP. Ventricular interdependence. *Prog Cardiovasc Dis* 1981;23:365-87.
16. Grant RP. Notes on the muscular architecture of the left ventricle. *Circulation* 1981;32:301-8.
17. Laks MM, Morady F. Norepinephrine—the myocardial hypertrophy hormone? *Am Heart J* 1976;91:674-5.
18. Simpson P, McGrath S, Savion S. Myocyte hypertrophy in neonatal heart cultures and its regulation by serum and by catecholamines. *Circ Res* 1982;51:787-801.
19. Calderera CM, Casti A, Rossoni C, Visioli O. Polyamines and noradrenaline following myocardial hypertrophy. *J Mol Cell Cardiol* 1971;3:121-6.
20. Fouad FM, Nakashima Y, Tarazi RC, Salcedo EE. Reversal of left ventricular hypertrophy in hypertensive patients treated with methyldopa. *Am J Cardiol* 1979;49:795-801.
21. Frohlich ED, Tarazi RC. Is arterial pressure the sole factor responsible for hypertensive cardiac hypertrophy. *Am J Cardiol* 1979;44:959-62.