

Evidence-Based Recommendations for the Diagnosis and Treatment of Pediatric Acne

AUTHORS: Lawrence F. Eichenfield, MD,^a Andrew C. Krakowski, MD,^a Caroline Piggott, MD,^a James Del Rosso, DO,^b Hilary Baldwin, MD,^c Sheila Fallon Friedlander, MD,^a Moise Levy, MD,^d Anne Lucky, MD,^e Anthony J. Mancini, MD,^f Seth J. Orlow, MD, PhD,^g Albert C. Yan, MD,^h Keith K. Vaux, MD,ⁱ Guy Webster, MD, PhD,^j Andrea L. Zaenglein, MD,^{k,l} and Diane M. Thiboutot, MD^l

^aDivision of Pediatric and Adolescent Dermatology, Rady Children's Hospital, San Diego and Departments of Pediatrics and Medicine (Dermatology), University of California, San Diego, San Diego, California; ^bSection of Dermatology, Valley Hospital Medical Center, Las Vegas, Nevada; ^cDepartment of Dermatology, SUNY Downstate Medical Center, Brooklyn, New York; ^dPediatric/Adolescent Dermatology, Dell Children's Medical Center, Austin, Texas, Department of Dermatology, UT Southwestern Medical School, Dallas, Texas and Departments of Pediatrics and Dermatology, Baylor College of Medicine, Houston, Texas; ^eDepartments of Dermatology and Pediatrics, University of Cincinnati College of Medicine and Cincinnati Children's Hospital Medical Center, Cincinnati, Ohio; ^fDepartments of Pediatrics and Dermatology, Northwestern University Feinberg School of Medicine and Division of Dermatology, Ann & Robert H. Lurie Children's Hospital of Chicago; ^gThe Ronald O. Perleman Department of Dermatology, New York University School of Medicine, New York, New York; ^hSection of Pediatric Dermatology, Children's Hospital of Philadelphia, Philadelphia, Pennsylvania and Departments of Pediatrics and Dermatology, Perelman School of Medicine at the University of Pennsylvania; ⁱDivision of Pediatrics and Hospital Medicine, Rady Children's Hospital, San Diego, California and Department of Pediatrics, University of California, San Diego, California; ^jDepartment of Dermatology, Jefferson Medical College, Thomas Jefferson University, Philadelphia, Pennsylvania; ^kDepartment of Dermatology, The Pennsylvania State University College of Medicine; and ^lDepartment of Pediatrics, Penn State Hershey Children's Hospital, Hershey, Pennsylvania

KEY WORDS

pediatric acne, acne treatment, combination acne therapy, retinoids, benzoyl peroxide, bacterial resistance, isotretinoin, hormonal therapy, acne guidelines, acne algorithm, neonatal acne, infantile acne, mid-childhood acne, preadolescent acne, American Acne and Rosacea Society, AARS

(Continued on last page)

abstract

INTRODUCTION: Acne vulgaris is one of the most common skin conditions in children and adolescents. The presentation, differential diagnosis, and association of acne with systemic pathology differs by age of presentation. Current acknowledged guidelines for the diagnosis and management of pediatric acne are lacking, and there are variations in management across the spectrum of primary and specialty care. The American Acne and Rosacea Society convened a panel of pediatric dermatologists, pediatricians, and dermatologists with expertise in acne to develop recommendations for the management of pediatric acne and evidence-based treatment algorithms.

METHODS: Ten major topic areas in the diagnosis and treatment of pediatric acne were identified. A thorough literature search was performed and articles identified, reviewed, and assessed for evidence grading. Each topic area was assigned to 2 expert reviewers who developed and presented summaries and recommendations for critique and editing. Furthermore, the Strength of Recommendation Taxonomy, including ratings for the strength of recommendation for a body of evidence, was used throughout for the consensus recommendations for the evaluation and management of pediatric acne. Practical evidence-based treatment algorithms also were developed.

RESULTS: Recommendations were put forth regarding the classification, diagnosis, evaluation, and management of pediatric acne, based on age and pubertal status. Treatment considerations include the use of over-the-counter products, topical benzoyl peroxide, topical retinoids, topical antibiotics, oral antibiotics, hormonal therapy, and isotretinoin. Simplified treatment algorithms and recommendations are presented in detail for adolescent, preadolescent, infantile, and neonatal acne. Other considerations, including psychosocial effects of acne, adherence to treatment regimens, and the role of diet and acne, also are discussed.

CONCLUSIONS: These expert recommendations by the American Acne and Rosacea Society as reviewed and endorsed by the American Academy of Pediatrics constitute the first detailed, evidence-based clinical guidelines for the management of pediatric acne including issues of special concern when treating pediatric patients. *Pediatrics* 2013;131:S163–S186

Acne vulgaris is one of the most common skin conditions in children and adolescents. Although often considered a disease of teenagers, in whom the prevalence is reported to be from 70% to 87%,¹ 12 years of age is no longer considered the lower end of the age range for acne onset.² A study by Lucky et al³ revealed acne lesions in 78% of 365 girls ages 9 to 10. In addition, acne and other acneiform (acnelike) conditions occur at different ages, including neonates, infants, and young children, and may be associated with differential diagnoses or systemic pathology that differs from teenagers.

There are issues of special concern in treatment of preadolescents with acne. The majority of clinical trials for acne medications are conducted in patients 12 years of age or older. As a result, there is little published evidence regarding the safety and efficacy of many acne medications in pediatric patients. Furthermore, the treatment of acne often involves use of several medications that target either different types of acne lesions, different factors involved in the pathogenesis of acne, or different degrees of acne severity. Potential interactions between medications can add another layer of complexity to the management of acne in pediatric patients, as can concerns about systemic side effects and impact of medications on growth and development. The psychosocial impact of acne can be significant, as can issues of adherence to treatment regimens.

Currently, detailed, acknowledged guidelines for the diagnosis and management of acne in pediatric patients are lacking. Recognizing the need to address special issues regarding the diagnosis and treatment of acne in children of various ages, a panel of experts consisting of pediatric dermatologists, pediatricians, and dermatologists with expertise in acne was convened under the auspices of the

American Acne and Rosacea Society, a nonprofit organization promoting research, education, and improved care of patients with acne and rosacea. The expert panel was charged with developing recommendations for the management of pediatric acne and evidence-based treatment algorithms. A member of the expert panel served as liaison to the American Academy of Pediatrics and as part of the recommendation writing group.

METHODS

The expert panel identified special issues in the diagnosis and treatment of acne and acneiform conditions in pediatric patients across various ages. Ten major topic areas were specified by the panel (Table 1). A thorough English-language literature search was performed for each topic area, and identified articles were reviewed utilizing a patient-centered approach to grading evidence available to the expert panel.⁴ Relevant clinical trial registries and data filed with the Food and Drug Administration (FDA) were included in the data review.

TABLE 1 Topic Areas Researched and Discussed by Expert Panel

Pediatric Acne Categorization and Differential Diagnosis of Acne
Evaluation of Pediatric Acne by Age/Classification
Evidence-based Treatment Review for Pediatric Acne
<ul style="list-style-type: none"> • OTC products • BP treatment • Topical retinoids, antibiotics, and fixed-dose combination products • Oral antibiotics: age-related issues, safety, and resistance • Isotretinoin pediatric patients with severe acne • OC use and hormonal therapy
Pediatric Acne Treatment Considerations
<ul style="list-style-type: none"> • Previous treatment history • Costs • Ease of use/regimen complexity and adherence • Vehicle selection • Active scarring • Side effects • Psychosocial impact • Diet

Each topic area was assigned to 2 expert reviewers, who developed and presented an in-depth summary and recommendations for further critique and editing. The Strength of Recommendation (SOR) Taxonomy ratings for the recommendation for a body of evidence is noted throughout the article.⁴ This taxonomy addresses the quality, quantity, and consistency of evidence and allows authors to rate individual studies or bodies of evidence. The taxonomy emphasizes the use of patient-oriented outcomes that measure changes in morbidity or mortality. The authors reviewed the bodies of evidence for each of the recommendations and assigned one of the following SOR: an A-level recommendation is based on consistent and good-quality patient-oriented evidence; a B-level recommendation is based on inconsistent or limited-quality patient-oriented evidence; and a C-level recommendation is based on consensus, usual practice, opinion, disease-oriented evidence, or case series for studies of diagnosis, treatment, prevention, or screening. This article summarizes the resultant consensus recommendations for the evaluation and diagnosis of pediatric acne, as well as a series of treatment algorithms to assist health care practitioners in the management and treatment of acne in pediatric patients.

CATEGORIZATION AND DIFFERENTIAL DIAGNOSIS OF PEDIATRIC ACNE

Both age and form of presentation are relevant to the diagnosis of pediatric acne. Although there is some overlap in age and presentation of acneiform conditions, the consensus of the panel regarding relevant age categories is presented in Table 2. These ranges are approximate. In girls, age of onset of menarche may be a better delineating point between preadolescence and

TABLE 2 Expert Panel Consensus: Pediatric Acne Categorized by Age

Acne Type	Age of Onset
Neonatal	Birth to ≤ 6 wk
Infantile	6 wk to ≤ 1 y
Mid-childhood	1 y to < 7 y
Preadolescent	≥ 7 to ≤ 12 y or menarche in girls
Adolescent	≥ 12 to ≤ 19 y or after menarche in girls

adolescence. In general, acne is uncomplicated by systemic disease, but in some cases it may be a cutaneous manifestation of underlying pathology. It is essential to have a broad understanding of acne at different ages and to be aware of the differential diagnoses for each age group. Table 3 presents a differential diagnosis for acne in each age group.^{5–7} Workup is based on age and physical findings.⁶ The physical examination should focus on type and distribution of acne lesions, height, weight, growth curve, and possible blood pressure abnormalities. Signs of precocious sexual maturation or virilization should prompt workup and/or a referral to a pediatric endocrinologist.⁸

Consensus Recommendation:

- Acneiform eruptions from the neonatal period through adolescence may be broadly categorized by age and pubertal status.

Neonatal Acne

Neonatal acne is estimated to affect up to 20% of newborns.⁹ The major controversy in this age group is whether the lesions truly represent acne or one of a number of heterogeneous papulopustular acneiform conditions typically without comedones, such as neonatal cephalic pustulosis (NCP) or transient neonatal pustular melanosis. Although rare, some neonates may present with androgen-driven comedonal and inflammatory acne.^{8,10} NCP pustules are usually confined to the

cheeks, chin, eyelids, and forehead, but the scalp, neck, and upper chest and back may be involved.⁸ Its pathogenesis may involve colonization with *Malassezia* species, a normal commensal of infant skin, or may represent an inflammatory reaction to a yeast overgrowth at birth.^{8,10} NCP is typically mild and self-limited, and reassuring the parents is usually the only management needed. If lesions are numerous, 2% ketoconazole cream may reduce fungal colonization.¹¹ Newborns also may present with or develop transient neonatal pustular melanosis, with pustules on the chin, neck, or trunk. Within 24 hours, these pustules rupture, leaving hyperpigmented macules with a rim of faint white scale.¹⁰

Consensus Recommendation:

- Neonates may have true acne, although many self-limited papulopustular eruptions also occur on the faces of neonates. In infants and younger children (< 7 years of age) with significant acne vulgaris, evaluation for signs of sexual precocity, virilization, and/or growth abnormalities that may indicate an underlying systemic abnormality (endocrinologic diseases, tumors, gonadal/ovarian pathology) and appropriate workup and/or referral to a pediatric endocrinologist may be warranted. (SOR: C).

Infantile Acne

Infantile acne may begin at ~ 6 weeks of age and last for 6 to 12 months or, rarely, for years. It is more common in boys and presents with comedones as well as inflammatory lesions, which can include papules, pustules, or occasionally nodular lesions. Physical examination should include assessment of growth including height, weight, and growth curve; testicular growth and breast development; presence of hirsutism or pubic hair; clitoromegaly; and increased muscle

mass.¹² Should workup for a hormonal anomaly be considered, a pediatric endocrinology referral and/or bone age and serologic evaluation of follicle-stimulating hormone, luteinizing hormone, testosterone, and dehydroepiandrosterone sulfate levels are recommended. No further workup is necessary for the majority of cases in the absence of hormonal abnormalities. It is also important to distinguish true infantile acne from other similar cutaneous lesions, because there is some evidence that infantile acne predisposes to more severe adolescent acne.¹³ Infantile acne may be treated with topical antimicrobial agents; topical retinoids; noncycline antibiotics, such as erythromycin; and, occasionally, isotretinoin, though all are without FDA indication for use in this age group.

Consensus Recommendation:

- Most infantile acne is self-limited and not associated with underlying endocrine pathology. However, in patients with additional physical signs of hormonal abnormality, a more extensive workup and/or referral to a pediatric endocrinologist may be appropriate. (SOR: C).

Mid-Childhood Acne

Mid-childhood acne presents primarily on the face with a mixture of comedones and inflammatory lesions.¹⁰ Children between the ages of 1 and 7 years, however, do not normally produce significant levels of adrenal or gonadal androgens; hence, acne in this age group is rare. When it does occur, an endocrine abnormality should be suspected. A workup by a pediatric endocrinologist is usually warranted to rule out adrenal or gonadal/ovarian pathology including the presence of androgen-secreting tumors. Increased bone age and accelerated growth, as evidenced by deviation from standardized age-appropriate growth curves, are important indicators of the effects

TABLE 3 Differential Diagnosis of Acne in Younger Pediatric and Adolescent Patients

Adolescent (~12–18 y of age)
Corticosteroid-induced acne
Demodex folliculitis
Gram-negative folliculitis
Keratosis pilaris
Malassezia (pityrosporum) folliculitis
Papular sarcoidosis
Perioral dermatitis
Pseudofolliculitis barbae
Tinea faciei
Preadolescent (≥7 to ≤12 y of age)
Acne venenata or pomade acne (from the use of topical oil-based products)
Angiofibromas or adenoma sebaceum
Corticosteroid-induced acne
Flat warts
Keratosis pilaris
Milia
Molluscum contagiosum
Perioral dermatitis
Syringomas
Mid-Childhood (1–7 y of age)
Adrenal tumors
Congenital adrenal hyperplasia
Cushing syndrome
Gonadal tumors
Ovarian tumors
PCOS
Premature adrenarche
True precocious puberty
Any Age
Acne venenata or pomade acne (from the use of topical or oil-based products)
Bilateral nevus comedonicus
Chlorinated aromatic hydrocarbons (chloracne)
Corticosteroids (topical, inhaled, and oral)
Demodicidosis
Facial angiofibromas (tuberous sclerosis)
Flat warts
Infections (bacterial, viral, and fungal)
Keratosis pilaris
Medication-Induced (anabolic steroids, dactinomycin, gold, isoniazid, lithium, phenytoin, and progestins)
Milia
Miliaria
Molluscum contagiosum
Periorificial dermatitis
Rosacea

Adapted from Tom and Friedlander⁶ and Krakowski and Eichenfield.⁷

of excess androgens. In addition to treatments to address androgen-secreting tumors or congenital adrenal hyperplasia, the treatment of mid-childhood acne is similar to that of adolescent acne except that oral tetracyclines are usually not an option in children younger

than 8 years of age because of the risk of damage to developing bones and tooth enamel. Hormonal therapy could be used if warranted by endocrinologic pathology.⁸

Consensus Recommendation:

- Mid-childhood acne is very uncommon and should warrant an endocrinologic workup for causes of hyperandrogenism. (SOR: C).

Preadolescent Acne

It is not uncommon for acne vulgaris to occur in preadolescents, as a result of normal adrenarche and testicular/ovarian maturation. Acne may be the first sign of pubertal maturation.⁹ In fact, with the trend toward earlier age of onset of adrenarche and menarche, there appears to be a downward shift in the age at which acne first appears. Preadolescent acne is characterized by a predominance of comedones on the forehead and central face (the so-called “T-zone”) with relatively few inflammatory lesions.¹⁰ Early presentation may include comedones of the ear.

History and physical examination are the most important parts of the assessment in this age group. Further workup is generally unnecessary unless there are signs of excess androgens.⁷ Polycystic ovary syndrome (PCOS) or another endocrinologic abnormality may be considered when the acne is unusually severe, accompanied by signs of excess androgens, or is unresponsive to treatment.¹⁴ Pelvic ultrasound is not considered useful for diagnosis of PCOS because it is non-specific.

Treatment of uncomplicated preadolescent acne is comparable to that of acne in older age groups, as discussed later. It is important in this age group to elicit the patient's level of concern regarding his or her acne, which may not always be concordant with parental concern.

Consensus Recommendation:

- Preadolescent (7–12 years) acne is common and may precede other signs of pubertal maturation. Workup beyond history and physical is generally unnecessary unless there are signs of androgen excess, PCOS, or other systemic abnormalities. (SOR: B).

PEDIATRIC ACNE CLASSIFICATION AND SEVERITY ASSESSMENT

In general, treatment of pediatric acne vulgaris is similar to acne treatment in older adolescents and adults and is based on acne pathophysiology. The pathogenesis of acne involves the interplay of 4 factors: sebaceous hyperplasia under the influence of increased androgen levels, alterations in follicular growth and differentiation, colonization of the follicle by *Propionibacterium acnes* (*P acnes*), and consequent immune response and inflammation.¹⁵

A useful clinical categorization of acne is based on predominate morphology: comedonal with closed and open comedones (“whiteheads” and “blackheads”); inflammatory, with erythematous papules, nodules, or cystlike nodular lesions; or mixed, where both types of lesions are present. The micro-comedo is the not-clinically-apparent precursor of both comedonal and inflammatory lesions. It is a product of hyperactive sebaceous glands and altered follicular growth and differentiation. Reduction in existing microcomedones and prevention of the formation of new ones is central to the management of all acne lesions.¹⁶

Comedones form as a result of increased cell division and cohesiveness of cells lining the follicular lumen. When these cells accumulate abnormally, mix with sebum, and partially obstruct the follicular opening, they form a closed comedo (whitehead). If the follicular opening is larger, the keratin buildup is

more visible and can darken to form an open comedo (blackhead). Follicular colonization with *P acnes* leads to inflammation via the production of inflammatory mediators and the formation of inflammatory papules and pustules. Nodular acne is characterized by a predominance of large inflammatory nodules or pseudocysts and is often accompanied by scarring or the presence of sinus tracts when adjacent nodules coalesce.

Acne severity may be classified clinically as mild, moderate, or severe based on the number and type of lesions and the amount of skin involved. Although there are numerous grading systems by which to define acne severity, there is no agreed-upon standard, and interpretation is subjective. Many grading systems are most useful for research purposes. For clinical purposes, simplicity is key. Typically, patients' assessments do not correlate well with either those of physicians or published severity scales.¹⁷ The panel noted that severity scales frequently overemphasize inflammatory lesions. For example, in some research settings, a patient might be classified as having mild acne because he or she has only a few inflammatory lesions in the presence of hundreds of closed comedones. In such cases, the patient (and the physician) is more likely to consider his or her acne to be severe. Determination of severity can be modified by extent of involvement and scarring as well.

Although some acne may resolve without residual changes, inflammatory acne may result in the formation of significant scars. In darker skin, post-inflammatory hyperpigmentation (PIH) is common. Residual erythema can occur as well. These changes are most often reversible but can take many months to fully resolve. Recognizing these as secondary changes is important when determining the efficacy of

treatment as patients may not recognize the improvement or think they have scarring. Effective and early treatment is essential to prevent scarring as well as postinflammatory changes and to limit the long-term physical and psychological impact of acne.

It has been repeatedly demonstrated that acne can have a significant adverse impact on quality of life, and that the level of distress may not correlate directly with acne severity.^{18,19} In 1 study, assessments using several quality of life instruments revealed deficits for acne patients who did not correlate with clinical assessments of severity.²⁰ Reported social, psychological, and emotional symptoms were as severe as those reported by individuals with chronic asthma, epilepsy, diabetes, and back pain or arthritis. Adolescents, in particular, may be insecure about their appearance and vulnerable to peer opinions. Because social functioning and quality-of-life decrements may not correlate with disease severity, even mild acne may be more troubling to young patients than they are willing to admit.²¹

Consensus Recommendation:

- Acne can be categorized as predominantly comedonal, inflammatory, and/or mixed. Presence or absence of scarring, PIH, or erythema should be assessed. Severity may be broadly categorized as mild, moderate, or severe. (SOR: A).

APPROACH TO PEDIATRIC ACNE THERAPY

The therapeutic objectives in acne are to treat as many age-appropriate pathogenic factors as possible by reducing sebum production, preventing the formation of microcomedones, suppressing *P acnes*, and reducing inflammation to prevent scarring.

Although no single acne treatment, apart from isotretinoin, addresses all 4 pathogenic factors, it is now clear that many of the medications traditionally used to treat acne actually act by more than 1 mechanism. In addition to targeting the largest number of pathogenic factors, the approach to pediatric acne should be to use the least aggressive regimen that is effective while avoiding regimens that encourage the development of bacterial resistance. Educating a patient (and parents) about reasonable expectations of results and discussing management of treatment-related side effects can maximize both compliance and efficacy.

Numerous medications are available to treat acne. Design of an effective regimen is facilitated by an increased understanding of the mechanisms of action, the side effect profile, and the indications and contraindications of key antiacne agents discussed later.

OVER-THE-COUNTER TREATMENT OPTIONS

Nationwide television commercials and magazine ads abound with over-the-counter (OTC) products. Although largely untested in controlled clinical trials, many of these products are considered somewhat effective, particularly for patients with mild acne. Those which have been tested include salicylic acid-containing topical products and many benzoyl peroxide (BP) products described in further detail later. Salicylic acid has revealed some efficacy in acne trials, although when tested head-to-head with other topicals, particularly BP, it is generally less effective.^{22,23} Nonprescription, nonbenzoyl-peroxide-containing products appear to be somewhat effective for the treatment of acne, especially mild acne, though there is limited published evidence supporting their efficacy in the treatment of acne.

Sulfur, sodium sulfacetamide, and resorcinol are active ingredients in

several OTC dermatology niche products. Sulfur exhibits mild antibacterial and keratolytic properties.²⁴ Because of sulfur's distinctive odor, it is often combined with sodium sulfacetamide to mask the scent.²⁵ It is often used in adult female acne because of its favorable tolerability.^{26,27} Resorcinol also has mild antimicrobial properties and is typically formulated in a 2% concentration in combination with 5% sulfur.

One common acne myth is that poor hygiene and improper cleansing cause acne.^{21,28} The role of facial cleansing in acne is to remove makeup, dirt, and excess oil.²⁹ Use of the wrong, too harsh cleanser can disrupt skin barrier, increase transepidermal water loss, encourage bacterial colonization, promote comedones, and cause symptoms of burning and stinging.^{30,31} Typically, twice-daily washing with a gentle soap-free, pH-balanced cleanser is recommended. Antibacterial washes, other than BP, have not been shown to be useful in the treatment of acne.

Facial toners can decrease oiliness and remove makeup and traces of dirt. They are a common component of several prepackaged combination acne treatment regimens. Patients should be cautious not to overuse facial toners because they can be irritating. If irritation occurs, this will adversely affect the tolerability of acne medications.

Another common acne myth is that use of cosmetics worsens acne. On the contrary, use of concealing oil-free, noncomedogenic makeup can improve patient quality of life and does not worsen the severity of acne.^{32,33} Use of cosmetics in patients with acne has not been shown to delay treatment response either.

BP has been shown to be the most widely studied of OTC products and has shown to be one of the most versatile, safe, inexpensive, and effective acne therapies.^{34,35} Its lipophilic nature per-

mits it to penetrate the stratum corneum and enter the pilosebaceous unit where *P. acnes* resides. It acts via the generation of free radicals that oxidize proteins in the *P. acnes* cell wall. It also has been shown to have mild comedolytic³⁶ and antiinflammatory properties.^{37,38} BP helps limit the development of *P. acnes* resistance to antibiotics and also provides increased efficacy in combination with retinoids.^{39,40} So far, antibiotic resistance to BP has not been reported.^{41–44}

Although issues regarding genotoxicity have been raised in the past, BP has now been labeled as “GRASE” (generally regarded as safe and effective) by the FDA, and all topical monotherapy products have been made available OTC since 2011. Labeling includes advice to avoid the eyes, lips, and mouth. The product can cause bleaching of hair and clothing, and risk of increased sunburn and the need for photoprotection also are mentioned. BP frequently causes dryness, erythema, and peeling upon initiation of treatment. Starting with lower concentrations (eg, 2.5%) and utilizing more emollient vehicles if needed can help alleviate these discomforts. Allergic contact dermatitis to BP occurs in 1 in 500 people and should be considered if a patient complains of itching and swelling of the eyes.

BP is available in a variety of formulations and in concentrations ranging from 2.5% to 10%. There is some evidence that higher concentrations do not increase efficacy but are more irritating. However, the back may be a “special site” circumstance, where increasing concentration or prolonged contact leads to increased efficacy.⁴⁵ Formulations include a variety of topical leave-on preparations as well as washes that permit patients to remove BP from the skin, reducing the possibility of bleaching of clothing, bedding, or towels.³⁸ It has been suggested that

short-contact BP therapies do not significantly reduce bacterial load, but data are lacking. However, they can be effective if left on the skin for the duration recommended by the manufacturer.

Consensus Recommendations:

- BP is generally regarded as a safe and effective medication that may be used as monotherapy or in topical combination products for mild acne or in regimens of care for acne of all types and severities. (SOR: A).
- BP may minimize development of antibiotic-resistant *P. acnes* when used with topical or systemic antibiotics. (SOR: C).

PRESCRIPTION TREATMENT OPTIONS: SINGLE AGENTS

Topical Retinoids

Topical retinoids, as monotherapy and in topical combination products, are used routinely for the treatment of acne vulgaris. Their safety and efficacy are well documented in large pivotal trials that included pediatric patients ranging from 12 to 18 years of age. Subsequently, because acne routinely presents in patients younger than 12 years of age, topical retinoids are widely used off-label in this age group. Tretinoin gel 0.05% (Atralin, Coria Laboratories, Fort Worth, TX) is FDA-approved for use in children ≥ 10 years of age,⁴⁶ and adapalene and benzoyl peroxide gel 0.1%/2.5% (Epiduo, Galderma Laboratories, LP, Fort Worth, TX) is indicated for ages 9 and older. Adapalene gel, tretinoin gel, and tretinoin microsphere gel have been investigated in both open-label and blinded studies in children under 12 years of age.^{47–49}

Retinoids normalize desquamation of the follicular epithelium, thus preventing the formation of new microcomedones, precursors to both comedonal and inflammatory lesions, and also promote the clearing of existing microcomedones.⁵⁰

In addition, some topical retinoids also have direct antiinflammatory activity.^{43,51,52} At present, 3 topical retinoids (tretinoin, adapalene, and tazarotene) are available by prescription in the United States. Each is available in a variety of formulations and concentrations (Table 4).⁵³ Their most common adverse effects include burning, stinging, dryness, and scaling.¹⁵ These effects may be reduced by initiating treatment with the lowest strength, typically sufficient to treat mild acne, or by recommending regular use of a moisturizer. Patients should be instructed not to spot-treat but rather to use a pea-size amount to cover the entire face. In patients with sensitive skin, therapy can be initiated with thrice-weekly application, increasing to daily use as tolerated.⁴⁸

Tolerability may be further improved by the use of a noncomedogenic moisturizer that includes a sunscreen.^{15,58} Topical tretinoin was the first retinoid approved for use in the United States. It is available in a variety of vehicles such as a micronized gel or a polymerized cream for increased tolerability. In a 12-week open-label study of 40 patients with mild/moderate acne ages 8 to 12 years (mean age, 10.7 years), tretinoin microsphere gel 0.04% produced a significant decrease in Evaluator's Global Severity Score ($P < .001$) from baseline to week 12, with 75% of participants graded as almost clear or mild. Skin irritation occurred in 35% of the patients but was mild in most cases and improved by study's end.⁴⁸

Other topical retinoid alternatives to tretinoin include adapalene and tazarotene. Adapalene, a distinct retinoid that is generally well tolerated, is available in cream, gel, and lotion formulations.^{53,54} Adapalene is photostable, including in fixed-combination with BP.⁵⁵

Although studies regarding the use of topical retinoids in pediatric patients

TABLE 4 Formulations and Concentrations of Topical Retinoids

Retinoid	Formulation ^a	Strength, %	Pregnancy Category
Tretinoin	Cream	0.025, 0.05, 0.1	C
	Gel	0.01, 0.025	
	Gel (micronized)	0.05	
	Microsphere gel	0.04, 0.1	
	Polymerized cream	0.025	
	Polymerized gel	0.025	
Adapalene	Cream	0.1	C
	Gel	0.1, 0.3	
	Solution	0.1	
	Lotion	0.1	
Tazarotene	Gel	0.05, 0.1	X
	Cream	0.05, 0.1	

Adapted from Imahiyerobo-Ip and Dinulos.⁵²

^a Numerous generic retinoids are available. Branded products are available under the following trade names: Atralin, Avita, and Retin-A Micro for tretinoin; Differin for adapalene; and Tazorac for tazarotene.

are extremely rare in the literature, in a 16-week study of 12 infants with infantile acne (mean age, 12.6 months), 0.1% adapalene cleared both comedonal and inflammatory lesions in a median of 3.4 months with side effects that did not require discontinuation, underscoring the reported high tolerability of adapalene.⁴⁷ Tazarotene is an effective topical retinoid, but it is used less often as a first-line agent for acne because of concerns regarding tolerability; it is also known to be more irritating.⁵⁶

In the absence of significant systemic absorption of the active ingredients, the possibility of intolerance remains the primary safety issue. However, older girls who may be of childbearing potential are often of the age group treated with topical retinoids. Naturally circulating endogenous retinoids are present in the plasma of normal healthy girls as a result of dietary consumption of foods such as fish, carrots, sweet potatoes, and red peppers. Continuous daily dosing of tretinoin 0.1% cream, tazarotene 0.1% gel, and adapalene 0.1% gel has been shown to only slightly increase the mean maximum plasma levels of circulating retinoids in most patients. In 1 study, serum retinoid levels were found to be more heavily influenced by dietary intake than by topical application of tretinoin. In

a study of 215 women accidentally exposed to topical tretinoin during the first trimester of pregnancy, Jick et al⁵⁷ showed no difference in developmental anomalies compared with 430 age-matched controls. Tretinoin and adapalene have a pregnancy category C and tazarotene a category X rating.

Consensus Recommendation:

- Topical retinoids (tretinoin, adapalene, tazarotene) may be used as monotherapy or in combination products and in regimens of care for all types and severities of acne in children and adolescents of all ages. (SOR adolescents: A; SOR pre-adolescents and younger: B).

Antibiotics/Antimicrobials

Although acne is not an infection, antibiotics reduce *P acnes* colonization of the skin and follicles. They are effective in acne both by inhibiting bacterial protein synthesis⁵⁸ and by decreasing inflammation via inhibition of bacterial proinflammatory mediators and decreasing neutrophil chemotaxis.^{58,59}

The alarming increase in *P acnes* resistance to both topical and systemic antibiotics used to treat acne not only renders these drugs less effective against acne but may also influence commensal bacteria in both the acne

patient and his or her environment.⁶⁰ Resistance may occur with both appropriate and incorrect use of antibiotics.⁵⁸

Topical Antibiotics

Topical antibiotic monotherapy is not recommended because of both its slow onset of action and the greater likelihood of the development of bacterial resistance. If topical or oral antibiotic treatment is to be prolonged more than a few weeks (as is usually the case in acne treatment), topical BP should be added to optimize efficacy via its non-specific antimicrobial activity and reduce the emergence of less sensitive *P acnes* variants.⁶⁰ It has even been suggested that, if antibiotic therapy is maintained for more than 3 months, a BP washout should occur between courses, although no large studies have addressed this recommendation.¹⁵

Use of topical antibiotics in fixed-combination products containing BP may help reduce the emergence of antibiotic-resistant strains of bacteria. In the case of the fixed-combination of tretinoin and clindamycin, concomitant use of BP is recommended.

Consensus Recommendation:

- Topical antibiotics (clindamycin, erythromycin) are not recommended as monotherapy because of slow onset of action and predictable emergence of antibiotic-resistant bacterial organisms. (SOR: C). If topical antibiotic treatment is to be prolonged for more than a few weeks, topical BP should be added, or used in combination products. (SOR: C).

Oral Antibiotics

Interestingly, with the exception of extended-release minocycline, use of oral antibiotics in acne is not FDA approved.⁶¹ Extended-release minocycline dosed at 1 mg/kg per day

(administered as 1 tablet daily) is FDA approved for the treatment of moderate to severe inflammatory acne vulgaris that is not predominantly nodular in patients ≥ 12 years of age.⁶² Both immediate-release doxycycline and immediate-release minocycline have listed the indication in their FDA-approved labeling of adjunctive use for severe acne, although this was not based on formal submission for FDA approval for either drug.^{63,64} The commonly used oral antibiotics for children older than 8 years are tetracycline derivatives, including tetracycline, doxycycline, and minocycline. Although erythromycin was used successfully in the past, the worldwide prevalence of *P acnes* resistance to erythromycin has led to decreased use of this agent, both orally and topically, for acne.^{60,65,66} Comparative studies are limited, but the second-generation tetracyclines, doxycycline and minocycline, are preferred because of pharmacokinetic advantages allowing for once-daily administration in most cases, greater lipophilicity that is believed to augment follicular penetration, and lower prevalence of resistant *P acnes* strains as compared with tetracycline.^{15,67,68} For children under 8 years of age and those with tetracycline allergies, alternative oral antibiotic agents, including erythromycin, azithromycin, and trimethoprim/sulfamethoxazole, should be used very judiciously because of the potential risk for severe adverse reactions, such as toxic epidermal necrolysis.^{69–72} Table 5 summarizes the dosages, adverse events, and precautions regarding the use of the most frequently used oral antibiotics for treatment of inflammatory acne.⁶⁹

The panel agreed that education and monitoring related to potential adverse events is important with oral antibiotic therapy for acne. Photosensitivity (phototoxicity) and “pill esophagitis” are

most common with oral doxycycline.^{73–75} The former can be circumvented with appropriate photoprotection, and the latter by ingestion with a large glass of water, maintaining an upright position for at least 1 hour after ingestion, and use of an enteric-coated formulation.⁷⁶ Although rare, drug hypersensitivity syndrome (DHS), Stevens-Johnson syndrome, or lupuslike syndrome (LLS) may occur with administration of minocycline. DHS presents early after initiation of minocycline therapy, usually within the first 2 to 8 weeks, commonly with flu-like symptoms (ie, fever, malaise), diffuse exanthemlike erythema, facial edema, cervical lymphadenopathy, and elevated hepatic enzymes (especially transaminases), although other organs may be involved with interstitial inflammation (eg, pneumonitis, nephritis, and thyroiditis).^{77,78}

Minocycline-associated LLS, which is commonly reversible, generally develops after chronic exposure (ie, many months to years), and often presents with malaise, distal polyarthralgias with or without polyarthritis, and, more rarely, autoimmune hepatitis.^{78–80} Most cases of minocycline-associated LLS do not have skin eruptions, although rare reports have revealed superficial vasculitis such as cutaneous polyarteritis nodosa. A positive antinuclear antibody test is often present, although not always diagnostic or predictive of minocycline LLS, along with other autoantibodies. The autoantibody profile may be highly variable among cases of minocycline-associated LLS. When present, p-ANCA positivity is believed to strongly support the diagnosis. Presence of antihistone antibody is not required to confirm the diagnosis of LLS and may not be detected in some cases. Finally, within the first few weeks of minocycline treatment, physicians should consider the rare risk of serumsicknesslike reaction.⁷⁸ Cutaneous and/or mucosal

TABLE 5 Oral Antibiotics Used for Treatment of Moderate-to-Severe Acne Vulgaris

Antibiotic	Recommended Dosage	Potential Adverse Effects	Comments
Doxycycline ^a	50–100 mg QD or BID; 150 mg QD	Gastrointestinal upset especially pill esophagitis (reduced with enteric coated formulation); photosensitivity (especially in doses of ≥ 100 mg daily); staining of forming tooth enamel (if given ≤ 8 y of age); vaginal candidiasis; BIH (rare).	Can be taken with meals, take with large glass of water and maintain upright position ≥ 1 h to decrease risk of esophagitis; optimize photoprotection especially in sunny season or with known increased outdoor exposure; avoid in children who have not developed set of permanent teeth; monitor for blurred vision, severe headaches sometimes with nausea and/or vomiting.
Erythromycin ^b	250–500 mg QD-BID	Gastrointestinal upset; drug-drug interactions such as increase in carbamazepine serum levels \rightarrow toxicity.	High prevalence of antibiotic-resistant <i>Pacnes</i> .
Tetracycline	500 mg BID	Fixed drug eruption; gastrointestinal symptoms; staining of forming tooth enamel (if given ≤ 8 y of age); vaginal candidiasis; BIH (rare).	Ingest on empty stomach preferable; absorption is decreased if taken with iron, calcium, or many other metal ions found in vitamins/supplements, dairy products (including milk, yogurt); avoid in children who have not developed set of permanent teeth; avoid in renal or hepatic disease; monitor for blurred vision, severe headaches sometimes with nausea and/or vomiting.
Minocycline (immediate release)	50–100 mg QD-BID	Cutaneous and/or mucosal hyperpigmentation of skin and mucosal sites (oral, sclera, conjunctiva); bone may be affected in some cases; DHS (systemic) often with hepatitis and/or pneumonitis (most often will occur within the first 1–2 mo); hepatitis (hypersensitivity [tends to occur more acutely early in treatment course] or autoimmune [more often to occur with more chronic use of several months to years]); LLS; Stephens-Johnson syndrome; vestibular toxicity (tends to occur within the first few days after starting therapy); staining of forming tooth enamel (if given ≤ 8 y of age); vaginal candidiasis; BIH (rare).	Can be taken with meals; warn patient about dizziness/vertigo (suggest initial doses be given when at home and not driving to assess if patient susceptible to these effects); avoid in children who have not developed set of permanent teeth; monitor for malaise, flulike symptoms, diffuse erythema with facial swelling, respiratory complaints suggestive of drug hypersensitivity especially within the first few months after starting therapy; discontinue therapy if this side effect suspected; monitor for malaise, distal arthralgias with or without arthritis especially with more prolonged use of several months to years suggestive of LLS; monitor for pigmentary changes on skin especially face, trunk, legs, and scars; monitor for blue or gray discoloration of sclera, oral mucosa, nail beds; monitor for blue discoloration of acne scars; some cases may be persistent even with discontinuation; monitor for blurred vision, severe headaches sometimes with nausea and/or vomiting.
Minocycline extended-release tablets (available since 2006)	1 mg/kg QD	Same potential reactions as above although above side effects reported predominantly with immediate-release formulations (available since 1971); lower incidence of acute vestibular side effects with weight-based dosing (1 mg/kg per day).	Same as above except lower incidence of acute vestibular side effects with weight-based dosing (1 mg/kg per day); not yet known if other potential side effects reduced with weight-based dosing of the extended-release formulation; less accumulation of minocycline over time due to pharmacokinetic properties of extended-release formulation; may possibly correlate with decreased risk of cutaneous or mucosal hyperpigmentation if dosed properly by patient weight.

TABLE 5 Continued

Antibiotic	Recommended Dosage	Potential Adverse Effects	Comments
Trimethoprim/ sulfamethoxazole	160–800 mg BID	Severe cutaneous eruptions (toxic epidermal necrolysis, Stevens-Johnson syndrome); bone marrow suppression (anemias, neutropenia, and thrombocytopenia); hypersensitivity reactions; drug eruptions (rash); fixed drug eruption.	Not generally recommended for use as first or second-line agent for acne; to be used judiciously in selected refractory cases; obtain complete blood cell count at baseline and periodically thereafter; additional caution in patients with history of anemia (megaloblastic types); may warrant hematologic consultation if use of this agent highly considered.

BID, twice daily; QD, once daily. Adapted from Tan,⁶⁹ Gollnick et al,¹⁵ and Del Rosso and Kim.⁷⁰

^a Enteric-coated and double-scored 150 mg tablet available; double-scored tablet provides 50 mg/unit (tablet can be administered whole or broken into total of 3 segments).

^b Use of lower dose for maintenance therapy based on anecdotal experience or clinical impression and not by large-scale clinical trials.

hyperpigmentation may occur in some patients treated with minocycline and appears to correlate with cumulative drug exposure over time in most cases reported with use of immediate-release minocycline formulations available since 1971.^{81–83} Weight-based dosing of minocycline (1 mg/kg per day) using the extended-release tablet formulation once daily, available since mid-2006, may potentially reduce the risk of hyperpigmentation as both the peak serum level and total drug exposure are diminished as compared with immediate-release minocycline formulations; however, continued pharmacosurveillance is warranted to confirm this preliminary observation.⁸⁴ Face, trunk, legs, oral mucosa, sclera, and nail beds should be examined periodically.

Acute vestibular adverse events (ie, vertigo, dizziness) that sometimes occur in patients treated with minocycline develop early after initiation of treatment and are reversible with discontinuation of therapy.^{85–87} Weight-based dosing of extended release-minocycline (1 mg/kg once daily) has been reported to reduce the risk for development of acute vestibular adverse events as compared with a daily dose up to threefold higher.⁶¹

A rare central nervous system-related side effect associated with use of tetracycline, doxycycline, or minocycline is benign intracranial hypertension (BIH),

also referred to as pseudotumor cerebri. A high index of suspicion is warranted if headache and visual disturbances, sometimes accompanied by nausea and/or vomiting, are noted to detect BIH early because persistence can lead to severe loss of vision, which may be permanent.⁸⁸

In the past 20 years, *P. acnes* has become less sensitive to oral and topical antibiotics because of increasing selection pressure arising from their widespread usage.^{60,66,70,89} However, strategies listed in Table 6 can minimize the potential for the development of resistance to antibiotics when used to treat acne, especially as the duration of therapy is often prolonged over months. Recent studies have revealed that the use of systemic antibiotics for acne treatment also may be associated with an increase in resistant coagulase-negative staphylococci and a possible increased risk of upper respiratory tract infection; however, further studies are needed to evaluate the true clinical implications of these potential risks.^{60,90}

Consensus Recommendations:

- Oral antibiotics are appropriate for moderate-to-severe inflammatory acne vulgaris at any age. Tetracycline derivatives (tetracycline, doxycycline, and minocycline) should not be used in children younger than 8 years of age. (SOR: B).

- Second-generation tetracyclines (doxycycline, minocycline) are sometimes preferred to tetracycline because of ease of use, fewer problems with absorption with food and minerals in vitamins and other supplements, and less-frequent dosing. (SOR: C).
- Patients should be educated and monitored for potential adverse events when utilizing oral antibiotics for acne. (SOR: B).

Topical Dapsone

Dapsone, a synthetic sulfone, has antimicrobial and antiinflammatory effects; however, its activity in the treatment

TABLE 6 Strategies to Optimize Oral Antibiotic Therapy in Acne Vulgaris

Use in moderate or severe inflammatory acne vulgaris in combination with a topical regimen that includes BP.
Avoid antibiotic monotherapy when using either an oral or topical antibiotic agent for acne vulgaris. Discontinue (or taper) within 1 to 2 mo once new inflammatory acne lesions have stopped emerging.
Incorporate a topical retinoid into the regimen early to augment overall therapeutic benefit and prepare for discontinuation of oral agent with goal of maintaining control with topical program; may also use BP-containing formulation with topical retinoid for maintenance of control of acne.
If retreatment is needed, use the same oral antibiotic that was previously effective in the past.

Adapted from Gollnick et al,¹⁵ Leyden,⁵⁰ and Del Rosso and Kim.⁷⁰

of acne as a topical agent is not believed to be related to *P. acnes* reduction.⁹¹ Recently, a 5% dapson gel was approved in the United States for acne treatment. It was evaluated in two 12-week randomized, double-blind, phase 3 trials in patients aged 12 and older with mild, moderate, or severe acne.⁹² The 3010 subjects used dapson 5% gel twice daily or vehicle gel. A combined analysis revealed a statistically significant reduction in noninflammatory and inflammatory lesions by week 12 compared with vehicle ($P < .001$). Treatment response was rapid, with statistically significant intergroup differences in lesion count at 4 weeks. Adverse events were comparable between dapson gel and vehicle gel and rarely led to discontinuation.

Available studies demonstrate that topical dapson is most effective against inflammatory lesions, with efficacy enhanced more when combined with a topical retinoid as compared with BP.^{92,93} The safety of 5% dapson gel applied twice daily has been demonstrated in patients who are glucose 6 phosphate dehydrogenase-deficient and in patients who are sulfonamide allergic.^{94–96} The most common application-site reactions consisted of erythema and dryness that were similar between groups. A temporary orange staining of the skin can occur when BP and topical dapson are used together.

Oral Isotretinoin in Severe Acne

Oral isotretinoin targets all of the pathophysiologic factors involved in acne typically producing excellent results.¹⁵ A recent consensus conference on its use recommends a starting dose of 0.5 mg/kg per day for the first 4 weeks to avoid initial flares, increasing to the full dosage of 1 mg/kg per day.⁹⁷ The panel concurs with this recommendation for iso-

tretinoin use in acne treatment of adolescents and preadolescents and agrees that it may be used in younger patients with severe, refractory, and scarring acne.

Its most common side effects include dry, chapped skin and lips, dry eyes, and myalgias. Nose bleeds secondary to dryness also are common. These effects are generally reversible upon discontinuation of the drug. Some patients may experience increases in serum triglycerides and changes in liver enzymes. Both fasting serum lipids and liver function tests should be obtained at baseline and monitored periodically thereafter. A major adverse effect of isotretinoin and a public health concern is its teratogenic potential. For this reason, the FDA mandated in 2007 the implementation of a computerized risk management program (iPledge), which registers all isotretinoin patients, physicians, pharmacies, and manufacturers and ensures monthly monitoring of pregnancy status in females of childbearing potential.

Three of the most significant and controversial groups of adverse effects attributed to isotretinoin and described in the drug's package insert are skeletal issues; potential for development of inflammatory bowel disease (IBD); and mood changes, depression, suicidal ideation, and suicide, which are addressed in greater detail because of their relevance in pediatric patients.⁹⁸

Bone Effects

The interaction between retinoids and skeletal homeostasis is complex. Animal studies have indicated that excessive intake of retinoids can have inhibitory effects on both osteoblast and osteoclast activity that may pose a theoretical risk for fractures or hyperostosis.^{99–112} Well-designed clinical studies involving human subjects have generated conflicting data on the as-

sociation between excessive intake of vitamin A with the incidence of fractures. In evaluating isotretinoin specifically, 1 small prospective cohort study associated isotretinoin with minimal-to-mild bone demineralization at specific sites (such as Ward's triangle of the femur), but revealed that these effects may be reversible.¹¹³ Additional data from small prospective cohort¹¹⁴ and case control studies^{115,116} have, however, documented no measurable changes in bone mineralization markers. These changes were not associated with increased risk of fractures in those treated with isotretinoin at the standard doses and durations used for acne.

Hyperostoses are thought to occur with somewhat greater frequency among those who received long-term systemic retinoid therapy for disorders of keratinization. Hyperostosis during retinoid use has been most strongly associated with long-term therapy or chemoprevention, appears to be dose- and duration-dependent, is often asymptomatic, and may resolve spontaneously. Overall, this phenomenon appears to be uncommon among those receiving isotretinoin for acne vulgaris. Premature epiphyseal closure in association with retinoid therapy appears to be a rare event and may occur in an asymmetric or generalized fashion. Only a single case has been reported in association with isotretinoin administered for acne.¹¹⁷ Other cases have primarily been reported as a consequence of isotretinoin therapy for disorders of keratinization¹¹⁸ or neuroblastoma.^{113,119}

IBD

There are conflicting data on the potential association between isotretinoin and IBD. In available published reports, 21 patients with preexisting IBD who subsequently receive isotretinoin have been reported to tolerate the drug;

4 experienced worsening of IBD symptoms during therapy, suggesting that the majority of patients with IBD who received isotretinoin have largely tolerated isotretinoin for acne.^{107,120–128} The occurrence of IBD after exposure to isotretinoin has been reported. These are composed of case reports or small case series ($N = 18$); a systematic review of FDA MedWatch Data¹²⁹ highlighting 85 identified cases, of which 62 were deemed highly probable or probable; and 1 large case-control study involving 8189 cases of IBD, which included 24 cases that had received isotretinoin.¹³⁰ In this case-control study, only ulcerative colitis was associated with previous isotretinoin use, and increasing cumulative dose or duration to isotretinoin was associated with an elevated risk of ulcerative colitis (1.5 odds ratio increase per 20 mg increase in dose, and 5.63 overall increased odds ratio in association with longer duration).

At the same time, a case-control study evaluating a Manitoba IBD Epidemiology Database revealed no evidence for an association between IBD and isotretinoin use¹³¹; in addition, a systematic literature-based search of case reports, case series, and clinical trials likewise revealed no evidence for an association.¹³²

An association between IBD (in particular, ulcerative colitis) and isotretinoin, therefore, may potentially exist, although if it does, it appears to affect a small subset of patients. The phenomenon appears to be rare, seems to be idiosyncratic, and, at present, there are no identifiable clinical characteristics that can currently a priori predict this type of response. The association is also fraught with confounding factors, since the highest age of IBD onset overlaps the age when patients develop severe acne and when isotretinoin is typically used. In addition, it was noted in a study by Margolis et al¹¹⁴ that the ma-

majority of patients prescribed isotretinoin treatment have been on extended antibiotic therapy and that previous antibiotic use may be an important confounding variable in the relationship between IBD and isotretinoin. Furthermore, a potential link between IBD and inflammatory acne itself cannot be excluded.

Mood Disorders

The evidence regarding an association between isotretinoin use and mood disorders is primarily anecdotal, with the original case series of 24 patients reported by Hazen comprising the reported experience on this linkage. One open-label study compared acne patients recalcitrant to antibiotics to those receiving isotretinoin, and identified changes in brain metabolism in the orbitofrontal cortex, which are thought to partially mediate depressive symptoms.¹³³ However, the numbers of patients studied were small ($N = 28$), and those receiving isotretinoin had more severe acne, which could correlate with more severe depressive symptoms independent of the isotretinoin. Indeed, in a large cross-sectional questionnaire-based study of 3775 adolescents between 18 and 19 years of age who suffered from acne, those with more severe acne were more than twice as likely to have mental health issues and 1.8 times more likely to have suicidal ideation. In fact, ~1 in 4 adolescents with significant acne were noted to have mental health issues. A systematic review by Marqueling and Zane¹³⁴ identified 6 prospective studies and 3 retrospective studies that involved at least 20 patients, studied depressive symptoms in human subjects as primary data, and used epidemiologic techniques. In this analysis, there was no apparent increase in depression diagnoses or symptoms when baseline was compared with after treatment with isotretinoin. Four subsequent additional

studies (2 prospective, 1 case-control, and 1 cohort study) evaluated isotretinoin use and depressive symptoms.^{135,136} Although none of these additional studies identified a positive association between isotretinoin use and depression, 2 of them indicated that as acne improved, quality of life improved¹³⁷ and depressive symptoms and suicidal ideation actually decreased.¹³⁸

In summary, case reports and case series have identified patients who developed depressive symptoms while receiving or after isotretinoin therapy, and 1 study utilizing positron emission tomography has documented changes in cerebral metabolism in patients receiving isotretinoin therapy. Epidemiologic studies, however, do not currently support a causative association between isotretinoin and depression, and acne severity itself is a predictor of mental health issues and suicidal ideation. Ongoing vigilance and surveillance of patients for mood changes while on isotretinoin therapy seem reasonable, but the data appear reassuring.

Consensus Recommendation:

- Isotretinoin is recommended for severe, scarring, and/or refractory acne in adolescents and may be used in younger patients. (SOR adolescents: A; SOR preadolescents and younger: C). Extensive counseling, particularly regarding the avoidance of pregnancy as well as careful monitoring of potential side effects and toxicities, is recommended.

PRESCRIPTION TREATMENT OPTIONS: TOPICAL FIXED-DOSE COMBINATION THERAPIES

Numerous topical fixed-dose combination products, including BP/clindamycin, BP/adapalene, BP/erythromycin, and tretinoin/clindamycin, are currently FDA approved for pediatric patients 12 years

and older as outlined in Table 7. All of the products are pregnancy category C.

In the phase 3 pivotal trials for BP 2.5%/clindamycin 1.2% gel (Acanya, Coria Laboratories), 62% of enrolled patients were between the ages of 12 and 17. In a subanalysis of 12- to 17-year-old patients, lesion count and success rate were similar to those obtained in the study as a whole.¹³⁹ In the pivotal trial for tretinoin 0.025%/clindamycin 1.2% (Ziana Gel, Medicis Pharmaceutical Corporation, Scottsdale, AZ), 51% of enrolled patients were 12 to 17 years of age and, in an unpublished subanalysis for the pediatric age group, was essentially no different from the study group as a whole. In the BP 2.5%/adapalene 0.1% gel (Epiduo Gel, Galderma Laboratories, LP, Fort Worth, TX) pivotal trial, the mean age was 16.2 years and a subanalysis of results in the 12- to 17-year-old group was similar to the study group as a whole.¹⁴⁰

Although sometimes more costly than single agents prescribed separately, fixed combinations applied once daily are very convenient and thus may improve adherence.^{52,141}

Consensus Recommendation:

- Fixed-dose combination topical therapies may be useful in regimens of care for all types and severities of acne. (SOR adolescents: A; preadolescents and younger: B).

HORMONAL THERAPY

Hormonal therapy in acne is directed at suppressing ovarian androgen pro-

duction and blocking the effects of androgens on the sebaceous gland that leads to reduction of sebum production and improvement in acne. Combination oral contraceptives (OCs; estrogen plus progestin) block the ovarian production of androgen, and antiandrogens, such as spironolactone, block the effects of androgens on the sebaceous gland. In patients diagnosed with congenital adrenal hyperplasia, low-dose glucocorticoids are used to suppress the adrenal production of androgens.

Although others have antiacne efficacy, only 3 combination OCs are currently FDA approved for the treatment of acne (Ortho Tri Cyclen [norgestimate/ethinyl estradiol] Tablets indicated for use in moderate acne in females ≥ 15 years of age; Estrostep [norethindrone acetate and ethinyl estradiol] Tablets indicated for use in moderate acne for females ≥ 15 years of age; and Yaz [drospirenone/ethinyl estradiol] Tablets for moderate acne in females ≥ 14 years of age). The reduction in the estrogen dosage of OCs has lowered the risk of thromboembolism associated with some of the earlier OC formulations, although this relationship is still under review by the FDA. Although absolute thromboembolic risk is low in adolescence, it is recommended that a family history of thrombotic events be obtained and young patients are asked if they smoke before OCs are prescribed. The most common adverse events related to their use include nausea/vomiting, breast tenderness, headache, weight gain, and breakthrough bleeding.

The most important issues regarding the use of combination OCs in the pediatric population involve whether low doses of estrogen provide sufficient estrogen for bone accrual and at what age it is safe to initiate use. Approximately 50% of bone mass is accrued between the ages of 12 and 18 years.¹⁴² Some experts believe that it is important to allow the development of as much bone mineral density (BMD) as possible before initiating treatment with exogenous estrogen.

In a 24-month study of postmenarchal girls with a mean age of 16.0 ± 1.4 years who were treated with an OC containing 100 mcg levonorgestrel and 20 mcg ethinyl estradiol, there was a mean increase in lumbar spine BMD at the femoral neck in 4.2% of girls who received OC versus 6.3% in untreated controls.¹⁴³ The use of OCs did not result in osteopenia in any subject. Nevertheless, the authors concluded that it is unclear whether the currently available low-dose OC containing 20 mcg ethinyl estradiol is adequate for bone mass accrual in this age group. A long-term study of combined OCs with calcium supplementation revealed no effect on BMD after 10 years.¹⁴⁴ Referral to an adolescent medicine specialist or gynecologist for management of OC treatment remains dependent on the physician's comfort level.

Spironolactone is a synthetic steroidal androgen receptor blocker that is often used in female acne patients.^{145,146} In select groups of acne patients, spironolactone has revealed efficacy,^{147–149} although its overall role in acne therapy and appropriate age to initiate treatment has not yet been fully determined.¹⁵⁰ There are minimal data on its use in pediatric acne.

Consensus Recommendations:

- Hormonal therapy with combined OC may be useful as second-line therapy in regimens of care in pubertal females with moderate-to-

TABLE 7 Topical Fixed-Dose Combination Prescription Acne Therapies

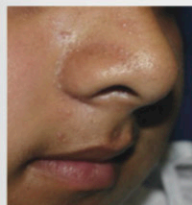Product	Active Ingredients and Concentration
Acanya Gel	Clindamycin phosphate, 1.2%; BP, 2.5% (aqueous-based)
BenzaClin Gel (generic available)	Clindamycin phosphate, 1%; BP, 5% (aqueous-based)
Benzamycin Gel (generic available)	Erythromycin, 3%; BP, 5% (alcohol-based)
Duac Gel ^a	Clindamycin phosphate, 1%; BP, 5% (aqueous-based)
Epiduo Gel	Adapalene, 0.1%; BP, 2.5%
Veltin Gel	Clindamycin phosphate, 1.2%; Tretinoin, 0.025%
Ziana Gel	Clindamycin phosphate, 1.2%; Tretinoin, 0.025%

^a Duac Gel is indicated for inflammatory acne vulgaris.

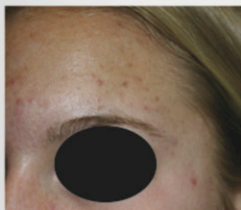
Pediatric Treatment Recommendations for Mild Acne

Mild Acne=Comedonal or Inflammatory/Mixed Lesions

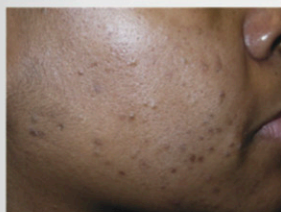Mild Comedonal Acne
(central face common in preteens and early teens)



More Extensive Comedonal Acne
(forehead involvement common in preteens and early teens; often with no or a few scattered superficial inflammatory lesions)



Mild Inflammatory Acne
(scattered superficial inflammatory papules/pustules + some comedones)



Pediatric Treatment Recommendations for Mild Acne

Initial Treatment

Benzoyl Peroxide (BP)
or
Topical Retinoid

or

Topical Combination Therapy*
BP + Antibiotic
or
Retinoid + BP
or
Retinoid + Antibiotic + BP

Inadequate Response**

Add BP or Retinoid,
If Not Already Prescribed
or
Change Topical Retinoid
Concentration, Type
and/or Formulation
or
Change Topical
Combination Therapy

Topical dapsone may be considered as single therapy or in place of topical antibiotic

*Topical fixed-combination prescriptions available

**Assess adherence

Additional Treatment Considerations

- Previous treatment/history
- Costs
- Vehicle selection
- Ease of use
- Managing expectations/side effects
- Psychosocial impact
- Active scarring
- Regimen complexity



© American Acne & Rosacea Society, 2011.

Photos courtesy of Lawrence F. Eichenfield, MD, James Q. Del Rosso, DO and Diane Thiboutot, MD

FIGURE 1

Pediatric treatment recommendations for mild acne.

severe acne. Tobacco use and family history of thrombotic events should be assessed. (SOR adolescents: A).

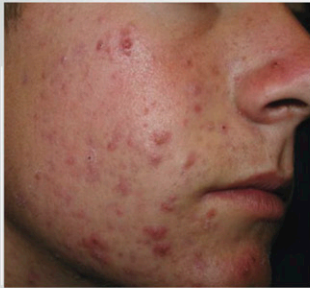- Because of concerns about growth and bone density, many experts recommend withholding OC for

acne unassociated with endocrinologic pathology until 1 year after onset of menstruation. (SOR: C).

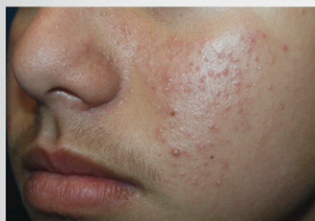Pediatric Treatment Recommendations for Moderate Acne

Moderate Acne=Comedonal or Inflammatory/Mixed Lesions

Note Marked Number of Inflammatory Lesions



Some Comedones Present



Pediatric Treatment Recommendations for Moderate Acne

Initial Treatment

Topical Combination Therapy*
Retinoid + Benzoyl Peroxide (BP)
or
Retinoid + (BP + Antibiotic)
or
(Retinoid + Antibiotic) + BP

or

Oral Antibiotic
+
Topical Retinoid + BP
or
Topical Retinoid + Antibiotic + BP

Topical dapsone may be considered in place of topical antibiotic

*Topical fixed-combination prescriptions available

**Assess adherence

Inadequate Response**

Change Topical Retinoid Concentration, Type and/or Formulation and/or Change Topical Combination Therapy

and/or

Add or Change Oral Antibiotic
FEMALES: Consider Hormonal Therapy†

or

Consider Oral Isotretinoin†

†Consider dermatology referral

Additional Treatment Considerations

- Previous treatment/history
- Costs
- Vehicle selection
- Ease of use
- Managing expectations/side effects
- Psychosocial impact
- Active scarring
- Regimen complexity



© American Acne & Rosacea Society, 2011.

Photos courtesy of Lawrence Eichenfield, MD and James Q. Del Rosso, DO

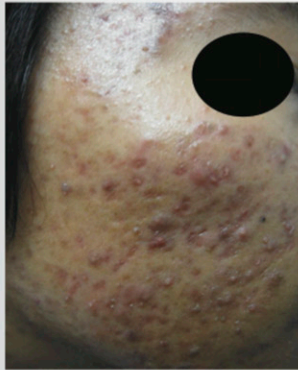FIGURE 2

Pediatric treatment recommendations for moderate acne.

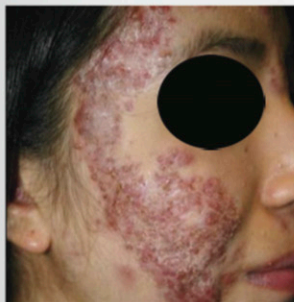Pediatric Treatment Recommendations for Severe Acne

Severe Acne=Inflammatory/ Mixed and/or Nodular Lesions

Extensive Inflammatory
Lesion Involvement



Note Diffuse Scarring



Pediatric Treatment Recommendations for Moderate Acne

Initial Treatment[†]

Combination Therapy*
Oral Antibiotic
+
Topical Retinoid
+
Benzoyl Peroxide (BP)
+/-
Topical Antibiotic

Inadequate Response**^{††}

Consider Changing
Oral Antibiotic
AND
Consider Oral Isotretinoin

FEMALES: Consider
Hormonal Therapy[†]

[†]Consider dermatology referral

Topical dapsone may be considered in
place of topical antibiotic

*Topical fixed-combination prescriptions
available

**Assess adherence; consider change of
topical retinoid

Additional Treatment Considerations

- Previous treatment/
history
- Costs
- Vehicle selection
- Ease of use
- Managing expectations/
side effects
- Psychosocial impact
- Active scarring
- Regimen complexity



© American Acne & Rosacea Society, 2011.

Photos courtesy of Anthony Mancini, MD and James Q. Del Rosso, DO

FIGURE 3

Pediatric treatment recommendations for severe acne.

EVIDENCE-BASED TREATMENT RECOMMENDATIONS FOR PEDIATRIC ACNE

When selecting acne treatment, it is important to assess severity as a function of number, type, and severity of lesions as well as psychological impact on the patient including the likelihood of scarring and/or dyspigmentation. The panel recommends pediatric treatment recommendations based on severity of mild, moderate, and severe acne as discussed later.

Mild Acne

Mild acne may present as predominantly comedonal or as mixed comedonal and inflammatory disease (Fig 1). Evidence-based treatment recommendations by the panel for mild acne are highlighted in Fig 1.

Initial Treatment

Topical therapy alone or in combination is recommended as initial treatment of mild acne. BP as a single agent, topical retinoids, or combinations of topical retinoids, antibiotics, and BP as individual agents or fixed-dose combinations may be used.

In patients of color in whom the propensity for scarring and PIH is greater, initial treatment also might include an oral or topical antibiotic.¹⁵¹ Depending on patient and parent preference, treatment could be initiated with monotherapy, including OTC products. OTC products are generally effective for very mild acne, but, with the exception of BP, data on the efficacy of their ingredients are lacking. Patients should be counseled that it takes ~4 to 8 weeks to demonstrate visible results from any acne treatment.

Consensus Recommendation:

- Initial therapy for mild acne may include OTC products such as BP as a single agent, topical retinoids, or combinations of topical retinoids,

antibiotics, and BP as individual agents or fixed-dose combinations. (SOR adolescents: A; SOR preadolescents and younger: B).

Inadequate Response

If response to first-line treatment is inadequate, it is important to check adherence by asking the patient and/or the parent and, if necessary, to reiterate usage instructions. If adherence appears to be adequate, a topical retinoid or BP may be added to monotherapy with either agent. It has been shown that early initiation of clindamycin/BP + adapalene produced earlier and greater reductions in lesion counts when compared with adapalene monotherapy or BP/clindamycin for 4 weeks, with adapalene added at week 4.¹⁵² The concentration, type, and/or formulation of the topical retinoid may be changed, or the topical combination therapy can be changed. Another option to consider is topical dapson; however, the panel notes large-scale comparative studies of dapson versus other topicals are lacking, particularly in pediatric patients.

Moderate Acne

Although it is recommended to start with the least aggressive, effective regimen, moderate (Fig 2) and severe acne typically requires a more aggressive regimen, possibly with the addition of oral antibiotics (Fig 3).

Initial Therapy

Initial therapy for moderate acne may include topical combination therapies as described earlier or with combinations that include topical dapson.

Adding an Oral Antibiotic

Overall, oral antibiotic therapy is a safe and effective approach to the treatment of moderate-to-severe inflammatory or mixed comedonal and inflammatory acne vulgaris used for more than 5

decades. Physicians may elect to initiate treatment of moderate acne with a topical regimen and add an oral antibiotic if the therapeutic response is not adequate. Alternatively, an oral antibiotic may be started concomitantly with a topical regimen for moderate-to-severe acne. Optimally, the topical regimen would include a retinoid and a BP-containing formulation, either separately or as a combination product. In addition, use of an oral antibiotic may be especially prudent if there is evidence of acne scarring, even if the current severity of inflammatory acne is more modest.¹⁵¹ Importantly, some oral antibiotics, especially tetracycline derivatives, in addition to antibiotic activity against *P. acnes*, exhibit certain antiinflammatory and immunomodulatory properties that may be operative in counteracting mechanisms or pathways involved in acne lesion development.^{60,153–155}

Typically, 4 to 8 weeks of compliant oral antibiotic use are needed before the clinical effects of an oral antibiotic are visible, whereas maximal response may require 3 to 6 months of administration.^{15,70} Once the formation of new inflammatory lesions, defined as lesions that are raised by palpation, are markedly diminished in number, consideration may be given to stopping oral antibiotics with continuation of topical therapy to maintain control of acne.

Consensus Recommendation:

- Moderate acne may be initially treated with topical combinations including a retinoid and BP and/or antibiotics, or with oral antibiotics in addition to a topical retinoid and BP and/or topical antibiotics. (SOR adolescents: A; SOR preadolescents and younger: C).

Inadequate Response

If response to the above topical combination regimens with or without oral

antibiotics is inadequate, adherence should again be evaluated. Referral to a dermatologist or pediatric dermatologist may be considered if response has been poor and there is continued patient or parental frustration. The type, strength, or formulation of the retinoid, BP, or BP-antibiotic component of the topical regimen may be changed to increase potency or adjusted to reduce skin irritation if present or to simplify the steps of application.

Severe Acne

Patients with severe acne are at significant risk for scarring (Fig 3). The panel recommends that the prompt initiation of appropriate treatment is essential to control the condition and prevent permanent skin changes.

Initial Treatment

Although the therapeutic agents are the same as those used in moderate acne, it is recommended that an oral antibiotic should be part of the initial treatment and should be used with either a topical retinoid + BP with or without topical antibiotics.

Consensus Recommendation:

- Severe acne should be treated with oral antibiotics and topical retinoids with BP, with or without topical antibiotics, with consideration of hormonal therapy in pubertal females, oral isotretinoin, and dermatology referral. (SOR: C).

Inadequate Response

In cases of inadequate response, compliance with the prescribed regimen should be reassessed first. If adherence has been adequate, the oral antibiotic agent or class may be changed. For instance, if doxycycline has provided only a partial response, minocycline might prove a more effective alternative. For female patients, combination OC therapy should be

considered. Both male and female patients unresponsive to these topical and oral therapies will benefit from consideration of oral isotretinoin.

RECOMMENDATIONS FOR ACNE MANAGEMENT IN THE PREADOLESCENT

The algorithm for acne management of the preadolescent is essentially the same as for the adolescent, though these recommendations are based more strongly on expert opinion. Antibiotics in the tetracycline class should not be used for the treatment of acne in patients under 8 years of age.

OTHER CONSIDERATIONS FOR PEDIATRIC ACNE TREATMENT SELECTION

A number of additional considerations are pertinent to acne management and selection of therapies in pediatric patients. Chief among them are an understanding of previous treatment history, cost of medications, ease of use and regimen complexity and its impact on adherence, vehicle selection, active scarring, and psychosocial impact of the acne on the individual. In addition, the influence of diet on acne, an area of evolving understanding, may be considered.

Previous Treatment and History

At the initial assessment, it is crucial to inquire about previous treatment history, if any. An important question is whether the patient responded to a specific first-line regimen. If so, unless there are circumstances dictating otherwise, treatment should be reinitiated with the previous regimen or some of its elements. However, if response to previous therapies has been poor, up-titration, add-on therapies, or switching to an alternative should be considered.¹⁵⁶

Financial Costs

In addition to the aforementioned considerations, patient resources and the financial costs of treatment must be considered when selecting a treatment regimen from the panel recommendations. A recent retrospective cross-sectional study by Patel et al¹⁵⁷ of 3 784 816 patients with acne and similar conditions indicated there was a significant overall decrease in reported total annual prescription spending widely attributed to the reduction of oral antibiotic use and increase in the use of OCs and oral retinoids. Further, the use of topical retinoids was preferred in combination with other treatments rather than as monotherapy. Managed-care organizations are increasingly requiring cost-sharing, and it may be necessary to adapt prescribing preferences to patient resources.

Ease of Use, Regimen Complexity, and Adherence

Adherence is the contemporary terminology for persistence in use of a recommended medical treatment and denotes a partnership between the patient and the physician. Adherence with an acne treatment regimen is a sine qua non of successful management. In fact, lack of adherence is a major reason for acne treatment failures.¹⁵⁸ Prevention and proactive education is easier than dealing with nonadherence after treatment response has been inadequate.⁵ Therefore, adherence to the prescribed regimen should be assessed at each visit, particularly if the response is less than expected. Adherence is a function of cost of medications/therapies, ease of use/regimen simplicity, patient preferences, tolerability, rapidity of results, and patient or parent understanding.

Vehicle Selection

In 1 small study, it was found that nonadherence with acne treatment was

52% after 3 months.¹⁵⁹ Adherence may be improved through patient and parent education, selection of a simple regimen, more frequent doctor visits, and choice of vehicles that improve medication tolerability. One study revealed a direct correlation between adherence and dosing frequency, with 83.6% of patients complying with once-daily dosing versus 74.9% with twice-daily dosing. Fixed combinations of topical medications may be helpful in this regard.

Empowering patients with control over their care is important for adherence.¹⁶⁰ It is essential to elicit information at each doctor visit about patient preferences and lifestyle. For example, a water-based gel may be the optimal choice for the patient who wears makeup.¹⁶¹ Teenagers, especially males, may not like the feel of moisturizers but may accept a gel, pad or foam, or in-shower wash.¹⁶⁰ Other vehicle considerations center around tolerability, which is influenced by the medication's impact on the skin barrier. Many topical medications are being formulated in vehicles, including aqueous gels, which are therapeutic and may help rehydrate and repair the skin barrier.¹⁶¹ It may be useful to initiate treatment with extremely mild topical agents until the skin has adjusted to medication effects and patients have adapted to side effects.¹⁶⁰

Active Scarring

The likelihood of scarring is an important consideration in treatment selection. Patients with moderate and severe acne are at increased risk of scarring, as are those with more deeply pigmented skin.¹⁵¹ Hence, aggressive treatment is warranted to prevent permanent sequelae in these patient populations.

Psychosocial Impact

The psychosocial impact of acne is influenced by numerous factors including

age, disease severity, social and familial networks, and individual personalities. Adolescents with substantial acne are reported to have high rates of mental health problems, affective isolation, social impairment, depression, and suicidal ideation.¹⁶² In the cases where the impact on the psychosocial health of the patient is particularly burdensome, effective treatment of acne may result in improvements in self-esteem, affect, shame, embarrassment, body image, social assertiveness, and self-confidence.¹⁵⁰

Managing Expectations

Adolescents are notoriously impatient. Physicians, who see the patient at intervals rather than daily, may note improvement between visits that may not be readily apparent to the adolescent who examines his or her face in the mirror several times per day.¹⁵⁶ A basic understanding of acne pathophysiology and how prescribed agents work to control acne may augment adherence.¹⁶³ For example, both patients and parents should be given reasonable expectations of the time to visible improvement. It is important to explain that acne may worsen or irritation may be more significant initially, with gradual improvement. An understanding of the "invisible microcomedo" helps patients understand why topical medications should be applied to the entire face.

Many adolescents believe that acne is related to facial hygiene, and so they may try treating themselves with harsh astringents, abrasives, or vigorous scrubbing. It is important for them to understand that such treatment may actually worsen their acne and increase the likelihood of inflammation and scarring. Many clinicians prefer to recommend an appropriate gentle, daily skin-care regimen, including a non-comedogenic moisturizer and sunscreen for the patient to use with the prescribed treatment(s).

Diet and Acne

Consideration of a role for diet in contributing to acne arose in the 1930s, and chocolate, sugar, and iodine were among the dietary factors implicated. As a result of a series of studies in the late 1960s that failed to identify a dietary connection, the concept fell out of fashion.¹⁶⁴ However, the debate has been rekindled in response to a variety of data emerging over the last decade.

A retrospective recall-based study in adult nurses¹⁶⁵ and a prospective self-assessment study in teenage girls¹⁶⁶ both suggested an association between acne and intake of milk and other dairy products. A subsequent prospective study in teenage boys suggested an association with skim milk,¹⁶⁷ although the previous 2 studies did not identify a difference based on milk fat content.

The effects on acne of glycemic load in the diet also have been subjected to examination. An anthropologic study¹⁶⁸ comparing acne rates in a hunter-gatherer population in Papua New Guinea versus those in the developed world suggested that dietary glycemic load may contribute to the observed differences in acne incidence. A number of prospective trials^{169,170} subsequently have been performed, notably including a randomized prospective controlled trial of a low glycemic diet versus a high glycemic diet in teenage boys.¹⁷¹ By the end of the 12-week study, the low glycemic diet was shown to provide superior reduction in the number of total acne lesions (-23.5 ± 3.9 vs -12.0 ± 3.5 , $P = .03$), as well as reductions in inflammatory lesion count and other parameters including weight and BMI.

Other dietary constituents that are the subject of renewed interest include zinc and antioxidants; the role of chocolate is being reinvestigated in a blinded placebo-controlled clinical trial (clinicaltrials.gov). Based on the currently

available data, it is difficult to point with certainty to any dietary manipulation that should be recommended to pediatric patients suffering from acne; however, consideration may be given in individual cases to institution of a low glycemic diet. Patient and parent education to dispel acne myths is an important treatment consideration.

CONCLUSIONS

As the pathogenesis of acne vulgaris appears to be similar at all ages, the

same principles and therapeutic agents apply to all age groups diagnosed with acne. However, age group differences may require special considerations in the use of these agents, particularly with regard to ease of use and patient adherence, cost factors, differences in psychosocial impacts among age groups, the likelihood of scarring, and the use of advanced vehicles to minimize adverse effects on young skin.

Although there are many acne treatment approaches to consider, these

evidence-based treatment recommendations from the pediatric perspective may provide useful guidance in the management of acne vulgaris during childhood and adolescence. In most cases, acne can be successfully treated by nondermatologists. In other instances, clinicians may decide that, in addition to using these recommendations, consultation with another specialist such as a pediatric dermatologist or pediatric endocrinologist is appropriate.

REFERENCES

1. Dreno B, Poli F. Epidemiology of acne. *Dermatology*. 2003;206(1):7–10
2. Friedlander SF, Eichenfield LF, Fowler JF Jr, Fried RG, Levy ML, Webster GF. Acne epidemiology and pathophysiology. *Semin Cutan Med Surg*. 2010;29(2 suppl 1):2–4
3. Lucky AW, Biro FM, Huster GA, Leach AD, Morrison JA, Ratterman J. Acne vulgaris in premenarchal girls. An early sign of puberty associated with rising levels of dehydroepiandrosterone. *Arch Dermatol*. 1994;130(3):308–314
4. Ebell MH, Siwek J, Weiss BD, et al. Strength of recommendation taxonomy (SORT): a patient-centered approach to grading evidence in the medical literature. *Am Fam Physician*. 2004;69(3):548–556
5. Eichenfield LF, Fowler JF Jr, Fried RG, Friedlander SF, Levy ML, Webster GF. Perspectives on therapeutic options for acne: an update. *Semin Cutan Med Surg*. 2010;29(2 suppl 1):13–16
6. Tom WL, Friedlander SF. Acne through the ages: case-based observations through childhood and adolescence. *Clin Pediatr (Phila)*. 2008;47(7):639–651
7. Krakowski AC, Eichenfield LF. Pediatric acne: clinical presentations, evaluation, and management. *J Drugs Dermatol*. 2007;6(6):589–593
8. Cantatore-Francis JL, Glick SA. Childhood acne: evaluation and management. *Dermatol Ther*. 2006;19(4):202–209
9. Jansen T, Burgdorf WH, Plewig G. Pathogenesis and treatment of acne in childhood. *Pediatr Dermatol*. 1997;14(1):17–21
10. Piggott CDS, Eichenfield LF, Lucky AW. Acne in children. In: Shalita AR, Del Rosso JQ, Webster GF, eds. *Acne Vulgaris*. New York, NY: Informa Healthcare; 2011:182–197
11. Marcoux D, McCuaig CC, Powell J. Prepubertal acne: clinical presentation, evaluation, and treatment. *J Cutan Med Surg*. 1998;2(suppl 3):2–6
12. Cunliffe WJ, Baron SE, Coulson IH. A clinical and therapeutic study of 29 patients with infantile acne. *Br J Dermatol*. 2001;145(3):463–466
13. Herane MI, Ando I. Acne in infancy and acne genetics. *Dermatology*. 2003;206(1):24–28
14. Lucky AW, Koltun W, Thiboutot D, et al. A combined oral contraceptive containing 3-mg drospirenone/ 20-microg ethinyl estradiol in the treatment of acne vulgaris: a randomized, double-blind, placebo-controlled study evaluating lesion counts and participant self-assessment. *Cutis*. 2008;82(2):143–150
15. Gollnick H, Cunliffe W, Berson D, et al; Global Alliance to Improve Outcomes in Acne. Management of acne: a report from a Global Alliance to Improve Outcomes in Acne. *J Am Acad Dermatol*. 2003;49(suppl 1):S1–S37
16. Thielitz A, Sidou F, Gollnick H. Control of microcomedone formation throughout a maintenance treatment with adapalene gel, 0.1%. *J Eur Acad Dermatol Venereol*. 2007;21(6):747–753
17. Demircay Z, Seckin D, Senol A, Demir F. Patient's perspective: an important issue not to be overlooked in assessing acne severity. *Eur J Dermatol*. 2008;18(2):181–184
18. Aktan S, Ozmen E, Sanli B. Anxiety, depression, and nature of acne vulgaris in adolescents. *Int J Dermatol*. 2000;39(5):354–357
19. Kellett SC, Gawkrödger DJ. The psychological and emotional impact of acne and the effect of treatment with isotretinoin. *Br J Dermatol*. 1999;140(2):273–282
20. Mallon E, Newton JN, Klassen A, Stewart-Brown SL, Ryan TJ, Finlay AY. The quality of life in acne: a comparison with general medical conditions using generic questionnaires. *Br J Dermatol*. 1999;140(4):672–676
21. Tan JK, Vasey K, Fung KY. Beliefs and perceptions of patients with acne. *J Am Acad Dermatol*. 2001;44(3):439–445
22. Shalita AR. Treatment of mild and moderate acne vulgaris with salicylic acid in an alcohol-detergent vehicle. *Cutis*. 1981;28(5):556–558, 561
23. Shalita AR. Comparison of a salicylic acid cleanser and a benzoyl peroxide wash in the treatment of acne vulgaris. *Clin Ther*. 1989;11(2):264–267
24. Gupta AK, Nicol K. The use of sulfur in dermatology. *J Drugs Dermatol*. 2004;3(4):427–431
25. Del Rosso JQ. The use of sodium sulfacetamide 10%-sulfur 5% emollient foam in the treatment of acne vulgaris. *J Clin Aesthet Dermatol*. 2009;2(8):26–29
26. Breneman DL, Ariano MC. Successful treatment of acne vulgaris in women with a new topical sodium sulfacetamide/sulfur lotion. *Int J Dermatol*. 1993;32(5):365–367
27. Tarımcı N, Sener S, Kilingç T. Topical sodium sulfacetamide/sulfur lotion. *J Clin Pharm Ther*. 1997;22(4):301
28. Green J, Sinclair RD. Perceptions of acne vulgaris in final year medical student written examination answers. *Australas J Dermatol*. 2001;42(2):98–101
29. Goodman G. Cleansing and moisturizing in acne patients. *Am J Clin Dermatol*. 2009;10(suppl 1):1–6
30. Draelos ZD. The effect of a daily facial cleanser for normal to oily skin on the skin barrier of subjects with acne. *Cutis*. 2006;78(suppl 1):34–40

31. Toombs EL. Cosmetics in the treatment of acne vulgaris. *Dermatol Clin*. 2005;23(3): 575–581, viii
32. Hayashi N, Imori M, Yanagisawa M, Seto Y, Nagata O, Kawashima M. Make-up improves the quality of life of acne patients without aggravating acne eruptions during treatments. *Eur J Dermatol*. 2005;15(4):284–287
33. Matsuoka Y, Yoneda K, Sadahira C, Katsuura J, Moriue T, Kubota Y. Effects of skin care and makeup under instructions from dermatologists on the quality of life of female patients with acne vulgaris. *J Dermatol*. 2006;33(11):745–752
34. Office of the Federal Register, National Archives and Records Administration. Federal Register. March 4, 2010;75(42):9767–9777
35. Kligman AM. Acne vulgaris: tricks and treatments. Part II: the benzoyl peroxide saga. *Cutis*. 1995;56(5):260–261
36. Kligman AM, Leyden JJ, Stewart R. New uses for benzoyl peroxide: a broad-spectrum antimicrobial agent. *Int J Dermatol*. 1977;16(5):413–417
37. Hegemann L, Toso SM, Kitay K, Webster GF. Anti-inflammatory actions of benzoyl peroxide: effects on the generation of reactive oxygen species by leucocytes and the activity of protein kinase C and calmodulin. *Br J Dermatol*. 1994;130(5):569–575
38. Krakowski AC, Stendardo S, Eichenfield LF. Practical considerations in acne treatment and the clinical impact of topical combination therapy. *Pediatr Dermatol*. 2008;25(suppl 1):1–14
39. Shalita AR, Rafal ES, Anderson DN, Yavel R, Landow S, Lee WL. Compared efficacy and safety of tretinoin 0.1% microsphere gel alone and in combination with benzoyl peroxide 6% cleanser for the treatment of acne vulgaris. *Cutis*. 2003;72(2):167–172
40. Pariser DM, Westmoreland P, Morris A, Gold MH, Liu Y, Graeber M. Long-term safety and efficacy of a unique fixed-dose combination gel of adapalene 0.1% and benzoyl peroxide 2.5% for the treatment of acne vulgaris. *J Drugs Dermatol*. 2007;6(9):899–905
41. Leyden JJ, Wortzman M, Baldwin EK. Antibiotic-resistant *Propionibacterium acnes* suppressed by a benzoyl peroxide cleanser 6%. *Cutis*. 2008;82(6):417–421
42. Ozolins M, Eady EA, Avery AJ, et al. Comparison of five antimicrobial regimens for treatment of mild to moderate inflammatory facial acne vulgaris in the community: randomised controlled trial. *Lancet*. 2004;364(9452):2188–2195
43. Thiboutot D, Gollnick H, Bettoli V, et al; Global Alliance to Improve Outcomes in Acne. New insights into the management of acne: an update from the Global Alliance to Improve Outcomes in Acne group. *J Am Acad Dermatol*. 2009;60(suppl 5):S1–S50
44. Mohd Nor NH, Aziz Z. A systematic review of benzoyl peroxide for acne vulgaris [published online ahead of print July 25, 2012]. *J Dermatolog Treat*.
45. Leyden JJ. Efficacy of benzoyl peroxide (5.3%) emollient foam and benzoyl peroxide (8%) wash in reducing *Propionibacterium acnes* on the back. *J Drugs Dermatol*. 2010;9(6):622–625
46. Atralin (tretinoin) Gel, 0.05% [package insert]. Fort Worth, TX: Coria Laboratories; 2007
47. Kose O, Koç E, Arca E. Adapalene gel 0.1% in the treatment of infantile acne: an open clinical study. *Pediatr Dermatol*. 2008;25(3):383–386
48. Eichenfield LF, Matiz C, Funk A, Dill SW. Study of the efficacy and tolerability of 0.04% tretinoin microsphere gel for preadolescent acne. *Pediatrics*. 2010;125(6). Available at: www.pediatrics.org/cgi/content/full/125/6/e1316
49. Eichenfield LF, Hebert AA, Schachner L, Paller AS, Rossi AB, Lucky AW. Tretinoin microsphere gel 0.04% pump for treating acne vulgaris in preadolescents: a randomized, controlled study. *Pediatr Dermatol*. 2012;29(5):598–604
50. Leyden JJ. A review of the use of combination therapies for the treatment of acne vulgaris. *J Am Acad Dermatol*. 2003;49(suppl 3):S200–S210
51. Hensby C, Cavey D, Bouclier M, et al. The in vivo and in vitro anti-inflammatory activity of CD271: a new retinoid-like modulator of cell differentiation. *Agents Actions*. 1990;29(1-2):56–58
52. Imahiyero-Ip JI, Dinulos JG. Changing the topography of acne with topical medications. *Curr Opin Pediatr*. 2011;23(1):121–125
53. Zaenglein AL, Thiboutot DM. Expert committee recommendations for acne management. *Pediatrics*. 2006;118(3):1188–1199
54. Jacyk WK, Mpofu P. Adapalene gel 0.1% for topical treatment of acne vulgaris in African patients. *Cutis*. 2001;68(suppl 4):48–54
55. Martin B, Meunier C, Montels D, Watts O. Chemical stability of adapalene and tretinoin when combined with benzoyl peroxide in presence and in absence of visible light and ultraviolet radiation. *Br J Dermatol*. 1998;139(suppl 52):8–11
56. Bershad S, Kranjac Singer G, Parente JE, et al. Successful treatment of acne vulgaris using a new method: results of a randomized vehicle-controlled trial of short-contact therapy with 0.1% tazarotene gel. *Arch Dermatol*. 2002;138(4):481–489
57. Jick SS, Terris BZ, Jick H. First trimester topical tretinoin and congenital disorders. *Lancet*. 1993;341(8854):1181–1182
58. Patel M, Bowe WP, Heughebaert C, Shalita AR. The development of antimicrobial resistance due to the antibiotic treatment of acne vulgaris: a review. *J Drugs Dermatol*. 2010;9(6):655–664
59. Esterly NB, Koransky JS, Furey NL, Trevisan M. Neutrophil chemotaxis in patients with acne receiving oral tetracycline therapy. *Arch Dermatol*. 1984;120(10):1308–1313
60. Leyden JJ, Del Rosso JQ, Webster GF. Clinical considerations in the treatment of acne vulgaris and other inflammatory skin disorders: focus on antibiotic resistance. *Cutis*. 2007;79(suppl 6):9–25
61. Fleischer AB Jr, Dinehart S, Stough D, Plott RT; Solodyn Phase 2 Study Group; Solodyn Phase 3 Study Group. Safety and efficacy of a new extended-release formulation of minocycline. *Cutis*. 2006;78(suppl 4):21–31
62. Solodyn [package insert]. Scottsdale, AZ: Medicis; 2012
63. Doryx [package insert]. Rockaway, NJ: Warner Chilcott; 2011
64. Minocin [package insert]. Cumberland, RI: Onset Dermatology; 2009
65. Strauss JS, Krowchuk DP, Leyden JJ, et al; American Academy of Dermatology/American Academy of Dermatology Association. Guidelines of care for acne vulgaris management. *J Am Acad Dermatol*. 2007;56(4):651–663
66. Cooper AJ. Systematic review of *Propionibacterium acnes* resistance to systemic antibiotics. *Med J Aust*. 1998;169(5):259–261
67. Leyden JJ, Del Rosso JQ. Oral antibiotic therapy for acne vulgaris: pharmacokinetic and pharmacodynamic perspectives. *J Clin Aesthet Dermatol*. 2011;4(2):40–47
68. Leyden JJ, Kaidbey K, Gans EH. The antimicrobial effects in vivo of minocycline, doxycycline and tetracycline in humans. *J Dermatolog Treat*. 1996;7:223–225
69. Tan HH. Antibacterial therapy for acne: a guide to selection and use of systemic agents. *Am J Clin Dermatol*. 2003;4(5):307–314
70. Del Rosso JQ, Kim G. Optimizing use of oral antibiotics in acne vulgaris. *Dermatol Clin*. 2009;27(1):33–42
71. Amin K, Riddle CC, Aires DJ, Schweiger ES. Common and alternate oral antibiotic therapies for acne vulgaris: a review. *J Drugs Dermatol*. 2007;6(9):873–880

72. Bhambri S, Del Rosso JQ, Desai A. Oral trimethoprim/sulfamethoxazole in the treatment of acne vulgaris. *Cutis*. 2007;79(6):430–434
73. Bjellerup M, Ljunggren B. Double blind cross-over studies on phototoxicity to three tetracycline derivatives in human volunteers. *Photodermatol*. 1987;4(6):281–287
74. Vălean S, Petrescu M, Cătinean A, Chira R, Mircea PA. Pill esophagitis. *Rom J Gastroenterol*. 2005;14(2):159–163
75. Kadayifci A, Gulsen MT, Koruk M, Savas MC. Doxycycline-induced pill esophagitis. *Dis Esophagus*. 2004;17(2):168–171
76. Järvinen A, Nykänen S, Paasiniemi L, et al. Enteric coating reduces upper gastrointestinal adverse reactions to doxycycline. *Clin Drug Investig*. 1995;10(6):323–327
77. Knowles SR, Shear NH. Recognition and management of severe cutaneous drug reactions. *Dermatol Clin*. 2007;25(2):245–253, viii
78. Shapiro LE, Knowles SR, Shear NH. Comparative safety of tetracycline, minocycline, and doxycycline. *Arch Dermatol*. 1997;133(10):1224–1230
79. Brown RJ, Rother KI, Artman H, et al. Minocycline-induced drug hypersensitivity syndrome followed by multiple autoimmune sequelae. *Arch Dermatol*. 2009;145(1):63–66
80. Shaughnessy KK, Bouchard SM, Mohr MR, Herre JM, Salkey KS. Minocycline-induced drug reaction with eosinophilia and systemic symptoms (DRESS) syndrome with persistent myocarditis. *J Am Acad Dermatol*. 2010;62(2):315–318
81. Geria AN, Tajirian AL, Kihiczak G, Schwartz RA. Minocycline-induced skin pigmentation: an update. *Acta Dermatovenerol Croat*. 2009;17(2):123–126
82. Gordon G, Sparano BM, Iatropoulos MJ. Hyperpigmentation of the skin associated with minocycline therapy. *Arch Dermatol*. 1985;121(5):618–623
83. Treister NS, Magalnick D, Woo SB. Oral mucosal pigmentation secondary to minocycline therapy: report of two cases and a review of the literature. *Oral Surg Oral Med Oral Pathol Oral Radiol Endod*. 2004;97(6):718–725
84. Plott RT, Wortzman MS. Key bioavailability features of a new extended-release formulation of minocycline hydrochloride tablets. *Cutis*. 2006;78(suppl 4):6–10
85. Del Rosso JQ. Systemic therapy for rosacea: focus on oral antibiotic therapy and safety. *Cutis*. 2000;66(suppl 4):7–13
86. Tsankov N, Broshtilova V, Kazandjieva J. Tetracyclines in dermatology. *Clin Dermatol*. 2003;21(1):33–39
87. Del Rosso JQ. Clinical significance of brand versus generic formulations: focus on oral minocycline. *Cutis*. 2006;77(3):153–156
88. Friedman DI. Medication-induced intracranial hypertension in dermatology. *Am J Clin Dermatol*. 2005;6(1):29–37
89. Gollnick H, Schramm M. Topical drug treatment in acne. *Dermatology*. 1998;196(1):119–125
90. Margolis DJ, Bowe WP, Hoffstad O, Berlin JA. Antibiotic treatment of acne may be associated with upper respiratory tract infections. *Arch Dermatol*. 2005;141(9):1132–1136
91. Stotland M, Shalita AR, Kissling RF. Dapsone 5% gel: a review of its efficacy and safety in the treatment of acne vulgaris. *Am J Clin Dermatol*. 2009;10(4):221–227
92. Draelos ZD, Carter E, Maloney JM, et al. Two randomized studies demonstrate the efficacy and safety of dapsone gel, 5% for the treatment of acne vulgaris. *J Am Acad Dermatol*. 2007;56(3):439.e1–439.e10
93. Fleischer AB Jr, Shalita A, Eichenfield LF, Abramovits W, Lucky A, Garrett S; Dapsone Gel in Combination Treatment Study Group. Dapsone gel 5% in combination with adapalene gel 0.1%, benzoyl peroxide gel 4% or moisturizer for the treatment of acne vulgaris: a 12-week, randomized, double-blind study. *J Drugs Dermatol*. 2010;9(1):33–40
94. Raimer S, Maloney JM, Bourcier M, et al; United States/Canada Dapsone Gel Study Group. Efficacy and safety of dapsone gel 5% for the treatment of acne vulgaris in adolescents. *Cutis*. 2008;81(2):171–178
95. Piette WW, Taylor S, Pariser D, Jarratt M, Sheth P, Wilson D. Hematologic safety of dapsone gel, 5%, for topical treatment of acne vulgaris. *Arch Dermatol*. 2008;144(12):1564–1570
96. Webster GF. Is topical dapsone safe in glucose-6-phosphate dehydrogenase-deficient and sulfonamide-allergic patients? *J Drugs Dermatol*. 2010;9(5):532–536
97. Goldsmith LA, Bolognia JL, Callen JP, et al; American Academy of Dermatology. American Academy of Dermatology Consensus Conference on the safe and optimal use of isotretinoin: summary and recommendations. *J Am Acad Dermatol*. 2004;50(6):900–906
98. Amnesteem [package insert]. Morgantown, WV: Mylan Pharmaceuticals; 2010
99. Rolanda C, Macedo G. Isotretinoin and inflammatory bowel disease. *Am J Gastroenterol*. 2007;102(6):1330
100. Bankar RN, Dafe CO, Köhnke A, Babu PS. Ulcerative colitis probably associated with isotretinoin. *Indian J Gastroenterol*. 2006;25(3):171–172
101. Passier JL, Srivastava N, van Puijenbroek EP. Isotretinoin-induced inflammatory bowel disease. *Neth J Med*. 2006;64(2):52–54
102. Menecier D, Poyet R, Thiolet C, et al. Ulcerative colitis probably induced by isotretinoin [in French]. *Gastroenterol Clin Biol*. 2005;29(12):1306–1307
103. Borobio E, Arin A, Valcayo A, Iñarrairaegui M, Nantes O, Prieto C. Isotretinoin and ulcerous colitis [in Spanish]. *An Sist Sanit Navar*. 2004;27(2):241–243
104. Melki M, Pouderoux P, Pignodel C, Balmès JL. Granulomatous colitis likely induced by isotretinoin [in French]. *Gastroenterol Clin Biol*. 2001;25(4):433–435
105. Reniers DE, Howard JM. Isotretinoin-induced inflammatory bowel disease in an adolescent. *Ann Pharmacother*. 2001;35(10):1214–1216
106. Deplaix P, Barthélémy C, Védrières P, et al. Probable acute hemorrhagic colitis caused by isotretinoin with a test of repeated administration [in French]. *Gastroenterol Clin Biol*. 1996;20(1):113–114
107. Godfrey KM, James MP. Treatment of severe acne with isotretinoin in patients with inflammatory bowel disease. *Br J Dermatol*. 1990;123(5):653–655
108. Brodin MB. Inflammatory bowel disease and isotretinoin. *J Am Acad Dermatol*. 1986;14(5 pt 1):843
109. Bruno NP, Beacham BE, Burnett JW. Adverse effects of isotretinoin therapy. *Cutis*. 1984;33(5):484–486, 489
110. Martin P, Manley PN, Depew WT, Blakeman JM. Isotretinoin-associated proctosigmoiditis. *Gastroenterology*. 1987;93(3):606–609
111. Spada C, Riccioni ME, Marchese M, Familiari P, Costamagna G. Isotretinoin-associated pan-enteritis. *J Clin Gastroenterol*. 2008;42(8):923–925
112. Medicines and Healthcare products Regulatory Agency. *Drug Analysis Print: Isotretinoin*. Available at: www.mhra.gov.uk/home/groups/public/documents/sentinel/documents/dap_1242820880005.pdf. Accessed March 19, 2013
113. Nishimura G, Mugishima H, Hirao J, Yamato M. Generalized metaphyseal modification with cone-shaped epiphyses following long-term administration of 13-cis-retinoic acid. *Eur J Pediatr*. 1997;156(6):432–435
114. Margolis DJ, Fanelli M, Hoffstad O, Lewis JD. Potential association between the oral tetracycline class of antimicrobials used to treat acne and inflammatory bowel disease. *Am J Gastroenterol*. 2010;105(12):2610–2616

115. Tekin NS, Ozdolap S, Sarikaya S, Keskin SI. Bone mineral density and bone turnover markers in patients receiving a single course of isotretinoin for nodulocystic acne. *Int J Dermatol.* 2008;47(6):622–625
116. Vestergaard P, Rejnmark L, Mosekilde L. High-dose treatment with vitamin A analogues and risk of fractures. *Arch Dermatol.* 2010;146(5):478–482
117. Steele RG, Lugg P, Richardson M. Premature epiphyseal closure secondary to single-course vitamin A therapy. *Aust N Z J Surg.* 1999;69(11):825–827
118. Milstone LM, McGuire J, Ablow RC. Premature epiphyseal closure in a child receiving oral 13-cis-retinoic acid. *J Am Acad Dermatol.* 1982;7(5):663–666
119. Inamo Y, Suzuki T, Mugishima H. A case of growth failure caused by 13-CIS-retinoic acid administration after bone marrow transplantation for neuroblastoma. *Endocr J.* 1999;46(suppl):S113–S115
120. Schleicher SM. Oral isotretinoin and inflammatory bowel disease. *J Am Acad Dermatol.* 1985;13(5 pt 1):834–835
121. Leyden JJ. Retinoids and acne. *J Am Acad Dermatol.* 1988;19(1 pt 2):164–168
122. Macdonald Hull S, Cunliffe WJ. The safety of isotretinoin in patients with acne and systemic diseases. *J Dermatolog Treat.* 1989;1:35–37
123. McHenry PM, Hudson M, Smart LM, Rennie JA, Mowat NA, White MI. Pyoderma faciale in a patient with Crohn's disease. *Clin Exp Dermatol.* 1992;17(6):460–462
124. Tsianos EV, Dalekos GN, Tzermias C, Merkouropoulos M, Hatzis J. Hidradenitis suppurativa in Crohn's disease. A further support to this association. *J Clin Gastroenterol.* 1995;20(2):151–153
125. Velez A, Alcalá J, Fernandez-Roldan JC. Pyoderma gangrenosum associated with acne conglobata. *Clin Exp Dermatol.* 1995;20(6):496–498
126. Rosen T, Unkefer RP. Treatment of pyoderma faciale with isotretinoin in a patient with ulcerative colitis. *Cutis.* 1999;64(2):107–109
127. Gatzka M, Simon M, Schuler G, Lüftl M. Rosacea fulminans, pyostomatitis and pyovulvitis in Crohn's disease: dapsone as key factor in combination therapy [in German]. *Hautarzt.* 2006;57(10):898–902
128. Guslandi M. Isotretinoin and inflammatory bowel disease. *Am J Gastroenterol.* 2007;102(7):1546–1547
129. Reddy D, Siegel CA, Sands BE, Kane S. Possible association between isotretinoin and inflammatory bowel disease. *Am J Gastroenterol.* 2006;101(7):1569–1573
130. Crockett SD, Porter CQ, Martin CF, Sandler RS, Kappelman MD. Isotretinoin use and the risk of inflammatory bowel disease: a case-control study. *Am J Gastroenterol.* 2010;105(9):1986–1993
131. Bernstein CN, Nugent Z, Longobardi T, Blanchard JF. Isotretinoin is not associated with inflammatory bowel disease: a population-based case-control study. *Am J Gastroenterol.* 2009;104(11):2774–2778
132. Crockett SD, Gulati A, Sandler RS, Kappelman MD. A causal association between isotretinoin and inflammatory bowel disease has yet to be established. *Am J Gastroenterol.* 2009;104(10):2387–2393
133. Bremner JD, Fani N, Ashraf A, et al. Functional brain imaging alterations in acne patients treated with isotretinoin. *Am J Psychiatry.* 2005;162(5):983–991
134. Marqueling AL, Zane LT. Depression and suicidal behavior in acne patients treated with isotretinoin: a systematic review. *Semin Cutan Med Surg.* 2007;26(4):210–220
135. Cohen J, Adams S, Patten S. No association found between patients receiving isotretinoin for acne and the development of depression in a Canadian prospective cohort. *Can J Clin Pharmacol.* 2007;14(2):e227–e233
136. Kaymak Y, Taner E, Taner Y. Comparison of depression, anxiety and life quality in acne vulgaris patients who were treated with either isotretinoin or topical agents. *Int J Dermatol.* 2009;48(1):41–46
137. McGrath EJ, Lovell CR, Gillison F, Darvay A, Hickey JR, Skevington SM. A prospective trial of the effects of isotretinoin on quality of life and depressive symptoms. *Br J Dermatol.* 2010;163(6):1323–1329
138. Rehn LM, Meririnne E, Höök-Nikanne J, Isometsä E, Henriksson M. Depressive symptoms and suicidal ideation during isotretinoin treatment: a 12-week follow-up study of male Finnish military conscripts. *J Eur Acad Dermatol Venereol.* 2009;23(11):1294–1297
139. Cook-Bolden F, Chen D, Eichenfield L, Stein-Gold L. Managing moderate to severe acne in adolescents: benefits of a fixed combination clindamycin phosphate (1.2%) and low concentration benzoyl peroxide (2.5%) aqueous gel in a subpopulation of 1,755 subjects. Poster presented at the 67th Annual Meeting of American Academy of Dermatology; March 6–10, 2009; San Francisco, CA
140. Eichenfield LE, Jorizzo JL, Dirschka T, et al. Treatment of 2,453 acne vulgaris patients aged 12–17 years with the fixed-dose adapalene-benzoyl peroxide combination topical gel: efficacy and safety. *J Drugs Dermatol.* 2010;9(11):1395–1401
141. Yentzer BA, Ade RA, Fountain JM, et al. Simplifying regimens promotes greater adherence and outcomes with topical acne medications: a randomized controlled trial. *Cutis.* 2010;86(2):103–108
142. Sabatier JP, Guaydier-Souquière G, Benmalek A, Marcelli C. Evolution of lumbar bone mineral content during adolescence and adulthood: a longitudinal study in 395 healthy females 10–24 years of age and 206 premenopausal women. *Osteoporos Int.* 1999;9(6):476–482
143. Cromer BA, Bonny AE, Stager M, et al. Bone mineral density in adolescent females using injectable or oral contraceptives: a 24-month prospective study. *Fertil Steril.* 2008;90(6):2060–2067
144. Lloyd T, Petit MA, Lin HM, Beck TJ. Lifestyle factors and the development of bone mass and bone strength in young women. *J Pediatr.* 2004;144(6):776–782
145. Burke BM, Cunliffe WJ. Oral spironolactone therapy for female patients with acne, hirsutism or androgenic alopecia. *Br J Dermatol.* 1985;112(1):124–125
146. Shaw JC. Low-dose adjunctive spironolactone in the treatment of acne in women: a retrospective analysis of 85 consecutively treated patients. *J Am Acad Dermatol.* 2000;43(3):498–502
147. Goodfellow A, Alaghband-Zadeh J, Carter G, et al. Oral spironolactone improves acne vulgaris and reduces sebum excretion. *Br J Dermatol.* 1984;111(2):209–214
148. Muhlemann MF, Carter GD, Cream JJ, Wise P. Oral spironolactone: an effective treatment for acne vulgaris in women. *Br J Dermatol.* 1986;115(2):227–232
149. Kim GK, Del Rosso JQ. Oral spironolactone in post-teenage female patients with acne vulgaris: practical considerations for the clinician based on current data and clinical experience. *J Clin Aesthet Dermatol.* 2012;5(3):37–50
150. Brown J, Farquhar C, Lee O, Toomath R, Jepson RG. Spironolactone versus placebo or in combination with steroids for hirsutism and/or acne. *Cochrane Database Syst Rev.* 2009;(2):CD000194
151. Poli F. Acne on pigmented skin. *Int J Dermatol.* 2007;46(suppl 1):39–41
152. Del Rosso JQ. Study results of benzoyl peroxide 5%/clindamycin 1% topical gel, adapalene 0.1% gel, and use in combination for acne vulgaris. *J Drugs Dermatol.* 2007;6(6):616–622
153. Webster G, Del Rosso JQ. Anti-inflammatory activity of tetracyclines. *Dermatol Clin.* 2007;25(2):133–135, v

154. Sapadin AN, Fleischmajer R. Tetracyclines: nonantibiotic properties and their clinical implications. *J Am Acad Dermatol*. 2006;54(2):258–265
155. Skidmore R, Kovach R, Walker C, et al. Effects of subantimicrobial-dose doxycycline in the treatment of moderate acne. *Arch Dermatol*. 2003;139(4):459–464
156. Yan AC, Treat JR. Beyond first-line treatment: management strategies for maintaining acne improvement and compliance. *Cutis*. 2008;82(2 suppl 1):18–25
157. Patel P, Lin HC, Feldman SR, Fleischer AB Jr, Nahata MC, Balkrishnan R. Medication choice and associated health care outcomes and costs for patients with acne and acne-related conditions in the United States. *J Drugs Dermatol*. 2011;10(7):766–771
158. Koo J. How do you foster medication adherence for better acne vulgaris management? *Skinmed*. 2003;2(4):229–233
159. Flanders PA, McNamara JR. Enhancing acne medication compliance: a comparison of strategies. *Behav Res Ther*. 1985;23(2):225–227
160. Baldwin HE. Tricks for improving compliance with acne therapy. *Dermatol Ther*. 2006;19(4):224–236
161. Draelos ZD. Improving compliance in acne treatment: benzoyl peroxide considerations. *Cutis*. 2008;82(suppl 5):17–20
162. Halvorsen JA, Stern RS, Dalgard F, Thoresen M, Bjertness E, Lien L. Suicidal ideation, mental health problems, and social impairment are increased in adolescents with acne: a population-based study. *J Invest Dermatol*. 2011;131(2):363–370
163. Campbell JL. Counseling to optimize compliance in adolescent acne patients treated with topical retinoids. Poster presented at Academy '04. New York, NY
164. Bowe WP, Joshi SS, Shalita AR. Diet and acne. *J Am Acad Dermatol*. 2010;63(1):124–141
165. Adebamowo CA, Spiegelman D, Danby FW, Frazier AL, Willett WC, Holmes MD. High school dietary dairy intake and teenage acne. *J Am Acad Dermatol*. 2005;52(2):207–214
166. Adebamowo CA, Spiegelman D, Berkey CS, et al. Milk consumption and acne in adolescent girls. *Dermatol Online J*. 2006;12(4):1
167. Adebamowo CA, Spiegelman D, Berkey CS, et al. Milk consumption and acne in teenaged boys. *J Am Acad Dermatol*. 2008;58(5):787–793
168. Cordain L, Lindeberg S, Hurtado M, Hill K, Eaton SB, Brand-Miller J. Acne vulgaris: a disease of Western civilization. *Arch Dermatol*. 2002;138(12):1584–1590
169. Smith RN, Mann NJ, Braue A, Mäkeläinen H, Varigos GA. The effect of a high-protein, low glycemic-load diet versus a conventional, high glycemic-load diet on biochemical parameters associated with acne vulgaris: a randomized, investigator-masked, controlled trial. *J Am Acad Dermatol*. 2007;57(2):247–256
170. Smith RN, Braue A, Varigos GA, Mann NJ. The effect of a low glycemic load diet on acne vulgaris and the fatty acid composition of skin surface triglycerides. *J Dermatol Sci*. 2008;50(1):41–52
171. Smith RN, Mann NJ, Braue A, Mäkeläinen H, Varigos GA. A low-glycemic-load diet improves symptoms in acne vulgaris patients: a randomized controlled trial. *Am J Clin Nutr*. 2007;86(1):107–115

(Continued from first page)

ABBREVIATIONS

AARS—American Acne and Rosacea Society

BIH—benign intracranial hypertension

BMD—bone mineral density

BP—benzoyl peroxide

DHS—drug hypersensitivity syndrome

FDA—Food and Drug Administration

IBD—inflammatory bowel disease

LLS—lupuslike syndrome

NCP—neonatal cephalic pustulosis

OC—oral contraceptive

OTC—over-the-counter

PCOS—polycystic ovary syndrome

PIH—postinflammatory hyperpigmentation

SOR—Strength of Recommendation

www.pediatrics.org/cgi/doi/10.1542/peds.2013-0490B

doi:10.1542/peds.2013-0490B

Accepted for publication Feb 21, 2013

Address correspondence to Lawrence F. Eichenfield, MD, 8010 Frost Street, Ste 602, San Diego, CA 92130. E-mail: leichenfield@rchsd.org

PEDIATRICS (ISSN Numbers: Print, 0031-4005; Online, 1098-4275).

Copyright © 2013 by the American Academy of Pediatrics

FINANCIAL DISCLOSURE: All authors filed relevant conflicts of interest statements with the American Acne and Rosacea Society (AARS) and the American Academy of Pediatrics (AAP). They received compensation from the AARS for participation in this consensus conference. Their participation included preparatory conference calls, planning communications, extensive literature search and research on subject, preparation of presentations including slides, and manuscript development, writing, and editing. No corporate benefactor of the AARS or AAP had any input into content preparation, data review, or any involvement in the outcome of the meeting or publication. Physician Resources, LLC provided editorial and research assistance to the AARS throughout the process.

FUNDING: The AARS, a nonprofit organization, received educational grant funding from annual corporate benefactors to fund this article. Those benefactors include Galderma Laboratories, Medicis Pharmaceuticals, Ortho Dermatologics, and Valeant Pharmaceuticals. No corporate benefactor of the AARS or AAP had any input into content preparation or data review, or any involvement in the outcome of the meeting or publication.

Evidence-Based Recommendations for the Diagnosis and Treatment of Pediatric Acne

Lawrence F. Eichenfield, Andrew C. Krakowski, Caroline Piggott, James Del Rosso, Hilary Baldwin, Sheila Fallon Friedlander, Moise Levy, Anne Lucky, Anthony J. Mancini, Seth J. Orlow, Albert C. Yan, Keith K. Vaux, Guy Webster, Andrea L. Zaenglein and Diane M. Thiboutot
Pediatrics 2013;131;S163
DOI: 10.1542/peds.2013-0490B

Updated Information & Services	including high resolution figures, can be found at: http://pediatrics.aappublications.org/content/131/Supplement_3/S163
References	This article cites 160 articles, 3 of which you can access for free at: http://pediatrics.aappublications.org/content/131/Supplement_3/S163#BIBL
Subspecialty Collections	This article, along with others on similar topics, appears in the following collection(s): Dermatology http://www.aappublications.org/cgi/collection/dermatology_sub Evidence-Based Medicine http://www.aappublications.org/cgi/collection/evidence-based_medicine_sub
Permissions & Licensing	Information about reproducing this article in parts (figures, tables) or in its entirety can be found online at: http://www.aappublications.org/site/misc/Permissions.xhtml
Reprints	Information about ordering reprints can be found online: http://www.aappublications.org/site/misc/reprints.xhtml

American Academy of Pediatrics

DEDICATED TO THE HEALTH OF ALL CHILDREN™



PEDIATRICS®

OFFICIAL JOURNAL OF THE AMERICAN ACADEMY OF PEDIATRICS

Evidence-Based Recommendations for the Diagnosis and Treatment of Pediatric Acne

Lawrence F. Eichenfield, Andrew C. Krakowski, Caroline Piggott, James Del Rosso, Hilary Baldwin, Sheila Fallon Friedlander, Moise Levy, Anne Lucky, Anthony J. Mancini, Seth J. Orlow, Albert C. Yan, Keith K. Vaux, Guy Webster, Andrea L. Zaenglein and Diane M. Thiboutot

Pediatrics 2013;131;S163

DOI: 10.1542/peds.2013-0490B

The online version of this article, along with updated information and services, is located on the World Wide Web at:

http://pediatrics.aappublications.org/content/131/Supplement_3/S163

Pediatrics is the official journal of the American Academy of Pediatrics. A monthly publication, it has been published continuously since 1948. Pediatrics is owned, published, and trademarked by the American Academy of Pediatrics, 141 Northwest Point Boulevard, Elk Grove Village, Illinois, 60007. Copyright © 2013 by the American Academy of Pediatrics. All rights reserved. Print ISSN: 1073-0397.

American Academy of Pediatrics

DEDICATED TO THE HEALTH OF ALL CHILDREN™

