

# Cancer eye in cattle

September 2015 Primefact 1422 first edition

Graham Bailey Cattle Health Coordinator Animal Biosecurity Orange

## Summary

Eye cancer occurs in older cattle, particularly Herefords, Poll Herefords and Friesians with unpigmented eyelids and eyeballs.

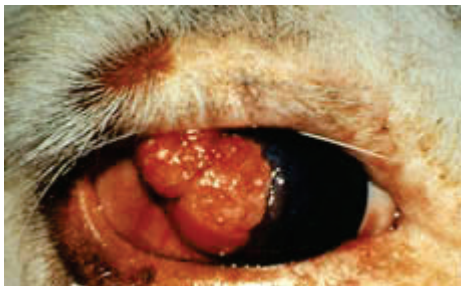Control by culling animals with early signs of cancer eye.

Prevent by crossbreeding or by strong selection for eyelid pigment.

Never breed from affected or treated animals.

## Introduction

**Figure 1** A typical cancer of the eyeball, characterised by a pink, fleshy growth. Animals with such cancers should be disposed of promptly.



Cancer eye (ocular squamous cell carcinoma) is the most common form of cancer in cattle. It is a skin cancer occurring on the eye and eyelids. Estimates of its prevalence vary from 1% to 20% in some herds. Some of the predisposing factors are heritable, and in certain lines or families nearly all cattle may be affected during their lifetime.

Australian Quarantine Inspection Service abattoir figures (2010-2014) from NSW indicate that 33% of total condemnations in mature cattle, and 6.6% of condemnations in young cattle (steers and heifers) are due to cancer eye. Overall, cancer eye represents 58% of all cancers that result in condemnation of mature cattle slaughtered in NSW.

## Cancer eye lesions

Cancer eye growths can occur on the eyeball, eyelid or third eyelid.

All eye cancers develop from precursor lesions, but less than half of these lesions develop into cancer. The precursor lesion can be:

- a plaque (a slightly elevated, flat, opaque area on the eyeball)
- a papilloma (a wart-like growth protruding from the eyeball)
- a keratoma (a horn-like projection attached to the eyelid)
- a small ulcer on the eyelid.

As the disease progresses from the precursor stage to the cancer stage, the tumour becomes ulcerated. Bleeding and weeping are common. Bacteria invade the lesion, which usually develops externally into a festering, foul-smelling growth.

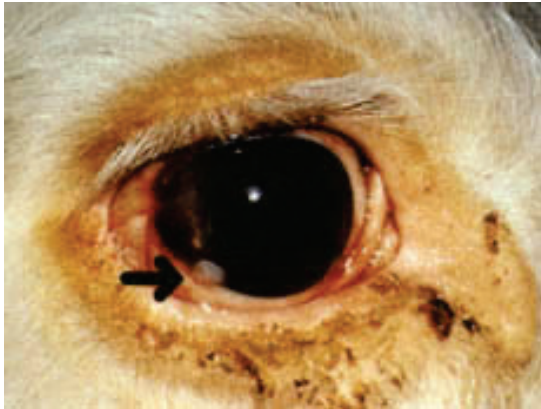
The cancerous tissue also grows inwards, invading the deeper tissues behind the eye. It can progress to the lymph nodes of the head and then to body organs such as the lungs and liver.

Cancers that begin in the third eyelid or outer eyelids usually invade the deeper tissues more quickly than do those that start on the eyeball.

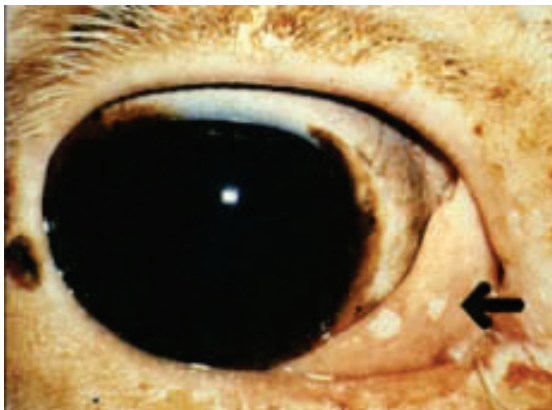
Untreated cattle may live for 2–5 years after the first appearance of a cancerous lesion, although such cattle may become weak and emaciated within 6 months, indicating the involvement of internal organs.

It is more common for only one eye to be affected, but occasionally the condition may occur in both eyes.

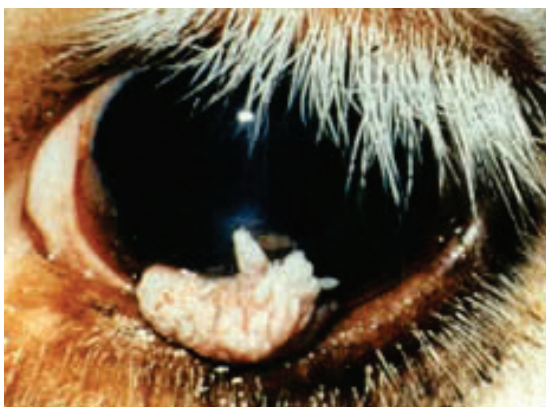**Figure 2** A plaque on the edge of the eyeball. Only some of these types of lesions will progress to become tumours, and some will regress spontaneously, but it is advisable to cull such animals.



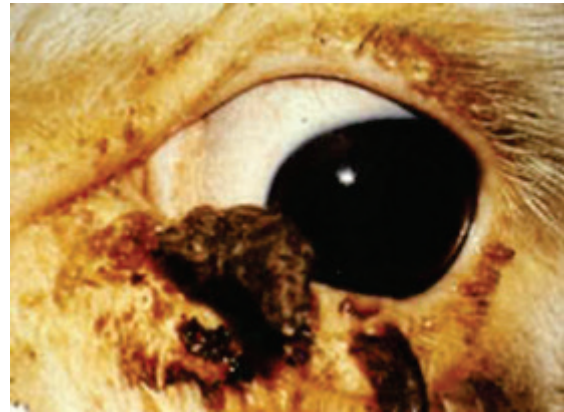**Figure 3** Two plaques on the third eyelid. Note the poor pigmentation of the eyelids and third eyelid.



**Figure 4** A well-developed papilloma. Such lesions can be removed with a cautery by a vet, but these animals should be disposed of as soon as practicable, and not be used for breeding.



**Figure 5** Watch for horny growths around the eye—they may also turn into cancers.



## Treatment

Surgical treatment of cancer eye is possible, particularly in the early stages, and is warranted if, for example, a cow has a young calf. Small lesions can be removed by electrocautery (burning) or cryosurgery (freezing). A veterinarian may also surgically remove lesions from the eyelids or third eyelid, scrape a lesion from the eyeball, or remove the whole eye.

In some cases, removal of very early precursor lesions may result in a permanent cure. However, more than 60% of cases recur and it is not good practice to continue to breed from treated cattle or from their progeny.

## Factors affecting incidence of cancer eye

### Pigmentation

Cattle with unpigmented skin around the eyes are more susceptible to cancer eye. Cancers usually start on unpigmented skin, but can then spread to pigmented areas. Eyelid pigment is present at birth and is easily assessed. Eyeball pigment usually takes more than 5 years to develop fully. Pigmentation of the eyelids and pigmentation of the eyeball are highly heritable and appear to be genetically related.

### Breed

The disease occurs in cattle that have areas of unpigmented skin or conjunctiva. Breeds such as Hereford, Poll Hereford and white-faced Friesian are most susceptible, with Hereford crosses being less susceptible than purebreds. Cancer eye is rare in breeds with fully pigmented skin, such as Angus and Santa Gertrudis.

## Age

Older cattle are more prone to cancer eye. The disease is uncommon in cows under 5 years of age. Males and females are equally susceptible, but the cancer is seen less frequently in males because steers are sent for slaughter at an early age, and bulls tend to be culled at an earlier age than cows.

## Ultraviolet solar radiation

Increased ultraviolet (UV) radiation is thought to predispose cattle to cancer eye. Therefore cattle living at low latitudes and high altitudes may be at greater risk, because latitude, altitude and daily hours of sunlight all contribute to the amount of UV radiation.

## Strain and sire

Susceptibility to the disease varies with strain and sire. The heritability of cancer eye has been estimated as moderate at 0.2-0.3.


## Other factors

Other factors have been suggested to have an affect on the development of cancer eye. These include nutrition, pregnancy and viruses. It is not clear what if any affect these have.

## Prevention

Cancer eye can be controlled by selective breeding. Selection for pigmented eyelids is most effective and can result in rapid improvement in the herd. This selection is recommended for all Hereford herds.

**Figure 6** Selection for pigmentation around the eyes in Herefords will help prevent cancer eye.



Eyeball pigmentation develops slowly, but apparently is genetically linked to eyelid pigmentation, so selection for one, in effect, selects for both.

Lower-lid pigmentation is more important than pigmentation of the upper lid. The intensity of pigmentation is not important as long as it is darker than just a pale brown.

Unlike eyeball pigment, third-eyelid pigment is not affected by selection for external eyelid pigment. Third-eyelid cancers account for about 10% of cancers in Herefords. They are easily removed by surgery in the early stages. Treated cows and their progeny should be culled as soon as practicable to select against this form of cancer eye.

Breeders not committed to producing pure Herefords should consider crossbreeding if cancer eye is a problem.

There are strain and sire differences. Breeders who identify families that are more susceptible, or sires whose progeny are more susceptible, should move away from these lines in their breeding program.

## Welfare and sale

On extensive properties, where disease may become well advanced before it is detected, severely affected stock should be destroyed for humane reasons as soon as they are found.

Stock with moderate to severe disease (e.g. those with tumours that are large and ulcerated or have a detectable odour) that is likely to cause increased pain or distress during a journey are not fit for transportation. If transported to a saleyard, they may be judged unfit for sale and condemned. Animals with all but very early, non-protruding lesions should be sent directly to the abattoir if regarded as still saleable, rather than to public saleyards.

If there is any evidence of spread of the cancer to nearby lymph nodes, such as lumps under the ear or jaw, the animal will be condemned at abattoir inspection. Such animals should be humanely destroyed.

A good manager will inspect stock regularly, recognise the early stages of cancer eye and cull affected animals immediately. This way the animals suffer little discomfort and the carcass will usually be passed for human consumption, thus minimising financial loss. Occasionally, however, an apparently small cancer may have already spread internally, in which case the carcass will be condemned.

## Acknowledgments

The original version of this Agfact was written by David Gardiner, former Veterinary Officer with NSW Agriculture. Additional information suggested for inclusion by Barbara Vanselow is gratefully acknowledged.

Photos were provided by:

- Barbara Vanselow, NSW Agriculture Beef Industry Centre, Armidale
- University of Queensland Faculty of Veterinary Science
- Belinda Walker, NSW Agriculture, Gunnedah.

For updates go to

[www.dpi.nsw.gov.au/factsheets](http://www.dpi.nsw.gov.au/factsheets)

---

© State of New South Wales through the Department of Trade and Investment, Regional Infrastructure and Services 2015. You may copy, distribute and otherwise freely deal with this publication for any purpose, provided that you attribute the NSW Department of Primary Industries as the owner.

Disclaimer: The information contained in this publication is based on knowledge and understanding at the time of writing (October 2015). However, because of advances in knowledge, users are reminded of the need to ensure that information upon which they rely is up to date and to check currency of the information with the appropriate officer of the Department of Primary Industries or the user's independent adviser.

Published by the NSW Department of Primary Industries.

ISSN: 1832-6668

PUB15/387