

See discussions, stats, and author profiles for this publication at: <https://www.researchgate.net/publication/6311348>

# Interpreting Serological Tests in Diagnosing Autoimmune Liver Diseases

Article in *Seminars in Liver Disease* · June 2007

DOI: 10.1055/s-2007-979469 · Source: PubMed

---

CITATIONS

95

---

READS

1,029

3 authors, including:



**Pietro Invernizzi**

Università degli Studi di Milano-Bicocca

407 PUBLICATIONS 12,833 CITATIONS

SEE PROFILE



**Ana Lleo**

Istituto Clinico Humanitas IRCCS

157 PUBLICATIONS 4,287 CITATIONS

SEE PROFILE

Some of the authors of this publication are also working on these related projects:



Genetics of PBC [View project](#)



Epidemiology of Primary Biliary Cholangitis [View project](#)

# Interpreting Serological Tests in Diagnosing Autoimmune Liver Diseases

Pietro Invernizzi, M.D., Ph.D.,<sup>1</sup> Ana Lleo, M.D.,<sup>1</sup> and Mauro Podda, M.D.<sup>1</sup>

## ABSTRACT

Autoimmune liver diseases (ALD) are characterized by immune-mediated injury of bile ducts or hepatocytes, thus including cholangiopathies such as primary biliary cirrhosis (PBC), primary sclerosing cholangitis, and autoimmune hepatitis. Further, ALD variants manifesting with both hepatocellular and cholangiocellular damage are becoming more common. Serum autoantibodies, together with imaging and histology, are critical to the diagnostic process when ALD is suspected. Because an early diagnosis can influence prognosis, the development of sensitive and specific tests for serum autoantibodies should be a priority for researchers to ensure a more efficient noninvasive workup. Little prognostic value has been observed for any of the ALD serum hallmarks, and a vigorous effort to investigate new and old markers should therefore be undertaken in longitudinal studies as in the recent paradigm of PBC-specific antinuclear antibodies. We review herein the numerous ALD screening tests available in routine and specialized laboratories and comment on their significance in clinical practice.

**KEYWORDS:** Autoimmune hepatitis, primary biliary cirrhosis, primary sclerosing cholangitis, overlap syndromes, serum autoantibodies

The field of autoimmune liver disease (ALD) is showing how the findings of basic science can influence routine clinical practice in terms of diagnostic procedures, clinical management, and prediction of outcome, although more work needs to be done to translate growing basic knowledge into clinical science. The diagnosis of ALD in a patient with liver disease requires the exclusion of other causes of liver damage, viral, alcoholic, toxic, genetic, metabolic, or nonalcoholic fatty liver disease, and a careful evaluation of clinical, biochemical, histopathological, and cholangiographic characteristics specific to each of the major ALD entities, autoimmune hepatitis (AIH), primary biliary cirrhosis (PBC), and, possibly, primary sclerosing cholangitis (PSC). Although few of these disease features are individually diagnostic

and most of the criteria have limited sensitivity and specificity, particular combinations of features can have very high sensitivity and specificity—but this area is in need of further development. Notably, with increasingly precise diagnostic definition among conditions categorized as ALD, increasing numbers of overlap cases are being reported.<sup>1,2</sup>

The detection and interpretation of serum autoantibodies has a major diagnostic role and allows the distinction of subsets of patients with different outcomes. Since the first serum autoantibodies were described in the 1950s,<sup>3</sup> continuing efforts have been made to develop their molecular definition and improve their diagnostic and prognostic utility in clinical practice. In this current age of advanced molecular biology, we are

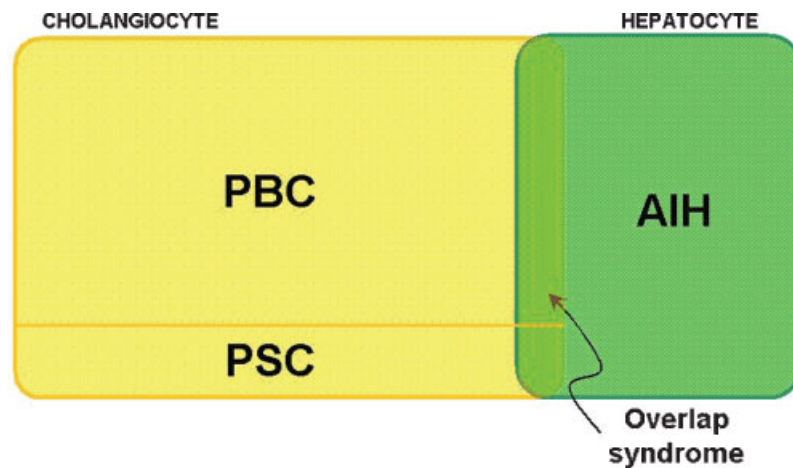
<sup>1</sup>Division of Internal Medicine and Liver Unit, San Paolo Hospital School of Medicine, University of Milan, Milan, Italy.

Address for correspondence and reprint requests: Pietro Invernizzi, M.D., Ph.D., Division of Internal Medicine and Liver Unit, San Paolo Hospital School of Medicine, University of Milan, Via di Rudini 8, 20142 Milano, Italy.

Lymphocytes and Liver: Domestic Bliss or Dangerous Liaisons; Guest Editors, M. Eric Gershwin, M.D., Ian R. Mackay, M.D.

Semin Liver Dis 2007;27:161–172. Copyright © 2007 by Thieme Medical Publishers, Inc., 333 Seventh Avenue, New York, NY 10001, USA. Tel: +1(212) 584-4662.

DOI 10.1055/s-2007-979469. ISSN 0272-8087.



**Figure 1** Primary targets of immune-mediated injury in autoimmune liver diseases. The illustration depicts the liver cellular subpopulations (cholangiocytes and hepatocytes) known to be the target of autoimmune aggression in patients with primary biliary cirrhosis (PBC), primary sclerosing cholangitis (PSC), and autoimmune hepatitis (AIH), respectively.

realizing widening diagnostic possibilities offered by new techniques for detecting autoantibodies.

ALD can be classified into two main entities according to the cell type primarily affected by immune injury: hepatocyte and cholangiocyte (Fig. 1). Although the pathology of AIH is more uniform, that of autoimmune cholangiopathies comprehends disease of the intrahepatic (PBC) and extrahepatic (PSC) biliary ducts. Whereas PBC is a prototypic autoimmune disease and a prototypic model for the study of immunopathogenesis, the inclusion of PSC among the autoimmune diseases is controversial and criteria are only weakly fulfilled. In the past, the term “autoimmune cholangitis” has been proposed for a subset of PBC patients lacking antimitochondrial antibodies (AMAs) by conventional methodology but expressing certain antinuclear antibodies (ANAs). However, more recent evidence suggests that these patients are affected by a disease not far different from classical PBC. The possibility that hepatocytes and cholangiocytes can undergo simultaneous injury has led to the nomination of different “overlap syndromes” involving AIH, and better clarification of these is a high priority.

This article presents a concise review of the literature on serum autoantibodies in ALD and discusses the current and emerging evidence regarding their clinical significance.

## AUTOIMMUNE HEPATITIS

AIH is a chronic disease related to immune-mediated destruction of hepatocytes consequential on loss of immune tolerance against liver cells<sup>4</sup> (Fig. 1). The presence of ANA, smooth muscle antibody (SMA), or liver-kidney microsome type 1 autoantibodies (anti-LKM-1) facilitates diagnosis and discriminates two distinct subtypes, AIH-1 and AIH-2. The different

serological reactivities for these two subtypes (ANA, SMA in AIH-1 and anti-LKM-1 in AIH-2) are virtually mutually exclusive; in rare cases of “double-positive” serology, the clinical expression resembles that of AIH-2.<sup>5</sup> Table 1 shows their clinical, epidemiological, and biochemical differences.

## AIH Diagnostic Criteria

The capacity for diagnosis of AIH in clinical practice, and particularly in epidemiologic studies, was improved by the introduction of a set of descriptive criteria by the International Autoimmune Hepatitis Group in 1993 (revised in 1999).<sup>6,7</sup> This scoring system consists of

**Table 1 Summary Comparison of Clinical, Serological, Epidemiological, and Genetic Characteristics of Autoimmune Hepatitis Subtypes<sup>4</sup>**

Clinical Features	Type 1	Type 2
Diagnostic autoantibodies	SMA, ANA, antiactin	Anti-LKM* P450 IID6
Age (y)	Bimodal (10–20, 45–70)	Pediatric (2–14)
Female (%)	78	89
Autoimmune comorbidity (%) <sup>†</sup>	41	34
Gamma-globulin ↑	+++	++
IgA ↓	No	Occasional
HLA association	B8, DR3, DR4	B14, DR3, C4AQ0
Steroid response	+++	+++
Progression to cirrhosis (%)	70	80

\*There are various anti-LKMs as well as IID6 (see reference 10).

<sup>†</sup>The comorbidities differ for the two types.<sup>4</sup> ANA, antinuclear antibody; HLA, human leukocyte antigen; IgA, immunoglobulin A; LKM, liver-kidney microsome; SMA, smooth muscle antibody.

several clinical, biochemical, and histological characteristics in which autoantibodies are essential elements. AIH can be *definitely* diagnosed when the cumulative score is greater than 15 in untreated patients and greater than 17 in treated patients and *probably* diagnosed on lower scores. The 1999 criteria using the definite score are highly sensitive (89%) and their overall specificity for the exclusion of AIH is 89.5% (against 65% for the original system). The criteria also seem to distinguish AIH and PSC more clearly.<sup>6</sup> A probable score has a much lower specificity. More recently, a simplified system has also been proposed, but its utility is still being evaluated (A.W. Lohse et al, unpublished data). The role of liver histology in the management of AIH remains critical, and a patient with suspected AIH should undergo percutaneous liver biopsy because histology remains the “gold standard” for grading and staging<sup>8</sup>; although no single histologic feature is sufficient to prove the diagnosis, interface hepatitis, lobular hepatitis, and prominence of plasma cells are strong pointers.

**Serum Autoantibodies in AIH**

In 2004, a subcommittee of the International Autoimmune Hepatitis Group established procedures and reference guidelines for more reliable serum autoantibody testing to overcome the previous lack of standardization.<sup>9</sup> Although tests for serum ANA, SMA, and LKM are critical for the diagnosis of AIH,<sup>10</sup> suspected

cases should also be tested for autoantibodies to other antigens, including soluble liver antigen/liver pancreas antigen (SLA/LP), antineutrophil cytoplasmic antigens (p-ANCA), and asialoglycoprotein receptor that can occur in AIH-1 and liver-cytosol type 1 that can occur in AIH-2. Finally, other much less specific autoantibodies can also be detected in some patients,<sup>11,12</sup> although they have limited if any clinical utility (Table 2).

**ANA**

ANAs were the first autoantibodies observed in AIH sera (over 50 years ago) and are still the most sensitive marker of AIH. Screening determinations of ANA are routinely made by means of indirect immunofluorescence (IIF) on cryostat sections of composite blocks of rodent multiorgan substrate panel that should include liver, kidney, and stomach. For positive sera, the pattern of nuclear staining then has to be assessed by use of HEp2 cells. ANAs in AIH usually have a homogeneous pattern that fades to a speckled pattern on remission. Minimal titers for positivity are 1:40 for tissue sections and 1:160 for HEp2 cells, but titers are usually much higher. Of course, a positive ANA test of itself is not specific for AIH because ANA positivity in sera occurs in patients with other autoimmune diseases, viral diseases, or even in older healthy subjects.<sup>13</sup> However, in a woman with a severe and acute liver disease and a hepatocellular derangement of liver functional indices, the presence of a homogeneous ANA IIF clearly indicates AIH.

**Table 2 Serum Immunoreactivities and Target Antigens in Autoimmune Hepatitis**

Autoantibody	Autoantigen	Liver Disease*	Clinical Features
ANA	Centromere, ribonucleoproteins	AIH, PBC, PSC, HCV, HBV, HDV, NASH, drug-induced hepatitis	
SMA (anti-G-actin, anti-intermediate filaments)	Monomeric/glomerular form of actin, tubulin, vimentin, desmin, cytokeratins	AIH, PBC, PSC, HCV, HBV, HDV, NASH, drug-induced hepatitis	
SMA (anti-F-actin)	Native/filamentous form of actin	AIH-1	Poor prognosis, young patients
LKM-1	Cyp P450 2D6	AIH-2, HCV	
LKM-3	UGT1A	AIH-2, HDV, HCV, APECED	
LC-1	Formiminotransferase cyclodeaminase	AIH-2, HCV	High level of disease activity, younger patients
SLA	UGA repressor tRNA-associated protein	AIH, HCV	Severe course, relapse after drug withdrawal
ASGPR	Asialoglycoprotein receptor	AIH, PBC, HCV, HBV, HDV, drug-induced hepatitis	High level of disease activity
Chromatin	Chromatin	AIH, HCV, HBV	High level of disease activity, relapse after drug withdrawal
CLA	Cardiolipin	AIH, HCV, HBV	High level of disease activity
p-ANCA/p-ANNA	Unknown	AIH, PSC	

\*HCV can be associated with almost every autoantibody but usually at lower levels. AIH, autoimmune hepatitis; ANA, antinuclear antibody; HBV, hepatitis B virus; HCV, hepatitis C virus; HDV, hepatitis D virus; LC-1, liver-cytosol type 1; LKM, liver-kidney microsome; NASH, nonalcoholic steatohepatitis; p-ANCA, peripheral antineutrophil cytoplasmic antigen; p-ANNA, peripheral antineutrophil nuclear antibody; PBC, primary biliary cirrhosis; PSC, primary sclerosing cholangitis; SLA, soluble liver antigen; SMA, smooth muscle antibody.

Although several target nuclear antigens have been reported for ANA in AIH, such as centromeres, ribonucleoproteins, cyclin A, and histones,<sup>14–16</sup> the most frequent pattern is homogeneous and the reactants are presumed to be nucleosome or histones. In the diagnostic work-up of AIH, ANA reflects AIH-1. However, the molecular characterization of target nuclear antigen specificity does not as yet provide any important additional information that increases diagnostic precision. Moreover, ANA patterns or titers do not correspond to different AIH phenotypes or predict the natural history of the disease.

#### SMA

Serum SMA react with proteins of the cytoskeleton, particularly with filamentous (F) actin, and perhaps with others as well—monomeric globular (G) actin, myosin, troponin, and tropomyosin.<sup>17</sup> Their clinical significance depends on their titer and antigenic specificity. The detection of SMA is routinely based on IIF and preparations of rodent gastric mucosa, but composite blocks of stomach, liver, and kidney are recommended. In 1976, Bottazzo et al described three immunomorphological patterns of IIF using SMA-positive sera; these were SMAv (staining of vessels), SMAvg (staining of vessels and renal glomeruli), and SMAvgt (staining of renal tubular structures in addition to vessels and glomeruli).<sup>18</sup> Like ANAs, SMAs have not been considered hitherto as highly specific for AIH because of their presence in other diseases, celiac disease, and viral diseases (chronic hepatitis C, infectious mononucleosis).<sup>19</sup> However, when detected by IIF at titers of more than 1:80, with an SMAvgt pattern of staining, and in an appropriate clinical context, they are quite sensitive for AIH-1, being present in some 80% of cases.<sup>10</sup> Overall, SMA positivity or titers do not correlate with any major clinical or prognostic features of patients with AIH-1 and it has not yet been demonstrated that SMA has pathogenic effects in AIH. However, the SMAvgt pattern by IIF (specifying antibodies against F-actin) is the most specific for a diagnosis of AIH-1,<sup>20</sup> more often found in younger patients with severe disease, and their loss under treatment correlates with improved laboratory test results but does not predict treatment outcome.<sup>21</sup> A new F-actin enzyme-linked immunosorbent assay (ELISA) has been proposed as a useful diagnostic tool with similar specificity but superior sensitivity for the diagnosis of AIH, compared with standard SMA-IIF detection. Because of its simplicity and operator independence, the F-actin ELISA may become a preferred screening technique for detection of these antibodies in patients with suspected AIH.

#### ANTI-SLA/LP

Anti-SLA and anti-LP were independently described in 1987<sup>22</sup> and in 1983,<sup>23</sup> respectively, and were

considered different reactivities until Wies and colleagues demonstrated their identity<sup>24</sup> and showed that the specific target was the UGA suppressor tRNA-associated protein.<sup>24</sup> Anti-SLA/LP, which remains the “shorthand” term for the reactant, is measurable by ELISA with positivity in up to 30% of patients with AIH-1.<sup>25</sup> Anti-SLA/LP is a valuable and specific diagnostic marker for AIH-1 but can also be detected in sera from patients with AIH-2 and PSC by means of more sensitive test, a radioligand assay.<sup>26</sup> Finally, we note that anti-SLA/LP is associated with features of more severe disease in AIH.<sup>26–28</sup>

#### ANTI-LKM

Serum autoantibodies against LKM proteins were first detected by IIF by Rizzetto et al in 1973.<sup>29</sup> LKM immunoreactivities are heterogeneous (see later) and associated with several immune-mediated liver diseases, including AIH-2,<sup>30</sup> viral hepatitis C and hepatitis D,<sup>31,32</sup> drug-induced hepatitis,<sup>33</sup> and hepatitis in AIRE deficiency. Subsequent studies have led to these autoantibodies being subclassified as LKM-1, LKM-2, and LKM-3, mainly according to the disease setting in which they occur. The specific reactants for antibodies to LKM-1 and LKM-3 are the cytochrome P450 isoform 2D6 (CYP2D6)<sup>34</sup> and the uridine diphosphate glucuronosyltransferases, respectively.<sup>35</sup> Serum autoantibody to LKM-1 is the main serological marker of AIH-2 and recognizes a reactant that is highly enriched in proximal renal tubule and hepatocellular cytoplasm. LKM autoantibodies have been extensively studied not only as markers of AIH-2 but also to make differential diagnoses from other hepatic diseases, to gain insight into the immunological mechanisms involved in AIH, and to assess disease outcome. A pathogenic role of anti-LKM-1 is still debated despite the development of close mouse models of AIH-2 based on immunization with human CYP2D6 or adenoviruses transgenic for human CYP2D.<sup>34,36</sup>

#### ANTI-LC1

Autoantibodies to LC1 are detected by IIF in the serum of some 50% of patients with AIH-2 and much less frequently in those with AIH-1 or chronic hepatitis C.<sup>10,37</sup> However, detection of anti-LC1 by means IIF is limited by the frequent presence of anti-LKM1 in the same serum; thus, anti-LC1 is best detected by means of immunoblotting or counterimmunoelectrophoresis.<sup>35,38</sup> However, they are the only detectable markers in some 10% of cases of AIH-2 and, even more interestingly, correlate with AIH severity and progression.<sup>38,39</sup> The specific target of anti-LC1 has been identified as formiminotransferase cyclodeaminase, an enzyme involved in folate metabolism that is mainly expressed in the liver.<sup>39</sup>

**OTHERS AUTOANTIBODIES IN AIH**

There are several other autoimmune reactivities including p-ANCA and antiasialoglycoprotein receptor that may be useful to extend the diagnosis of AIH in patients without the usual classic autoantibodies, but testing for these is seldom called for in clinical practice. Antibodies to the asialoglycoprotein receptor are detectable in up to 90% of all patients with AIH-1, often coexisting with other autoantibodies, but these lack specificity for the diagnosis of AIH-1.<sup>40</sup> However, as with anti-LC1, high titers of antiasialoglycoprotein receptor are associated with more florid inflammatory disease activity and may be useful to monitor treatment responses.<sup>41</sup> p-ANCAs are detected by IIF at high titer and in up to 90% of patients with AIH-1 but also occur to a lesser degree in patients with PSC, PBC, or chronic viral hepatitis.<sup>42</sup> The pathogenic role (if any) of these autoantibodies in AIH is not clear. Their routine determination is not recommended, but at least assays for ANCA are readily available.

**PRIMARY BILIARY CIRRHOSIS**

PBC is a slowly progressive autoimmune disease of the liver that primarily affects women.<sup>43</sup> It is histopathologically characterized by portal inflammation and immune-mediated destruction of the intrahepatic bile ducts, the loss of which leads to decreased bile excretion and the retention of toxic substances, particularly bile acids, within the liver, causing additional hepatic damage. Progressive fibrosis and cirrhosis eventually cause liver failure (Fig. 1). Currently up to 60% of newly diagnosed patients are asymptomatic at the time of diagnosis,<sup>44</sup> being discovered by abnormal serum enzyme levels in liver function tests done for other purposes. Several clinical and experimental findings strongly imply an autoimmune pathogenesis for PBC, which is a model of autoimmune conditions because of its female

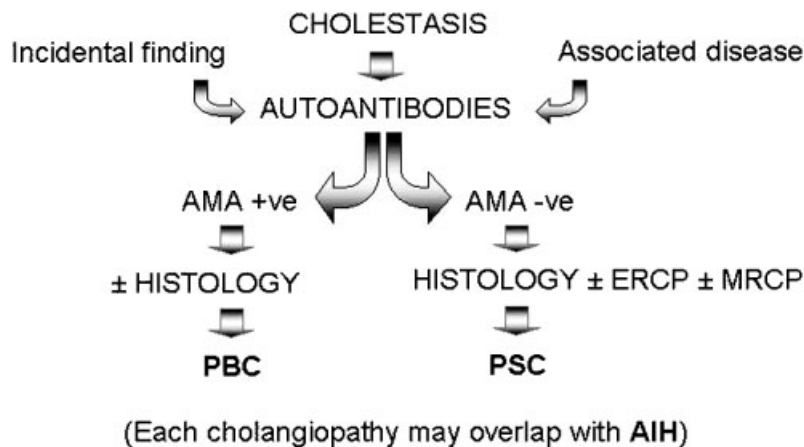
predominance, genetic predisposition, and the fact that most cases show the presence of disease-specific autoantibodies. However PBC loses a little of its gloss as a model autoimmune disease because the diagnostically characteristic antimitochondrial reactivity still has no defined role in pathogenesis.<sup>45,46</sup>

**PBC Diagnostic Criteria**

The diagnosis of PBC is based on the presence of two out of three internationally accepted criteria: increased enzymes indicating cholestasis (alkaline phosphatase) for more than 6 months; detectable serum AMA, titer greater than 1:40; and a compatible or diagnostic liver histology<sup>43</sup> (Fig. 2). The proposal of making a “definite” diagnosis only when all these of criteria are met may be too narrow because, for example, patients seronegative for AMA (but often positive for ANA) have a natural history similar to that of their AMA-positive counterparts.<sup>47</sup> The value of histological assessments is still a question of debate, but we believe that liver biopsy specimens are important for determining the stage of the disease at presentation and during follow-up.<sup>48</sup>

**Serum AMA: The Hallmark of PBC**

AMAs are considered the diagnostic hallmark of PBC as they are detected in up to 95% of affected individuals.<sup>49</sup> IIF is still the most widely used screening assay for AMA, although immunoblotting has an overall sensitivity of more than 90% and a specificity of 98%,<sup>50</sup> and use of cloned mitochondrial antigens (see later) containing the major autoepitopes in an ELISA format can identify AMA in the sera of patients previously defined as AMA negative.<sup>50,51</sup> In addition, we have generated and validated a bead assay for AMA and thereby found that 20% of rigorously defined AMA-negative patients have antibodies to one or



**Figure 2** Diagnostic flow chart for autoimmune cholangiopathies. PBC, primary biliary cirrhosis; PSC, primary sclerosing cholangitis; AIH, autoimmune hepatitis; AMA, antimitochondrial antibodies; ERCP, endoscopic retrograde cholangiopancreatography; MRCP, magnetic resonance cholangiopancreatography.

more mitochondrial autoantigens.<sup>52</sup> However, although the presence of AMA is one of the three diagnostic criteria in clinical practice, they are not clinically useful during follow-up of patients as several studies demonstrate that titers and patterns do not correlate with disease stage or outcome.<sup>47,53–55</sup> AMAs recognize the highly conserved regions of 2-oxo-acid dehydrogenase enzymes (OADC), particularly the dihydrolipoamide acetyltransferase (E2 component) of the pyruvate dehydrogenase complex (PDC). Serum AMAs react selectively against members of the 2-OADC family; these include PDC-E2, the E2 subunit of branched chain 2-oxo-acid dehydrogenase complex (BCOADC-E2), the E2 subunit of the oxoglutarate dehydrogenase complex (OGDC-E2), the dihydrolipoamide dehydrogenase (E3)-binding protein (E3BP), and the E1 $\alpha$  subunit of the pyruvate dehydrogenase complex (PDC-E1 $\alpha$ ) (Table 3).<sup>56</sup> Although AMAs are found in more than 90% of patients with PBC, their specific pathogenic role has not been defined.<sup>57</sup> AMAs are often detectable for several years before the onset of overt clinical disease.<sup>58</sup>

### ANA in PBC: A Prognostic Marker?

Antibodies to nuclear antigens are found in ~40% of patients with PBC and more often in those without AMA.<sup>59,60</sup> Over the past few years, various nuclear structures have been identified as specific targets of ANA in PBC.<sup>1</sup> The two most frequent IIF patterns are the “nuclear rim,” which depends on autoantibody recognition of gp210 and nucleoporin p62, proteins localized within the nuclear pore complex (NPC), and the “multiple nuclear dots” pattern, wherein the structures recognized are the Sp100 and promyelocytic leukemia proteins. The nuclear rim and nuclear dot patterns

are highly specific for the disease<sup>61</sup> (Table 3). Although less specific, anticentromere autoantibodies (ACAs) are found in ~10% of sera of patients with PBC.<sup>62</sup> PBC-specific ANAs have been found more frequently in patients with advanced disease in several cross-sectional studies<sup>59–64</sup> and, even more interestingly, the presence of anti-NPC is associated with accelerated progression toward advanced disease and, eventually, death.<sup>65,66</sup> These findings have been confirmed from Japan,<sup>67,68</sup> including data on a prognostic utility for ACA in PBC. These data have obvious implications for the clinical management of PBC given that the only accepted index for estimating survival has been obtained and validated in patients with advanced PBC and hence is of limited use in early disease. For these reasons, anti-NPC and ACA testing are important for identifying asymptomatic patients with a likely unfavorable disease course and warranting early therapy and overcoming some of the major limitations of currently available prognostic indicators such as the Mayo score.<sup>69</sup> However, once PBC has progressed to the advanced histological stages and abnormal levels of serum bilirubin have been reached, anti-NPC determinations do not seem to offer any additional advantage over other prognostic models.<sup>66</sup>

### Autoimmune Cholangitis

The term “autoimmune cholangitis” was first introduced to describe a PBC-like disease seropositive for ANA and later an AMA-negative PBC possibly with serum ANA or SMA, or both.<sup>70</sup> However, the term became broadened to cover (1) serum ANA and/or SMA positivity and/or hypergammaglobulinemia; (2) serum AMA negativity by IIF; (3) biochemical and/or histological features of cholestatic and hepatocellular injury; and (4) the exclusion of chronic viral, metabolic, or toxic liver disease.<sup>71</sup> This definition could include PBC with non-typical presentations, small duct PSC, idiopathic adulthood ductopenia, and transitional stages of the classic diseases. It is worth noting that although AMA and, particularly, the PBC-specific anti-M2 may not be detected by IIF, they may be demonstrable by other assays such as ELISA or immunoblotting using purified bovine or porcine heart mitochondria or recombinant mitochondrial antigens. The present opinion is that cases of autoimmune cholangitis represent a subset of PBC and should be managed accordingly.

**Table 3 Mitochondrial and Nuclear Autoantigens in Primary Biliary Cirrhosis**

Mitochondrial Antigens	
E2 subunits of 2-OADC	PDC-E2* OGDC-E2* BCOADC-E2*
Pyruvate dehydrogenase complex	E3BP* PDC E1 $\alpha$ *
Nuclear Antigens	
Nuclear pore complex	gp210* nucleoporin 62*
Multiple nuclear dots	Sp100 PML
Centromeres	CENP A, B, and C

\*Specific molecules detectable by immunoblot or enzyme-linked immunosorbent assay, other than indirect immunofluorescence. BCOADC, branched-chain 2-oxo-acid dehydrogenase complex; E3BP, dihydrolipoamide dehydrogenase (E3)-binding protein; 2-OADC, 2-oxo-acid dehydrogenase complex; OGDC, oxoglutarate dehydrogenase complex; PDC, pyruvate dehydrogenase complex.

### PRIMARY SCLEROSING CHOLANGITIS

PSC is a rare but important cause of chronic liver disease and is characterized by chronic inflammation and obliterative fibrosis of the intra- and/or extrahepatic biliary tree, which leads to bile stasis, hepatic fibrosis, and, ultimately, cirrhosis, end-stage liver disease, and the need for liver transplantation<sup>72,73</sup> (Fig. 1). Its natural

history is further complicated by the predisposition to cholangiocarcinoma and other malignancies.<sup>74</sup>

The etiopathogenesis of PSC is unknown, although there is evidence that immune-mediated mechanisms play some role.<sup>75,76</sup> This is indicated by its association with ulcerative colitis (UC) in the majority of patients,<sup>77,78</sup> the presence of serum autoantibodies, and defined human leukocyte antigen susceptibility alleles.<sup>79</sup> It has been debated whether PSC is an atypical autoimmune disease or an immune-mediated inflammatory disease.<sup>80,81</sup> It has been considered an “autoimmune disease with atypical features” because the autoimmune diseases concept fails to explain several important differences between PSC and classical autoimmune diseases. For example, there is the predominance of affected males, the absence of disease-specific autoantibodies, and the poor response to immunosuppressive medications. Interestingly, there are reports, mostly from Japan, of PSC-like biliary strictures associated with autoimmune pancreatitis,<sup>82,83</sup> sharing the major features of the latter, and a raised level in serum of immunoglobulin G4 (IgG4) and IgG4-bearing plasma cells in the lesions; as with patients with autoimmune pancreatitis, these patients are highly responsive to corticosteroids.

### PSC Diagnostic Criteria

PSC is characteristically accompanied by a cholestatic biochemical pattern and the results of liver function tests remain normal until the later stages (Fig. 2). Although their diagnostic applicability has not been studied in detail, it seems that detectable autoantibodies are not sensitive or specific enough to be of much use in the diagnosis of PSC.<sup>84</sup> Up to 80% of patients have atypical perinuclear ANCA (p-ANCA) in their serum, but such ANCA can also be found in patients with AIH or inflammatory bowel diseases without PSC. Imaging techniques (endoscopic retrograde cholangiopancreatography [ERCP] or magnetic resonance cholangiopancreatography [MRCP]) that demonstrate strictured and dilated tracts within intrahepatic or extrahepatic bile ducts are more useful. In the case of “small duct” PSC (typically characterized by the absence of ERCP or MRCP alterations), or PSC-AIH overlap syndrome, liver histology is crucial in establishing the diagnosis. The wider availability of invasive and noninvasive cholangiography has led to a perceptible increase in the rate of diagnosis of PSC in children.<sup>85</sup>

### ANCA

Various autoantibodies can be simultaneously present in patients with PSC, but there is growing evidence that only ANCAs are diagnostically relevant. There are two well-established IIF patterns of ANCA: diffuse cytoplasmic fluorescence accentuated between the nuclear

lobes (c-ANCA) or homogeneous fluorescence of the perinuclear cytoplasm (p-ANCA). ANCAs recognize different cytoplasmic constituents of neutrophil granulocytes and are valuable diagnostic and prognostic markers in systemic vasculitides, particularly Wegener's granulomatosis and related conditions.<sup>86,87</sup>

Reported frequencies of p-ANCA in PSC range from 33%<sup>88</sup> to 88%.<sup>89</sup> Classical p-ANCAs are clearly different from the so-called atypical p-ANCAs, which are almost exclusively found in patients with inflammatory bowel disease, PSC, or AIH.<sup>42,90,91</sup> The perinuclear immunofluorescence produced by atypical p-ANCA actually represents rim-like staining of the nuclear periphery<sup>92</sup> so that atypical p-ANCAs react with the nuclear envelope rather than with cytoplasmic antigens, a reversion to the older notion of “granulocyte-specific ANA,” whereas the recently introduced and more accurate term is “peripheral antineutrophil nuclear antibodies (p-ANNA)”<sup>93</sup>. Unlike that in systemic vasculitides, the pathogenetic role of ANCA in PSC is not clear. Immunoblotting has shown that the antigens recognized by atypical p-ANCA/p-ANNA are probably located in the neutrophil nucleus and may be represented by the 50-kDa myeloid-specific nuclear envelope protein.<sup>94</sup>

The utility of p-ANCA and p-ANNA in the clinical management of patients with PSC is still doubtful. Serum titers of antineutrophil antibodies do not correlate with disease activity, extent, or duration. Furthermore, ANCAs do not identify clinical subgroups of PSC as defined by the occurrence of dominant strictures or bacterial cholangitis or the coexistence of UC. A few studies have found a correlation between serum endpoint titers of antineutrophil antibodies and clinical indices in PSC, such as ANCA being associated with decreased serum albumin and increased serum alkaline phosphatase levels, so suggesting a more severe disease course.<sup>95</sup>

### Other Autoantibodies in PSC

The multiple nonspecific autoantibodies observed in PSC are probably a consequence of chronic inflammation and an immunogenetic bias toward vigorous immune responses. ANAs of ill-defined pattern can be detected in a substantial portion (53%) of PSC patients and SMAs in 13% to 20%, whereas AMAs are never present. Over 60% of PSC patients have anticardiolipin antibodies, and concentrations seem to correlate positively with histological changes and disease severity.<sup>96</sup> Recent evidence points to biliary epithelial cells being a target of autoantibodies: in one unconfirmed study, 63% of patients had antibodies to biliary epithelial cells, which induced the expression and production of CD44 and IL-6.<sup>97</sup> CD44 is an adhesion molecule that interacts with hyaluronic acid and is involved in a wide variety of physiological and pathological processes.<sup>98</sup>



Because anti-CD44 is reported to reduce experimental arthritis,<sup>99</sup> CD44 inhibition may be therapeutic in PSC. Current studies are attempting to confirm these speculative theories.

## OVERLAP SYNDROMES

The term "overlap syndrome" is used by hepatologists to describe variant diseases in which the biochemical and histological characteristics of AIH are associated with either PBC or PSC. One estimate is that in 18% of patients with one ALD there are coexisting features of a second ALD.<sup>100</sup> These overlap syndromes usually arise with both hepatocellular and cholangiocellular dysfunction and, when left untreated, progress toward liver cirrhosis and failure. More specifically, the AIH-PBC overlap syndrome is found in 10% of adults with AIH or PBC, and the AIH-PSC overlap syndromes is found in 6% to 8% of children, adolescents, or young adults with either AIH or PSC.<sup>100</sup> In addition to overlap syndromes, there are rare instances of apparent full transition from PBC to AIH, AIH to PBC, or AIH to PSC. In some instances of overlap syndrome, the coexistence is evident at initial presentation, or one of the overlap partners precedes the other; in the latter case PBC usually precedes AIH. In any event, more data are needed on the clinical characteristics and outcomes. The diagnosis and clinical management of overlap syndromes should be based on that required for each of the individual diseases: for example, UDCA is used for chronic cholestasis, immunosuppressants for AIH, and liver transplantation is indicated for end-stage disease.

## Autoantibodies in Overlap Syndromes

### AIH-PBC OVERLAP SYNDROME

The biochemical features of patients with the AIH-PBC overlap syndrome include high serum levels of transaminases plus markers of cholestasis plus increased levels of immunoglobulins M and G. Histologically, features of both diseases are evident, interface hepatitis and bile duct destruction. Serologically, there is positivity for SMA and AMA. However, the presence of ANA in the serum of a patient with AIH-PBC overlap syndrome is "tricky": ANAs are found in ~40% of patients with PBC and/or patients with AMA,<sup>59,60</sup> but these are usually "PBC-associated ANAs" (anti-nuclear pore complex, anti-sp100, or ACA) and are not at all indicative of AIH-associated ANA. In practice, reliable criteria for a diagnosis of AIH-PBC overlap syndrome are signs of hepatocellular and cholangiocellular injury with combined biochemical and histological features of AIH and PBC. The autoantibody profile may help to identify which is the more dominant member of overlap, which is usually PBC rather than AIH.

### AIH-PSC OVERLAP SYNDROME

The diagnosis of AIH-PSC overlap syndrome is likewise based on clinical and histological criteria, together with radioimaging data. A literature review published some years ago revealed a histology-based overlap between AIH and PSC in 6% of patients with AIH.<sup>101</sup> Kaya et al devised a scoring system for the diagnosis of AIH-PSC overlap syndrome,<sup>102</sup> but it is possibly biased by patients' age and the range of autoantibodies considered, and a call for more and better validated data was made.<sup>103</sup> An observed overlap of AIH in up to one third of children with PSC is of interest; such children usually have high levels of gamma globulins, interface hepatitis on liver biopsy, and an autoantibody profile as seen in AIH-1, prompting the term "autoimmune sclerosing cholangitis" (ASC) to describe this pediatric AIH-PSC overlap syndrome. These patients with ASC commonly suffer from UC and are often ANCA positive,<sup>104</sup> but patients with AIH alone also occasionally develop UC and express an "atypical" ANCA positivity.

## FUTURE DIRECTIONS

Specific serology has proved to be a mainstay of diagnostic testing for AIH and PBC, but a disease-relevant reactant has yet been identified in PSC. The goal of identifying more accurate and disease-specific and sensitive serum markers for each of the ALDs and the overlap syndromes justifies continuing effort. Success in the near future will require better molecular characterization of the present autoantigenic reactants and better standardization among laboratories. Commercially provided assays are readily available for the various serum autoantibodies, but stringent quality assurance testing is needed to ensure that laboratories obtain high qualitative standards. Furthermore, new technological advances are now allowing the development of increasingly automated detection methods associated with more rapid, accurate, and reliable autoantibody assays.<sup>105</sup> This will not only decrease the likelihood of human error in biological testing and allow better standardization but also reduce the time and cost involved in performing the individual assays.

Serologists should remain on the alert for new serologic markers in ALD that may have not only better sensitivity and specificity for diagnosis but also greater relevance for pathogenesis than the traditional markers in use at present. With the ultimate goal of predicting and possibly preventing autoimmunity, it will be important to assess the predictive role of ALD-specific autoantibodies, and the possibility of high-throughput investigation of multiple autoantigen reactivities will allow screening of healthy populations for autoimmune potential. However, although population screening for PBC-associated autoantibodies might be cost effective, this is less evident for AIH-associated autoantibodies.

Finally, autoantibodies not only may predict the development of a specific ALD when found in healthy subjects but also may predict its clinical manifestations, severity, and rate of progression.

**ABBREVIATIONS**

ACA	anticentromere autoantibody
AIH	autoimmune hepatitis
ALD	autoimmune liver disease
AMA	antimitochondrial antibody
ANA	antinuclear antibody
ANCA	antineutrophil cytoplasmic antigen
ASC	autoimmune sclerosing cholangitis
BCOADC	branched-chain 2-oxo-acid dehydrogenase complex
CYPs	cytochromes
ELISA	enzyme-linked immunosorbent assay
ERCP	endoscopic retrograde cholangiopancreatography
IgG4	immunoglobulin G4
IIF	indirect immunofluorescence
LKM	liver-kidney microsome
MRCP	magnetic resonance cholangiopancreatography
NPC	nuclear pore complex
OADC	2-oxo acid dehydrogenase enzymes complex
OGDC	oxoglutarate dehydrogenase complex
p-ANNA	peripheral antineutrophil nuclear antibody
PBC	primary biliary cirrhosis
PDC	pyruvate dehydrogenase complex
PSC	primary sclerosing cholangitis
SLA/LP	soluble liver antigen/liver pancreas antigen
SMA	smooth muscle antibody
UC	ulcerative colitis

**REFERENCES**

1. Invernizzi P, Selmi C, Ranftler C, Podda M, Wiesierska-Gadek J. Antinuclear antibodies in primary biliary cirrhosis. *Semin Liver Dis* 2005;25:298-310
2. Beuers U, Rust C. Overlap syndromes. *Semin Liver Dis* 2005;25:311-320
3. Cowling DC, Mackay IR, Taft LI. Lupoid hepatitis. *Lancet* 1956;271:1323-1326
4. Krawitt EL. Autoimmune hepatitis. *N Engl J Med* 2006;354:54-66
5. Homborg JC, Abuaf N, Bernard O, et al. Chronic active hepatitis associated with antiliver/kidney microsome antibody type 1: a second type of "autoimmune" hepatitis. *Hepatology* 1987;7:1333-1339
6. Alvarez F, Berg PA, Bianchi FB, et al. International Autoimmune Hepatitis Group Report: review of criteria for

- diagnosis of autoimmune hepatitis. *J Hepatol* 1999;31:929-938
7. Johnson PJ, McFarlane IG. Meeting report: International Autoimmune Hepatitis Group. *Hepatology* 1993;18:998-1005
8. Burgart LJ, Batts KP, Ludwig J, Nikias GA, Czaja AJ. Recent-onset autoimmune hepatitis: biopsy findings and clinical correlations. *Am J Surg Pathol* 1995;19:699-708
9. Vergani D, Alvarez F, Bianchi FB, et al. Liver autoimmune serology: a consensus statement from the committee for autoimmune serology of the International Autoimmune Hepatitis Group. *J Hepatol* 2004;41:677-683
10. Strassburg CP, Manns MP. Autoantibodies and autoantigens in autoimmune hepatitis. *Semin Liver Dis* 2002;22:339-352
11. Hueber AJ, Boxberger F, Ganslmayer M, Hahn EG. Antiphospholipid syndrome in combination with autoimmune hepatitis. *Eur J Gastroenterol Hepatol* 2005;17:241-243
12. Muratori P, Muratori L, Guidi M, et al. Anti-Saccharomyces cerevisiae antibodies (ASCA) and autoimmune liver diseases. *Clin Exp Immunol* 2003;132:473-476
13. Lyons R, Narain S, Nichols C, Satoh M, Reeves WH. Effective use of autoantibody tests in the diagnosis of systemic autoimmune disease. *Ann NY Acad Sci* 2005;1050:217-228
14. Strassburg CP, Alex B, Zindy F, et al. Identification of cyclin A as a molecular target of antinuclear antibodies (ANA) in hepatic and non-hepatic autoimmune diseases. *J Hepatol* 1996;25:859-866
15. Strassburg CP, Manns MP. Antinuclear antibody (ANA) patterns in hepatic and extrahepatic autoimmune disease. *J Hepatol* 1999;31:751
16. Czaja AJ, Nishioka M, Morshed SA, Hachiya T. Patterns of nuclear immunofluorescence and reactivities to recombinant nuclear antigens in autoimmune hepatitis. *Gastroenterology* 1994;107:200-207
17. Czaja AJ, Cassani F, Cataleta M, Valentini P, Bianchi FB. Frequency and significance of antibodies to actin in type 1 autoimmune hepatitis. *Hepatology* 1996;24:1068-1073
18. Bottazzo GF, Florin-Christensen A, Fairfax A, et al. Classification of smooth muscle autoantibodies detected by immunofluorescence. *J Clin Pathol* 1976;29:403-410
19. Gatselis NK, Georgiadou SP, Koukoulis GK, et al. Clinical significance of organ- and non-organ-specific autoantibodies on the response to anti-viral treatment of patients with chronic hepatitis C. *Aliment Pharmacol Ther* 2006;24:1563-1573
20. Muratori P, Muratori L, Agostinelli D, et al. Smooth muscle antibodies and type 1 autoimmune hepatitis. *Autoimmunity* 2002;35:497-500
21. Czaja AJ. Behavior and significance of autoantibodies in type 1 autoimmune hepatitis. *J Hepatol* 1999;30:394-401
22. Manns M, Gerken G, Kyriatsoulis A, Staritz M, Meyer zum Buschenfelde KH. Characterisation of a new subgroup of autoimmune chronic active hepatitis by autoantibodies against a soluble liver antigen. *Lancet* 1987;1:292-294
23. Teufel M, Niessen KH, Berg PA. Chronic active hepatitis in childhood with detection of liver-pancreas-specific autoantibodies. *Eur J Pediatr* 1983;140:30-33
24. Wies I, Brunner S, Henninger J, et al. Identification of target antigen for SLA/LP autoantibodies in autoimmune hepatitis. *Lancet* 2000;355:1510-1515

25. Herkel J, Heidrich B, Nieraad N, et al. Fine specificity of autoantibodies to soluble liver antigen and liver/pancreas. *Hepatology* 2002;35:403-408
26. Ma Y, Okamoto M, Thomas MG, et al. Antibodies to conformational epitopes of soluble liver antigen define a severe form of autoimmune liver disease. *Hepatology* 2002;35:658-664
27. Baeres M, Herkel J, Czaja AJ, et al. Establishment of standardised SLA/LP immunoassays: specificity for autoimmune hepatitis, worldwide occurrence, and clinical characteristics. *Gut* 2002;51:259-264
28. Czaja AJ, Donaldson PT, Lohse AW. Antibodies to soluble liver antigen/liver pancreas and HLA risk factors for type 1 autoimmune hepatitis. *Am J Gastroenterol* 2002;97:413-419
29. Rizzetto M, Swana G, Doniach D. Microsomal antibodies in active chronic hepatitis and other disorders. *Clin Exp Immunol* 1973;15:331-344
30. Muratori L, Lenzi M, Ma Y, et al. Heterogeneity of liver/kidney microsomal antibody type 1 in autoimmune hepatitis and hepatitis C virus related liver disease. *Gut* 1995;37:406-412
31. Yamamoto AM, Cresteil D, Homberg JC, Alvarez F. Characterization of anti-liver-kidney microsome antibody (anti-LKM1) from hepatitis C virus-positive and -negative sera. *Gastroenterology* 1993;104:1762-1767
32. Yamamoto AM, Johanet C, Duclos-Vallee JC, et al. A new approach to cytochrome CYP2D6 antibody detection in autoimmune hepatitis type-2 (AIH-2) and chronic hepatitis C virus (HCV) infection: a sensitive and quantitative radioligand assay. *Clin Exp Immunol* 1997;108:396-400
33. Homberg JC, Abuaf N, Helmy-Khalil S, et al. Drug-induced hepatitis associated with anticytoplasmic organelle autoantibodies. *Hepatology* 1985;5:722-727
34. Manns MP, Griffin KJ, Sullivan KF, Johnson EF. LKM-1 autoantibodies recognize a short linear sequence in P450IID6, a cytochrome P-450 monooxygenase. *J Clin Invest* 1991;88:1370-1378
35. Manns MP, Vogel A. Autoimmune hepatitis, from mechanisms to therapy. *Hepatology* 2006;43(suppl 1):S132-S144
36. Lapierre P, Djilali-Saiah I, Vitozzi S, Alvarez F. A murine model of type 2 autoimmune hepatitis: Xenoinmunization with human antigens. *Hepatology* 2004;39:1066-1074
37. Lenzi M, Manotti P, Muratori L, et al. Liver cytosolic 1 antigen-antibody system in type 2 autoimmune hepatitis and hepatitis C virus infection. *Gut* 1995;36:749-754
38. Muratori L, Cataleta M, Muratori P, Lenzi M, Bianchi FB. Liver/kidney microsomal antibody type 1 and liver cytosol antibody type 1 concentrations in type 2 autoimmune hepatitis. *Gut* 1998;42:721-726
39. Lapierre P, Hajoui O, Homberg JC, Alvarez F. Formiminotransferase cyclodeaminase is an organ-specific autoantigen recognized by sera of patients with autoimmune hepatitis. *Gastroenterology* 1999;116:643-649
40. Poralla T, Treichel U, Lohr H, Fleischer B. The asialoglycoprotein receptor as target structure in autoimmune liver diseases. *Semin Liver Dis* 1991;11:215-222
41. Treichel U, Gerken G, Rossol S, et al. Autoantibodies against the human asialoglycoprotein receptor: effects of therapy in autoimmune and virus-induced chronic active hepatitis. *J Hepatol* 1993;19:55-63
42. Targan SR, Landers C, Vidrich A, Czaja AJ. High-titer antineutrophil cytoplasmic antibodies in type-1 autoimmune hepatitis. *Gastroenterology* 1995;108:1159-1166
43. Kaplan MM, Gershwin ME. Primary biliary cirrhosis. *N Engl J Med* 2005;353:1261-1273
44. Prince MI, Chetwynd A, Craig WL, Metcalf JV, James OF. Asymptomatic primary biliary cirrhosis: clinical features, prognosis, and symptom progression in a large population based cohort. *Gut* 2004;53:865-870
45. Mackay IR, Whittingham S, Fida S, et al. The peculiar autoimmunity of primary biliary cirrhosis. *Immunol Rev* 2000;174:226-237
46. Gershwin ME, Ansari AA, Mackay IR, et al. Primary biliary cirrhosis: an orchestrated immune response against epithelial cells. *Immunol Rev* 2000;174:210-225
47. Invernizzi P, Crosignani A, Battezzati PM, et al. Comparison of the clinical features and clinical course of antimitochondrial antibody-positive and -negative primary biliary cirrhosis. *Hepatology* 1997;25:1090-1095
48. Heathcote EJ. Management of primary biliary cirrhosis. The American Association for the Study of Liver Diseases practice guidelines. *Hepatology* 2000;31:1005-1013
49. Van de Water J, Cooper A, Surh CD, et al. Detection of autoantibodies to recombinant mitochondrial proteins in patients with primary biliary cirrhosis. *N Engl J Med* 1989;320:1377-1380
50. Kitami N, Komada T, Ishii H, et al. Immunological study of anti-M2 in antimitochondrial antibody-negative primary biliary cirrhosis. *Intern Med* 1995;34:496-501
51. Mattalia A, Luttig B, Rosina F, et al. Persistence of autoantibodies against recombinant mitochondrial and nuclear pore proteins after orthotopic liver transplantation for primary biliary cirrhosis. *J Autoimmun* 1997;10:491-497
52. Oertelt S, Rieger R, Selmi C, et al. A sensitive bead assay for antimitochondrial antibodies: chipping away at AMA-negative primary biliary cirrhosis. *Hepatology* 2007;45:659-665
53. Joshi S, Cauch-Dudek K, Heathcote EJ, et al. Antimitochondrial antibody profiles: are they valid prognostic indicators in primary biliary cirrhosis? *Am J Gastroenterol* 2002;97:999-1002
54. Neuberger J, Bradwell AR. Anti-mitochondrial antibodies in primary biliary cirrhosis. *J Hepatol* 2002;37:712-716
55. Muratori L, Muratori P, Granito A, et al. The Western immunoblotting pattern of anti-mitochondrial antibodies is independent of the clinical expression of primary biliary cirrhosis. *Dig Liver Dis* 2005;37:108-112
56. Ishibashi H, Shimoda S, Gershwin ME. The immune response to mitochondrial autoantigens. *Semin Liver Dis* 2005;25:337-346
57. Nishio A, Keeffe EB, Gershwin ME. Immunopathogenesis of primary biliary cirrhosis. *Semin Liver Dis* 2002;22:291-302
58. Metcalf JV, Mitchison HC, Palmer JM, et al. Natural history of early primary biliary cirrhosis. *Lancet* 1996;348:1399-1402
59. Invernizzi P, Podda M, Battezzati PM, et al. Autoantibodies against nuclear pore complexes are associated with more active and severe liver disease in primary biliary cirrhosis. *J Hepatol* 2001;34:366-372
60. Muratori P, Muratori L, Ferrari R, et al. Characterization and clinical impact of antinuclear antibodies in primary biliary cirrhosis. *Am J Gastroenterol* 2003;98:431-437

61. Rigopoulou EI, Davies ET, Pares A, et al. Prevalence and clinical significance of isotype specific antinuclear antibodies in primary biliary cirrhosis. *Gut* 2005;54:528–532
62. Yang WH, Yu JH, Nakajima A, et al. Do antinuclear antibodies in primary biliary cirrhosis patients identify increased risk for liver failure? *Clin Gastroenterol Hepatol* 2004;2:1116–1122
63. Itoh S, Ichida T, Yoshida T, et al. Autoantibodies against a 210 kDa glycoprotein of the nuclear pore complex as a prognostic marker in patients with primary biliary cirrhosis. *J Gastroenterol Hepatol* 1998;13:257–265
64. Miyachi K, Hankins RW, Matsushima H, et al. Profile and clinical significance of anti-nuclear envelope antibodies found in patients with primary biliary cirrhosis: a multi-center study. *J Autoimmun* 2003;20:247–254
65. Invernizzi P, Wiesierska-Gadek J, Battezzati PM, et al. Prognostic value of autoantibodies against proteins of nuclear pore complexes (anti-NPCs) in early primary biliary cirrhosis (PBC). *J Hepatol* 2004;40:159–160. Abstract
66. Wiesierska-Gadek J, Penner E, Battezzati PM, et al. Correlation of initial autoantibody profile and clinical outcome in primary biliary cirrhosis. *Hepatology* 2006;43:1135–1144
67. Nakamura M, Shimizu-Yoshida Y, Takii Y, et al. Antibody titer to gp210-C terminal peptide as a clinical parameter for monitoring primary biliary cirrhosis. *J Hepatol* 2005;42:386–392
68. Nakamura M, Kondo H, Mori T, et al. Anti-gp210 and anti-centromere antibodies are different risk factors for the progression of primary biliary cirrhosis. *Hepatology* 2007;45:118–127
69. Dickson ER, Grambsch PM, Fleming TR, Fisher LD, Langworthy A. Prognosis in primary biliary cirrhosis: model for decision making. *Hepatology* 1989;10:1–7
70. Heathcote J. Autoimmune cholangitis. *Gut* 1997;40:440–442
71. Czaja AJ, Carpenter HA, Santrach PJ, Moore SB. Auto-immune cholangitis within the spectrum of autoimmune liver disease. *Hepatology* 2000;31:1231–1238
72. Lee YM, Kaplan MM. Primary sclerosing cholangitis. *N Engl J Med* 1995;332:924–933
73. Cullen SN, Chapman RW. The medical management of primary sclerosing cholangitis. *Semin Liver Dis* 2006;26:52–61
74. Lazaridis KN, Gores GJ. Primary sclerosing cholangitis and cholangiocarcinoma. *Semin Liver Dis* 2006;26:42–51
75. Worthington J, Cullen S, Chapman R. Immunopathogenesis of primary sclerosing cholangitis. *Clin Rev Allergy Immunol* 2005;28:93–103
76. Aoki CA, Bowlus CL, Gershwin ME. The immunobiology of primary sclerosing cholangitis. *Autoimmun Rev* 2005;4:137–143
77. Fausa O, Schrupf E, Elgjo K. Relationship of inflammatory bowel disease and primary sclerosing cholangitis. *Semin Liver Dis* 1991;11:31–39
78. Broome U, Bergquist A. Primary sclerosing cholangitis, inflammatory bowel disease, and colon cancer. *Semin Liver Dis* 2006;26:31–41
79. Wiencke K, Spurkland A, Schrupf E, Boberg KM. Primary sclerosing cholangitis is associated to an extended B8–DR3 haplotype including particular MICA and MICB alleles. *Hepatology* 2001;34:625–630
80. O'Mahony CA, Vierling JM. Etiopathogenesis of primary sclerosing cholangitis. *Semin Liver Dis* 2006;26:3–21
81. Mayer L. Redefining autoimmunity. *Gastroenterology* 2003;125:1574
82. Hamano H, Kawa S, Horiuchi A, et al. High serum IgG4 concentrations in patients with sclerosing pancreatitis. *N Engl J Med* 2001;344:732–738
83. Mendes FD, Jorgensen R, Keach J, et al. Elevated serum IgG4 concentration in patients with primary sclerosing cholangitis. *Am J Gastroenterol* 2006;101:2070–2075
84. Levy C, Lindor KD. Primary sclerosing cholangitis: epidemiology, natural history, and prognosis. *Semin Liver Dis* 2006;26:22–30
85. Mieli-Vergani G, Vergani D. Immunological liver diseases in children. *Semin Liver Dis* 1998;18:271–279
86. Gross WL, Ludemann G, Kiefer G, Lehmann H. Anti-cytoplasmic antibodies in Wegener's granulomatosis. *Lancet* 1986;1:806
87. Jenne DE, Tschopp J, Ludemann J, Utecht B, Gross WL. Wegener's autoantigen decoded. *Nature* 1990;346:520
88. Peen E, Sundqvist T, Skogh T. Leucocyte activation by anti-lactoferrin antibodies bound to vascular endothelium. *Clin Exp Immunol* 1996;103:403–407
89. Seibold F, Weber P, Klein R, Berg PA, Wiedmann KH. Clinical significance of antibodies against neutrophils in patients with inflammatory bowel disease and primary sclerosing cholangitis. *Gut* 1992;33:657–662
90. Duerr RH, Targan SR, Landers CJ, et al. Neutrophil cytoplasmic antibodies: a link between primary sclerosing cholangitis and ulcerative colitis. *Gastroenterology* 1991;100:1385–1391
91. Mulder AH, Broekroelofs J, Horst G, et al. Anti-neutrophil cytoplasmic antibodies (ANCA) in inflammatory bowel disease: characterization and clinical correlates. *Clin Exp Immunol* 1994;95:490–497
92. Terjung B, Herzog V, Worman HJ, et al. Atypical antineutrophil cytoplasmic antibodies with perinuclear fluorescence in chronic inflammatory bowel diseases and hepatobiliary disorders colocalize with nuclear lamina proteins. *Hepatology* 1998;28:332–340
93. Terjung B, Worman HJ. Anti-neutrophil antibodies in primary sclerosing cholangitis. *Best Pract Res Clin Gastroenterol* 2001;15:629–642
94. Terjung B, Spengler U, Sauerbruch T, Worman HJ. "Atypical p-ANCA" in IBD and hepatobiliary disorders react with a 50-kilodalton nuclear envelope protein of neutrophils and myeloid cell lines. *Gastroenterology* 2000;119:310–322
95. Roozendaal C, de Jong MA, van den Berg AP, et al. Clinical significance of anti-neutrophil cytoplasmic antibodies (ANCA) in autoimmune liver diseases. *J Hepatol* 2000;32:734–741
96. Angulo P, Peter JB, Gershwin ME, et al. Serum autoantibodies in patients with primary sclerosing cholangitis. *J Hepatol* 2000;32:182–187
97. Xu B, Broome U, Ericzon BG, Sumitran-Holgersson S. High frequency of autoantibodies in patients with primary sclerosing cholangitis that bind biliary epithelial cells and induce expression of CD44 and production of interleukin 6. *Gut* 2002;51:120–127
98. Nagano O, Saya H. Mechanism and biological significance of CD44 cleavage. *Cancer Sci* 2004;95:930–935
99. Naor D, Nedvetzki S. CD44 in rheumatoid arthritis. *Arthritis Res Ther* 2003;5:105–115
100. Beuers U. Hepatic overlap syndromes. *J Hepatol* 2005;42(suppl 1):S93–S99

101. Czaja AJ. The variant forms of autoimmune hepatitis. *Ann Intern Med* 1996;125:588–598
102. Kaya M, Angulo P, Lindor KD. Overlap of autoimmune hepatitis and primary sclerosing cholangitis: an evaluation of a modified scoring system. *J Hepatol* 2000;33:537–542
103. Chazouilleres O. Diagnosis of primary sclerosing cholangitis–autoimmune hepatitis overlap syndrome: to score or not to score? *J Hepatol* 2000;33:661–663
104. Gregorio GV, Portmann B, Karani J, et al. Autoimmune hepatitis/sclerosing cholangitis overlap syndrome in childhood: a 16-year prospective study. *Hepatology* 2001;33:544–553
105. Vignali DA. Multiplexed particle-based flow cytometric assays. *J Immunol Methods* 2000;243:243–255