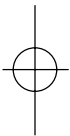


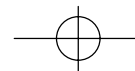
**CONTENTS**

PAGE

PAGE

INTRODUCTION	2	4. GLAUCOMA	19
MANAGEMENT OBJECTIVES	2	5. VISUAL PROBLEMS	19
SCOPE OF THE GUIDELINE	3	6. HEALTH PROMOTION AND HEALTH EDUCATION	22
1. MANAGEMENT OF PREVENTIVE EYE CONDITIONS/DISEASES	3	7. AWARENESS OF EARLY SIGNS AND FAMILY HISTORY OF CHRONIC DISEASES AND EYE DISEASES	22
1.1 Prevention of xerophthalmia	3	8. REFERRAL CRITERIA	22
1.2 Prevention of Bacterial and Viral Eye Infections	4		
1.3 Prevention of Trachoma	4		
1.4 Prevention of Ophthalmia Neonatorum	7		
1.5 Prevention of Occupational Hazards and Trauma	7		
1.6 Management of Chronic Diseases and other conditions	8		
2. EYE INFECTIONS/CONDITIONS	8		
2.1 Conjunctivitis	8		
– Bacterial	8		
– Viral	9		
– Allergic	10		
2.2 Ophthalmia Neonatorum	12		
2.3 Trachoma	13		
3. EYE INJURIES	16		
3.1 Chemical burns	16		
3.2 Superficial foreign body	17		
3.3 Blunt or penetrating injuries	17		
Use of eye pads	18		





## INTRODUCTION

The activities of primary eye care are clinical, preventive and promotive.

Preventive eye-care programmes teach health workers to diagnose and treat ocular or systemic diseases or conditions which will cause visual impairment and blindness if left untreated.

The principles of prevention of blindness and the treatment of common eye diseases **must** therefore be incorporated into primary health-care programmes.

Accidents cannot be eliminated in the home or working environment, but common sense and good occupational health practises will substantially reduce the occurrence of trauma-related ocular injuries. These can be managed at primary level, but referral criteria should be strictly adhered to.

## MANAGEMENT OBJECTIVES

- n To effectively manage eye conditions at primary level thereby limiting complications and potential blindness
- n To apply cost-effective interventions and accessibility to eye care for persons with eye disease/problem

### Primary target:

- Children and adults
- Health professionals
- Employers

### Secondary target:

- School personnel.

can and should be prevented. Some diseases, such as xerophthalmia and trachoma are classified as social diseases.

## 1.1 PREVENTION OF XEROPHTHALMIA

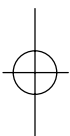Vitamin A supplementation should be given as prophylaxis to communities where vitamin A deficiency is common.

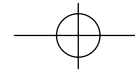
- n children under 12 months  
100 000 IU every 6 months
- n children over 12 months  
200 000 IU every 6 months

All children with:

- eye conditions secondary to vitamin A deficiency
- measles present or during the past 3 months
- kwashiorkor and/or marasmus

- n under 12 months  
100 000 IU immediately, to be repeated 24 hours later and after 6 weeks
- n over 12 months  
200 000 IU immediately, to be repeated 24 hours later





1.2 PREVENTION OF BACTERIAL AND VIRAL EYE INFECTIONS

**Personal hygiene**

- Wash face and cleanse eyes frequently.
- Use only own face-cloth and towel or hands to wash the face.
- Wash hands before touching eyes or near eyes or before applying ophthalmic ointments/drops.
- Never touch eyelids/eyes with the tip of an ophthalmic ointment or eye dropper.
- Do not share ophthalmic ointments/drops.
- Do not rub eyes.
- Never rinse contact lenses with tap water or any unpreserved solution.
- Never use urine to wash the eyes, especially not in newborn babies.

1.3 PREVENTION OF TRACHOMA

Health education is essential in terms of preventing infection, re-infection and complications (blindness), and curtailing/eliminating the spread of disease.

Transmission of the disease is by indirect or direct eye-to-eye contact and the common fly is the major vector in the infection - re-infection cycle.

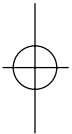
**Epidemiology**

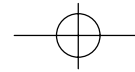
**Facial cleanliness**

- Daily hand and facial washing of mothers, children and

the whole community - this indicates the need for an

- |      |                                   |  |
|------|-----------------------------------|--|
| n    | Risk factors                      |  |
| i)   | Overcrowding                      | live in close physical contact, (share infected sleeping material) |
| ii)  | Facial uncleanliness              | children playing together; attracts flies that transmit infections |
| iii) | Insufficient sanitation:          | attracts flies   |
|      | - garbage disposal                |  |
|      | - unavailability of latrines      |  |
|      | - cattle near human dwellings     |  |
| iv)  | Certain habits:                   |  |
|      | - sharing handkerchiefs or towels | cross-infection  |
| v)   | Fly density                       |  |
| vi)  | Access to water                   | affects hygiene  |
| vii) | Hot and dry, dusty conditions     | flies multiply rapidly; dust provokes nasal and eye discharges     |





- adequate water-supply
- – Ideally, each person should have own individual face-cloth for facial washing. If towels are used then each person should use their own individual towels.
- – Removal of discharges from the face and nose will decrease the number of flies and break the infection - re-infection cycle. 'If you get rid of the discharge, you will get rid of the disease'
- – Trachoma, as an eye-to-eye infection, has disappeared almost entirely in certain countries because the standards of hygiene have been improved.

**Environmental hygiene**

- – Properly designed latrines (ventilated pit latrine) decrease the number of flies
- – Safe and adequate water-supplies
- – Removal or proper disposal of refuse
- – Animals kept at a safe distance from homes and not near water sources

**Educational Programme**

All education programmes should use:

6 Ds – Dry

- Dusty
- Dirty

- Dung
- Discharge
- Density (overcrowding)

5 Fs – Flies

- Faeces
- Fingers
- Families (contaminated clothing,

Ongoing programme of public awareness and health education encouraging community participation and involvement of

- all primary health-care facilities

- mother and child health clinics
- community radio

**1.4 PREVENTION OF OPHTHALMIA NEONATORUM**

Screen all pregnant women for sexually transmitted disease (STD) syndrome and treat.

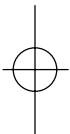Cleanse/wipe eyes of all newborn babies with a clean cloth, cotton wool or swab.

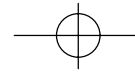
Routine administration of chloramphenicol 1% ophthalmic ointment into the eyes of every newborn baby.

**NO** harmful applications, such as urine, to be applied to the eyes of newborn babies.

**1.5 PREVENTION OF OCCUPATIONAL HAZARDS AND TRAUMA**

- Health education regarding the danger of agricultural and industrial practises
- Environments should be free from items posing eye hazards e.g. fireworks, paintball war games, etc.
- Pre-employment visual screening and regular follow-up for jobs requiring high visual efficiency
- Exit visual screening (on termination of employment)
- Availability and use of safety devices in vehicles e.g. seatbelts to be enforced
- First aid training and equipment in high-risk industries
- Improve safety features of machines and/or other equipment – ensure effective maintenance and regular inspections
- Effective packaging, handling and storage of chemical materials and other dangerous substances
- Supply of protective devices in high-risk industries is mandatory
- Training of labour force for high-risk jobs
- Adherence to minimum safety standards for workshops and factories with regard to lighting conditions and maximum working hours





#### OTHER CONDITIONS (refer appropriate guidelines)

- Diabetes
- Hypertension
- Malnutrition (nutrition deficiencies/under-nutrition)
- Acute glaucoma

## 2.1 CONJUNCTIVITIS

A broad term which is normally used for inflammatory conditions of the conjunctiva which may be infectious, caused by bacteria or viruses (pink eye), allergic causes or trauma.

#### Referral criteria within 48 hours

- Suspected corneal ulceration
- Pupil irregularity
- Diminished visual acuity
- Severe pain in the eye
- Trauma
- Suspected herpes keratitis

#### BACTERIAL CONJUNCTIVITIS (excluding conjunctivitis in the newborn)

##### **Clinical features**

- Stickiness of eyelids on awakening in the morning
- Discharge from one or both eyes
- Redness of conjunctival fornices
- Swollen lids

##### **Management of bacterial conjunctivitis**

- Apply chloramphenicol 1% ophthalmic ointment 6 hourly for 7 days.
- Paracetamol for pain relief
- Refer if no response after 5 days

#### VIRAL CONJUNCTIVITIS (PINK EYE)

##### **Clinical features**

- This is a highly contagious, viral infection which is spread by contact – hands, towels, face-cloths.
- It may start in one eye and spread to the other, or more commonly both eyes are infected.
- Itchy eyes.
- Sore eyes, feeling of grittiness (roughness) or burning which is often described by patients as being painful.
- Photophobia.
- Watery discharge.
- Conjunctivae reddened, swollen and may become haemorrhagic.
- If the discharge is yellow then a secondary bacterial infection has occurred.
- There may be swelling of the eyelids.
- The cornea, iris and pupil are completely normal.
- Normal visual acuity.
- **If unilateral, refer.**

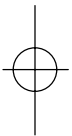
##### **Management of viral eye infection**

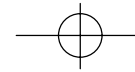
- Advise the patient to cleanse/rinse the eyes by washing with normal saline or clean warm water.
- Cold compresses
- Apply oxymetazoline 0.025% eye drops instilled in the eyes 6 hourly for 7 days.
- Advise on prevention measures.
- Paracetamol for pain relief.
- Off work or school for  $\pm$  4 days, according to health professional's discretion.

#### ALLERGIC CONJUNCTIVITIS

May be seasonal.

- Causes:** Allergy to pollens, grass, animal fur, etc.
- hayfever conjunctivitis.
  - Allergy to eye medication.





**Clinical features**

- Itching, lacrimation and photophobia.
- Conjunctiva may appear normal or slightly red.
- Severe cases – conjunctival swelling.

**Management of allergic conjunctivitis**

- Remove cause if known and possible.
- Cold compresses to relieve symptoms.
- Oxymetazoline 0.025% eye drops instilled in the eyes 6 hourly for 7 days for both children and adults.

*Chlorpheniramine oral for severe cases:*

- children 6 months – 1 year 1 mg twice daily
- children 1–5 years 1–2 mg three times daily
- children 5–12 years 2–4 mg 3–4 times daily
- children over 12 years and adults 4 mg 3–4 times daily

**Referral criteria**

- If severe or prolonged reaction
- All persons using contact lenses

**SIGNS AND SYMPTOMS                      MANAGEMENT**

- Itchy eyes
- Photophobia + normal or slightly red conjunctiva

- Itchy eyes
- Sore eyes
- Photophobia
- Watery eye/discharge
- Red conjunctiva
- Cornea, iris and pupil normal
- Normal visual acuity

- Sore eye
- Photophobia
- Red conjunctiva
- Cornea, iris and pupil normal
- Normal visual acuity
- + stickiness of eye lids on awakening in morning due to yellowish discharge from one or both eyes.

**2.2 OPHTHALMIA NEONATORUM**

Ophthalmia neonatorum is conjunctivitis in the newborn baby.

**n GONOCOCCAL CONJUNCTIVITIS**

*Bacterial conjunctivitis*

- Chloramphenicol 1% ophthalmic ointment 6 hourly for 7 days
- Paracetamol for pain relief
- Not better after 5 days - refer

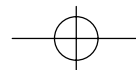
*Viral eye infection*

- Cold compresses
- Oxymetazoline 0.025% eye drops 6 hourly for 7 days
- Paracetamol for pain relief
- Prevention of spreading

*Allergic conjunctivitis*

- Remove cause if possible
- Cold compresses
- Oxymetazoline 0.025% eye drops 6 hourly for 7 days
- Chlorpheniramine, oral, for severe cases
- If prolonged - refer





**Cause:** Neisseria gonorrhoea.

**Clinical features:**

- Eyes are often sticky.
- Heavy purulent discharge, often associated with oedema of the eyelids.
- Onset within 36 to 48 hours after birth.
- Maternal history of purulent vaginal discharge at birth.

If this condition is not treated, it can become very severe and infect the cornea and lead to blindness.

**Management**

It is imperative that the pus is washed out as soon as possible. Ensure adequate irrigation or REFER for admission to ensure adequate irrigation, if heavy purulent discharge is present. Do not injure the cornea.

**Eye irrigation**

Use normal saline or **cooled** boiled water or sterile water. Initially, continuous irrigation will be needed. Baby should be hospitalised. If not possible, the mother must be taught how to irrigate the eyes or return to health facility/institution whenever irrigation is needed.

**Drug management**

After removal of pus:

- Chloramphenicol 1% ophthalmic ointment 2 - 4 hourly. (teach the mother to insert the ointment)

**Plus**

- Oral erythromycin 62.5 mg 6 hourly for 10 days.

**Referral criteria**

No response after 2 days of treatment, or evidence of corneal ulceration refer to doctor or ophthalmic nurse.

**NON-GONOCOCCAL INFECTIONS**

**Clinical features:**

- Slight watery or mildly purulent discharge.
- Mildly inflamed conjunctivae.
- Onset within 36 to 48 hours after birth.

**Management**

Cleanse eyes properly with distilled water and cotton/other swabs before drug treatment.

**Drug management**

After removal of pus:

- Chloramphenicol 1% ophthalmic ointment 2 - 4 hourly. (teach the mother to insert the ointment)

**Plus**

- Oral erythromycin 62.5 mg 6 hourly for 10 days.

**Referral criteria**

No response after 5 days of treatment.

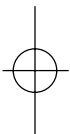
**2.3 TRACHOMA - a notifiable medical condition**

**Cause:** a strain of the bacteria Chlamydia trachomatous

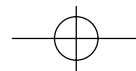
**Management**

The management of trachoma requires behavioural and environmental changes in addition to medical care. The four major factors are surgery for trichiasis, antibiotics for active infection, facial cleanliness and environmental hygiene (SAFE).

- S – Surgery for trichiasis
- A – Antibiotics for active infection
- F – Facial cleanliness
- E – Environmental improvement with water and sanitation, economic development and education.







If the first two signs are present, plus one of the following signs, trachoma can be diagnosed.

Ability to examine the conjunctiva under the upper eyelid is essential.

- A watery discharge may be the only symptom
- Follicles on the conjunctiva under the upper eyelid. Refer TF.

**and**

- Eyes feel gritty
- Photophobia is common
- Purulent discharge caused by a secondary infection.

#### **Chronic**

- Membranous thickening of the cornea (pannus)
- Erosion and/or inflammation of the cornea (keratitis)
- Scars on the conjunctiva under upper eyelid. Refer TS.
- Turning in of eyelashes (entropion). Refer TT.
- Turning in of whole eyelid.

If a patient has conjunctivitis in endemic areas, trachoma should be suspected.

#### **Trachoma Follicular (TF)**

There are 5 or more follicles in the upper tarsal conjunctiva. (For this grading system, follicles must be at least 0.5mm in diameter.)

#### **Trachomatous Inflammation, intense (T1)**

Pronounced inflammatory thickening of the tarsal conjunctiva will obscure half the normal deep tarsal vessels.

#### **Trachomatous Conjunctival Scarring (TS)**

The presence of scarring in the tarsal conjunctiva.

(These scars are easily visible as white lines, bands or sheets (fibrosis) in the tarsal conjunctiva.)

(Evidence of recent removal of in-turned eyelashes should also be graded as trichiasis.)

#### **Corneal Opacity (CO)**

Easily visible corneal opacity is present over the pupil. (This definition refers to corneal scarring which is so dense that at least part of the pupil margin is blurred when seen through the opacity).

#### **Treatment of infection**

- Tetracycline 1% ophthalmic ointment twice a day for 6 weeks. Treatment must be continued for six weeks even if eye seems to get better.
  - Doxycycline 100mg twice daily for 10 days in non-pregnant adults. (Not for young children or pregnant women).
- or**
- Erythromycin 500mg, 6 hourly for 10 days in pregnant women
  - Erythromycin 30 - 50mg/kg/day in divided doses, 6 hourly for 10 days for children.

#### **Assess the whole family for trachoma**

#### **Referral criteria**

Turned in eyelashes or eyelids (trichiasis) - Refer to an ophthalmic nurse or doctor.

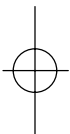
### **3.1. CHEMICAL BURNS**

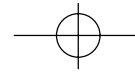
- This is an emergency, e.g. alkali, acid

#### **Clinical features**

- Pain
- Inability to open eyes
- Blurred vision
- Excessive teary and watery eye

#### **Management of chemical burns**





eyes at place of injury to avoid delay.

Irrigate or wash the eyes **immediately** and continuously with clean water for at least 20 minutes. In severe alkaline burn cases irrigation should be prolonged further. If needed apply topical anaesthetic - tetracaine 0.5% and repeat irrigation/washing out of eyes. NB: **Do not neutralise acid with alkaline and vice versa.**

- Evert upper eyelid and remove debris with cotton bud.
- Start with drug treatment:
  - atropine 1% ophthalmic drops stat - **maximum 2 drops**
  - chloramphenicol 1% ophthalmic ointment 6 hourly
  - analgesic
    - paracetamol – children:
      - 10 mg/kg/dose, 4 - 6 hourly
    - adults:
      - 500mg to 1g, 4 - 6 hourly
      - (maximum dose 4g/24 hours)

**All cases should be referred within 12 hours.**

### 3.2. SUPERFICIAL FOREIGN BODY (FB)

#### **Clinical features**

- Patient complains of something in the eye
- The foreign body can be seen
- Pain

#### **Management of FB in eye**

- Take proper history.
- Wash eye with clean water or normal saline.
- Remove FB if visible on sclera or conjunctiva with a cotton tipped stick/bud.
- Apply chloramphenicol ophthalmic ointment 3 to 4

only to remove the FB. If topical anaesthetic has been used, pad eye for 12 hours.

- A foreign body may be lodged under the upper eye lid. It is essential to inspect upper conjunctiva by everting the upper lid if possible.
- If foreign body cannot be easily removed: refer.

#### **Referral criteria**

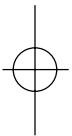
- Hyphaema
- Deformed pupil
- Scleral or corneal laceration
- Lid oedema
- Intraocular haemorrhage
- FB that cannot be easily removed
- Suspected retained intraocular FB. Be suspicious of a retained intraocular FB, e.g. a person was using a hammer, chisel, drill or nail gun.

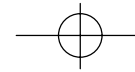
### 3.3 BLUNT OR PENETRATING INJURIES OF THE ORBIT, LID OR GLOBE

**Refer** immediately (within 12 hours) if there is:

- Acute change in vision in any eye to 6/12 or less on the Snellen chart
- Lid laceration
- Blood in the anterior chamber
- Unequal, irregular or sluggish (slow reaction) pupils
- Perforation of the cornea or sclera
- Disruption of the sclera
- Limitation of movement of the eyes
- Double vision (diplopia)
- Extreme swelling which prevents adequate examination
- Poor red reflex.

#### **Treatment at the clinic**





or

- If there is marked photophobia and the eye is congested
  - Apply chloramphenicol 1% ophthalmic ointment 6 hourly for 7 days
- Severe pain
  - Treat pain according to severity with available drugs.

Glaucoma is damage to the optic nerve caused by a level of intraocular pressure (often raised) which results in loss of vision.

Refer: Prevention of Blindness Programme for the management of glaucoma.

### ACUTE GLAUCOMA

#### **Clinical features:**

- The pupil is moderately dilated.
- Sudden onset of extremely severe, bursting pain and eye redness.
- A unilateral temporal headache after being exposed

#### **USE OF EYE PADS**

*The purpose of an eye pad is to hold the upper lid closed in circumstances where blinking would delay healing or cause discomfort e.g. corneal abrasions or ulcers.*

#### **It is not to keep light out of the eye!**

*Do not use with infections - especially conjunctivitis with a discharge, and in infants.*

*When indicated, the eye pad would be folded over to be thick enough to fill the area between the eye brow, nose and cheek and would be held in place with adhesive tape to achieve the purpose of holding the lid closed;*

- Coloured haloes around lights (bright rings)
- The eye feels hard, compared to the other eye, when measured with finger palpation (this is not an accurate test).
- Vomiting in severe cases.

#### **Emergency treatment before referral:**

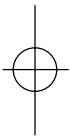
- Acetazolamide 250mg 6 hourly orally.
- Instill pilocarpine 1% eye drops every 15 minutes for four (4) doses
- Refer to ophthalmologist within 12 hours.

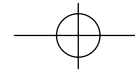
A well-trained and equipped optometrist or nurse can establish the urgency or non-urgency of many of these presentations.

Altered vision is always of concern, but **sudden visual loss** suggests serious disease.

#### **Clinical features**

- Frequent headaches and eye fatigue suggest
  - refractive errors
- Severe headaches with nausea suggest
  - acute glaucoma, migraine, brain pathology or systemic disease
- Gradually diminishing vision in one or both eyes suggest
  - cataract formation, glaucoma
- Cobwebs effect or black spots suggest retinal pathology or vitreous opacification
- Persistent dark areas in vision suggests retinal diseases or optic nerve problems
- Seeing coloured haloes (or bright rings) around lights suggests acute glaucoma.





- Determine visual acuity accurately in both eyes by Snellen chart
- If the vision is diminished (• 6/12) perform the following tests:

1. Pin hole test

- Make a hole in a piece of dark/black paper with a large pin, needle or point of a pen or pencil so that it is about 1mm wide
- Ask the patient to look through this hole at the Snellen chart
  - if vision improves, this suggests that the patient has a refractive error and needs glasses = refer to optometrist
  - if no improvement or vision becomes worse, this suggests cataract, glaucoma or retinal disease = refer to secondary or tertiary level.

2. Red reflex test

- The patient looks past the examiner's head focussing on a distant target
- With the ophthalmoscope at 0 (zero) the examiner keeps it close to his eye and then focuses the beam of light so that it falls on the pupillary area of the cornea
  - The examiner starts about 60cm away from the patient
  - In normal individuals, the examiner should be able to see a red or pink colour (reflex) through the pupil which comes from the retina

*Significance of an absent red reflex is always important*

- If there is a history of trauma or diabetes the absence of a red reflex is probably due to
  - retinal detachment
  - a vitreous or internal haemorrhage
  - mature cataracts

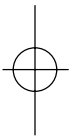
cataracts


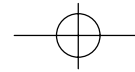
- absence of red reflex in mature cataracts
- In a patient above the age of 50 years with no history of trauma or previous eye disease, an absent red reflex is almost sure to be due to cataract formation (especially with decreased visual acuity).

**Absent red reflex - refer to secondary or tertiary level**

NB: Associated diabetes or hypertension should be adequately managed BEFORE referral, as surgery can only be considered with appropriately managed disease

- Encourage immunisation especially against measles.
- Healthy eating habits (especially Vitamin A). Refer: Nutrition policy.
- Anti-tobacco message and support system for quitters.
- Alcohol consumption control/anti-alcohol message.
- Safer sex practices (sexually transmitted disease (STD) prevention and management).
- Accident prevention.
- Use of eye pads (refer page 18)






- family history of
  - Diabetes
  - Glaucoma
  - Retinoblastoma
  - Strabismus
  - Retinitis Pigmentosa
  - Hypertension

**IMMEDIATE REFERRALS - within 12 hours**

- Pain or redness in **one eye only** or unilateral watery eye especially with visual and pupil abnormalities suggests serious disease, unless a treatable cause can be



- pain
- poor vision
- Sudden visual loss **in one or both eyes** for which an obvious treatable cause can not be found
- Trauma with any complication:
  - deep penetrating foreign bodies
  - hyphaema (blood in the anterior chamber)
  - poor vision
  - laceration of cornea or sclera
  - chemical burns, refer after emergency irrigation
- Recent proptosis of one or both eyes
- Squint - recent onset



**An 'only eye' patient, no matter what the complaint, must be given great understanding and priority**

**LESS URGENT REFERRALS**

vision

- Cataracts
- Chronic glaucoma
- Long-standing blindness – *first* visit to health facility
- Eyelashes rubbing on the cornea (trichiasis)
- Eyelids bent into the eye (entropion)
- Eyelids bent out too much (ectropion)
- Ptosis (drooping eyelid)
- Double vision except following recent injury
- Diabetic patients (once a year)
- All foreign bodies older than 36 hours and still causing pain and redness

**REFERRALS OF CHILDREN**

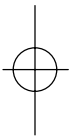
- Leucokoria (white reflex from the pupil):
  - often due to the presence of a cataract or retinoblastoma (tumour of the retina)
- Enlargement of the eye (buphthalmos / keratoglobus) due to:
  - congenital glaucoma
  - acquired glaucoma
- Hazy cornea (corneal oedema)
- Squint at **any** age if not previously investigated by ophthalmologist
- Newborn with conjunctivitis, after 2 days if no improvement with treatment (Refer: Ophthalmia Neonatorum)
- Diabetes - once a year.

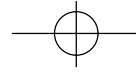
**ACKNOWLEDGEMENTS**

The Department of Health wishes to thank all the people who were involved in the development of the National Guideline on Management and Control of Eye Conditions at Primary Level.

*Special thanks to the following stakeholders:*

- Department of Health, national and provincial offices
- Bureau for the Prevention of Blindness
- Departments of Ophthalmology





- Ophthalmological Society of South Africa
- South African Optometric Association
- Pretoria Eye Institute
- St John's Eye Hospital

