



12 Lead ECGs: Ischemia, Injury, Infarction

This course has been awarded
four (4) contact hours.
This course expires on December 20, 2015.

Copyright © 2003 by RN.com.
All Rights Reserved. Reproduction and distribution
of these materials are prohibited without the
express written authorization of RN.com.

First Published: April 10, 2003
Revised: June 7, 2005
Revised: June 7, 2007
Revised: September 20, 2011

Acknowledgements

RN.com acknowledges the valuable contributions of...

...**Tanna R. Thomason, RN, MS, CCRN**, author of 12 Lead ECG Interpretation: Ischemia, Injury and Infarction. Tanna has over 20 years of experience as a clinician in the hospital setting. After completing her Master's Degree as a Clinical Nurse Specialist from San Diego State University in 1993, Tanna has functioned as a critical care Clinical Nurse Specialist for Sharp Memorial Hospital in San Diego, CA. In addition to her Clinical Nurse Specialist role, Tanna has been teaching nursing students since 1998 in an adjunct faculty position at Point Loma Nazarene University. In 2001, Tanna is President of Smart Med Ed, an educational consulting business. Tanna's publications center on research in caring for the acute myocardial infarction, congestive heart failure, and interventional cardiology patient populations. Tanna is a member of the American Association of Critical Care Nurses (AACN) and has served in various leadership roles for the San Diego Chapter of AACN. Other memberships include Sigma Theta Tau and the Cardiovascular Council of the American Heart Association.

...**Karen Siroky, MSN, RN**, for updating this course. Karen Siroky, MSN, RN-BC is the Clinical Education Director for RN.com. Karen has a BSN from University of Arizona and an MSN from San Diego State

Material Protected by Copyright

University. Karen's clinical experience includes ICU, transplant, quality services, nursing administration and education. She has worked with RN.com for more than 10 years and has authored a number of courses for RN.com.

Purpose and Objectives

The purpose of 12 Lead ECG Interpretation: Ischemia, Injury, and Infarction is to educate healthcare professionals on a systematic system of examining and interpreting 12 lead ECGs. The course also offers information about basic treatments in various situations and potential problems that may be encountered.

After successful completion of this continuing education course, participants will be able to:

1. Identify demographic data pertaining to the severity of coronary artery disease and occurrence of acute myocardial infarctions.
2. Correctly identify the following normal ECG components: isoelectric line, Q wave, R wave, and ST segment.
3. Describe the ECG characteristics of a normal 12 lead ECG.
4. Systematically assess and interpret a 12 lead ECG for abnormal patterns of ischemia, injury, and infarction.
5. Interpret ST elevation MI (STEMI or acute injury changes).
6. Describe potential treatment options for the patient experiencing acute myocardial damage.
7. Differentiate STEMI from non-STEMI and contrast the treatment priorities for each.

Disclaimer

RN.com strives to keep its content fair and unbiased. The author(s), planning committee, and reviewers have no conflicts of interest in relation to this course. There is no commercial support being used for this course. Participants are advised that the accredited status of RN.com does not imply endorsement by the provider or ANCC of any commercial products mentioned in this course.

There is no "off label" use of drugs or products discussed in this course.

You may find that both generic and trade names are used in courses produced by RN.com. The use of trade names does not indicate any preference of one trade named agent or company over another. Trade names are provided to enhance recognition of agents described in the course.

Note: All dosages given are for adults unless otherwise stated. The information on medications contained in this course is not meant to be prescriptive or all-encompassing. You are encouraged to consult with physicians and pharmacists about all medication issues for your patients.

Before Continuing This Course

If you are new at ECG rhythm interpretation, take RN.com's course "Telemetry Interpretation" before beginning this course.

This course will not teach basic ECG interpretation, bundle branch block, axis deviation, or chamber hypertrophies.

This self-learning module is designed for the nurse who has **already mastered basic ECG rhythm interpretation** and is ready to advance into the interpretation of the 12 lead ECG. This module will not teach basic ECG interpretation and dysrhythmias.

In this module, the emphasis will be on the identification and management of acute ischemia, injury, and infarction. The module teaches the bedside practitioner to examine the 12-lead ECG in a systematic format to determine acute or chronic changes. ST Elevation MI (STEMI) infarction patterns will be discussed for the patient experiencing acute injury to the inferior, anterior, and lateral surfaces of the heart. Non-ST elevation myocardial infarction (Non-STEMI) patterns and treatments will also be discussed.

After correctly identifying the 12-lead ECG abnormality, this module helps the nurse to determine nursing priorities in managing patients with specific types of infarctions. Treatment options per the American College of Cardiology (ACC) and American Heart Association (AHA) will be integrated throughout the sections.

Introduction

Accurate 12 lead electrocardiogram (ECG) interpretation is an essential diagnostic tool when caring for the patient with clinical symptoms of a suspected acute coronary syndrome (ACS) . If your patient is admitted with a diagnosis of unstable angina, chest pain, or rule-out myocardial infarction, the 12 Lead ECG is used as a focal point in treatment decision strategies.

- Would your patient benefit from a **thrombolytic** agent?
- Should your patient go directly to the **cardiac catheterization** lab for a percutaneous coronary intervention (i.e. angioplasty/stent)?
- Is **drug therapy** (i.e. anticoagulation, nitroglycerin) and medical management best for your patient?

You and the physician will collaborate in these types of critical decisions. To expedite appropriate treatment, all nurses working in the critical care setting, emergency department, urgent care, and cardiovascular cath lab areas must be able to detect patterns of acute ischemia, injury and infarction on the 12 lead ECG.

Angina, STEMI, NSTEMI

ACS is comprised of one of three conditions:

Unstable angina -

- Occurs without cause (for example, it wakes you up from sleep).
- Lasts longer than 15 - 20 minutes.
- Responds poorly to nitroglycerin.
- May occur along with a drop in blood pressure or significant shortness of breath (Medline, 2011).

NSTEMI - (Non ST Segment Elevation Myocardial Infarction.

- ST Segment Elevation does not occur.
- Coronary artery is only partially blocked.
- A smaller portion of cardiac tissue dies, since there is not complete artery blockage.

- Difficult to distinguish from unstable angina without measuring cardiac enzymes.

STEMI - (ST Elevation Myocardial Infarction).

- ST elevation does occur indicating complete blockage of the coronary artery.
- A larger amount of cardiac tissue dies.
- More severe than NSTEMI.
- Early intervention critical.

Regions of Myocardial Involvement

The nature and severity of an acute myocardial infarction (MI) may be related to the region of myocardial involvement. The three most common areas of the heart affected by an MI (STEMI or NSTEMI) are:

- Inferior
- Anterior
- Lateral

Knowledge of:

- ECG tracings common to each of these areas
- The coronary artery source of each area
- Clinical signs and symptoms, and
- Potential complications

Are all vital to subsequent patient care management.

Acute Myocardial Infusion Statistics

Each year, about 1.2 million people in the United States have an acute MI. AMI is the leading killer of both men and women in the United States.

Of the people who die from heart attacks, about half die within an hour of the first symptoms and before they reach a healthcare facility (National Heart, Lung and Blood Institute, 2011).

Prognosis is based on numerous variables including size and depth of MI, blood supply to residual non-infarcted myocardium (collateral circulation), age of patient, number of previous infarctions, and left ventricular function.

The average age at the time of the first MI is 50 years for men and 60 years for women. Early recognition and treatment is essential. It has been shown that early treatment results in reductions in mortality, infarct size, and improved left ventricular function. Reperfusion therapy beyond 12 hours from onset of acute symptoms has shown little benefit.

Test Yourself

Reperfusion therapy shows little benefit if started _____ hours after the onset of symptoms.

- A. 4- Incorrect! Reperfusion therapy shows little benefit if started 12 hours after the onset of symptoms.
- B. 6- Incorrect! Reperfusion therapy shows little benefit if started 12 hours after the onset of symptoms.
- C. **12- Correct!**
- D. 14- Incorrect! Reperfusion therapy shows little benefit if started 12 hours after the onset of symptoms.

Symptomatology

Chest discomfort or pain associated with MI is called angina pectoris. Unstable angina can occur at rest or with exercise. It may result from a sudden decrease in coronary blood flow caused by coronary thrombosis **OR** spasm **OR** from the inability to increase coronary blood flow sufficiently to meet myocardial oxygen demands (e.g. during exercise).

Acute myocardial infarction (MI) is actual necrosis of myocardial tissue as a result of relative or absolute lack of blood supply to the myocardium. Most acute MIs are caused by atherosclerosis (e.g. fat deposits, fibrosis, calcification, and/or platelet aggregation), which results in a progressive narrowing of the coronary artery, thrombus formation and ultimately the occlusion of blood flow. Occlusion can be caused also by coronary artery spasm. The site of the infarction is determined by the location of the arterial occlusion.

According to the World Health Organization (WHO) definition, the diagnosis of MI is based on the presence of at least two of the following three criteria:

- A clinical history of ischemic-type chest discomfort,
- Changes on serially obtained electrocardiographic tracings
- A rise and fall in serum cardiac marker labs.

The comprehensive assessment of the patient experiencing chest discomfort (or other questionable symptoms) centers around three assessment categories or “clues.” The first assessment “clue” is focused around the **characteristics of the chest discomfort** and the physical examination. The second assessment “clue” is **rapid and accurate interpretation of the 12 lead ECG**. The third assessment “clue” is the rise and fall of **cardiac marker labs** (more on this later in the module).

Although all three categories or “clues” are important, the 12 lead ECG is THE primary diagnostic study which sits at the CENTER of all decision making protocols.

Clues to Help Diagnose Chest Pain

The comprehensive assessment of the patient experiencing chest discomfort (or other questionable symptoms) centers around three assessment categories or “clues.” The first assessment “clue” is focused around the **characteristics of the chest discomfort** and the physical examination. The second assessment “clue” is **rapid and accurate interpretation of the 12 lead ECG**. The third assessment “clue” is the rise and fall of **cardiac marker labs** (more on this later in the module).

Although all three categories or “clues” are important, the 12 lead ECG is THE primary diagnostic study which sits at the CENTER of all decision making protocols.

- Clues
- Characteristics of the pain
- Interpretation of the 12 lead
- Cardiac Markers

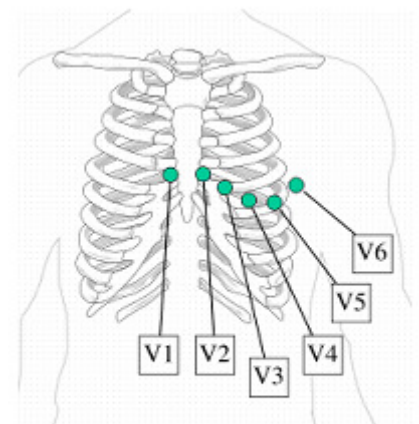
Format of the Printed 12 Lead ECG

The 12 Lead ECG has a standardized format. There are six Frontal Leads which are labeled or called Leads I, II, III, aVR, aVL, and aVF.

Leads I, II, and III represent a picture of the electrical conduction of the heart from view of the limb to the heart.

12 Lead Format			
I	aVR	V1	V4
II	aVL	V2	V5
III	aVF	V3	V6

The small “a” means “Augmented”. The augmented leads show the electrical conduction (augmented) from the heart to the right arm (aVR) from the heart to the left arm (aVL) and the heart to the right foot (aVF).



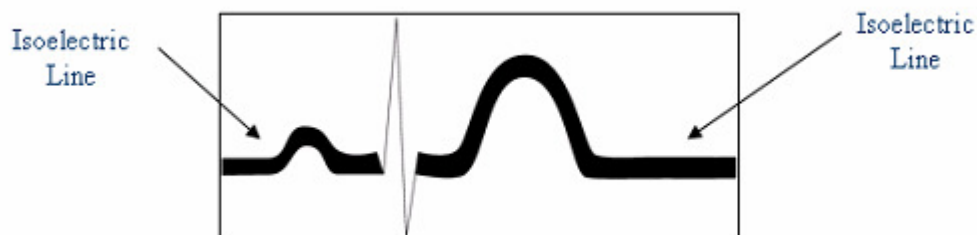Example of precordial lead placement.

There are six Precordial Leads (also called “Chest Leads” or “V leads”) named V1, V2, V3, V4, V5, and V6.

The “Isoelectric Line” – What Is It and Why Is It Important?

The isoelectric line is the baseline on the ECG recording. It is where electrical activity is “resting”.

The isoelectric line is an imaginary line on the ECG recording where your PR interval is recorded and where the ST segment normally sits. The isoelectric line is important because it is used as a normal reference point for evaluating ST – T wave abnormalities (more on this later)!

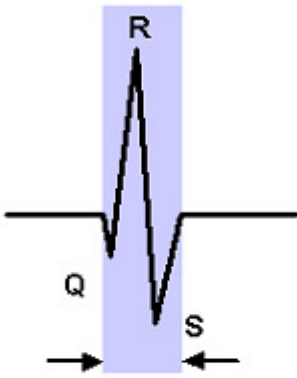


Review of Basic ECG Morphology

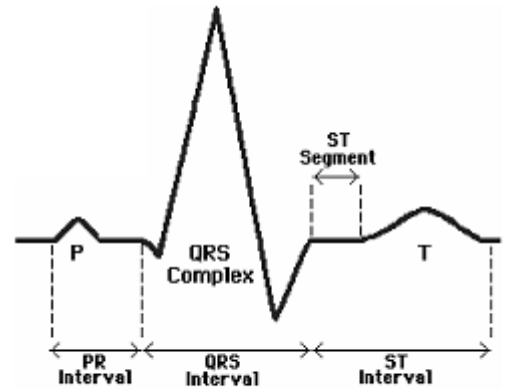
Atrial depolarization is represented by the "P" wave. The impulse travels from the sinoatrial (SA) node into the atrio-ventricular junction (AV node) and the Bundle of His. This conduction is reflected in the PR interval.

The PR interval sits on the isoelectric line (see below). Ventricular depolarization is represented by the QRS tracing.

The ST segment is a reflection of ventricular repolarization, which is followed by the T wave, which shows repolarization of the ventricles. Remember the ST segment should also sit on the isoelectric line.



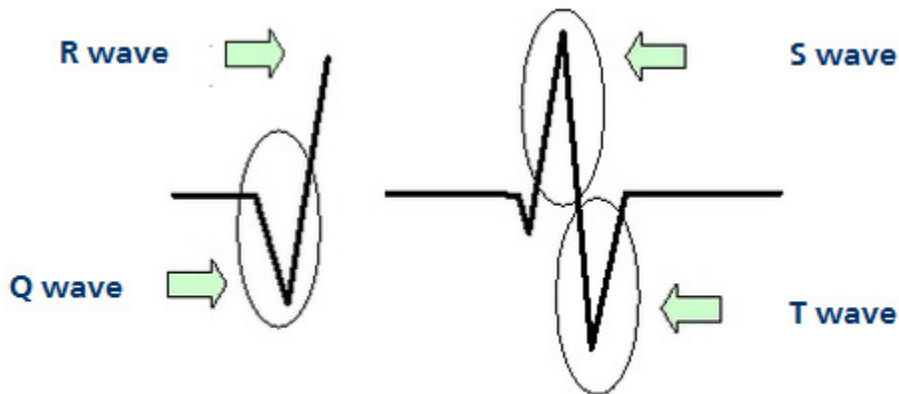
The QRS interval is measured from start of Q to end of S.



Used with permission from Smart Med Ed.

QRS Terminology

If you need a quick review of the basic ECG terminology, study the table below. It is very important that we "speak the same language" related to identification of Q waves, ST segments, and T waves.



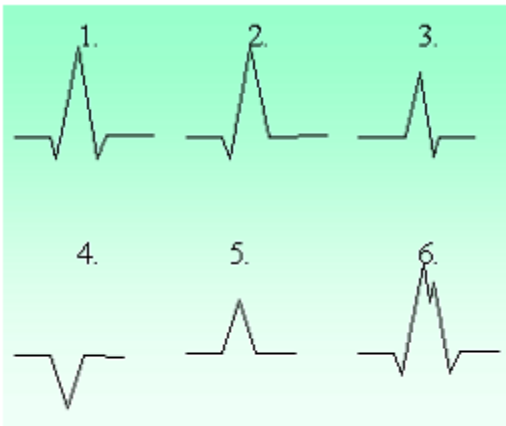
Used with permission from Smart Med Ed.

More Information

Q wave	First negative deflection after the PR interval
R wave	Any upright deflection
S wave	A negative deflection after the R wave
QS	All of the complex is negative
Qrs	"Lower case" letters when complexes are small (this is subjective, either is fine)
QRS	"Upper case" letters when complexes are large

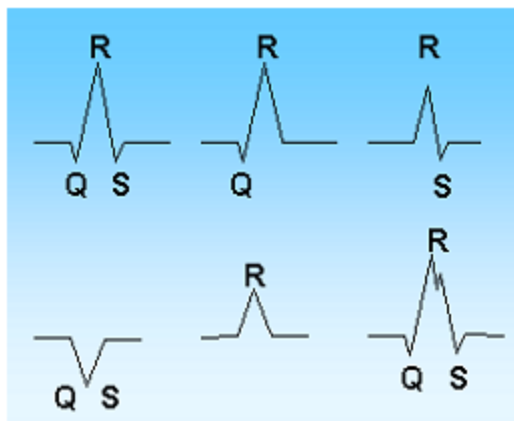
QRS Morphology Interpretation

Practice interpreting the following QRS morphologies



Used with permission from Smart Med Ed.

Answer:



1. QRS
2. qR
3. Rs
4. QS
5. R
6. QRS with "notched" appearance

Normal Q Waves

Normal Q waves are an indication of normal septal depolarization. After the atria depolarize, the septum depolarizes, followed by the right and left bundle branches. The leads which have the "best view" of the septum are leads I, aVL, V5, and V6. When the septum depolarizes, the ECG records this event with a small "Q wave."

These small or "baby" Qs are called "normal septal Q waves" and they have two important ECG

criteria:

- Normal septal Qs need to be \leq one small ECG box in width (.04 seconds wide)
- Normal septal Qs need to be \leq one-fourth the height of the R wave

For example, if the R wave is 6 boxes high and the preceding Q wave is one box deep, this would be $\leq 25\%$ the height of the R wave.

Normal septal Qs can be seen in any of the 12 leads, but are often best seen in Leads I, aVL, V5, and V6. Regardless of the lead they are found in, they must meet both of the ECG criteria below to be considered "normal."

Abnormal Q Waves

Normal Qs are skinny and not very deep.

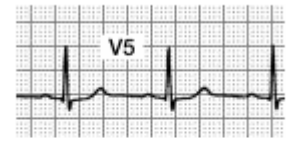Abnormal Q waves are an indication that the heart has been damaged and cannot conduct normally. Abnormal Q waves reflect that there has been a loss of electrical activity resulting from damaged myocardial tissue.

Abnormal Q waves are a permanent marker of damage and never go away. Abnormal Qs can be found in any of the 12 leads. Generally speaking, the larger the number of leads with abnormal Qs, the greater the amount of heart damage!

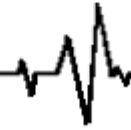An abnormal Q wave has the following criteria:

- $\geq .04$ seconds wide
- $\geq 25\%$ the height of the R wave
- Permanent (do not go away) on the ECG recording

Normal Q Wave ECG Criteria:

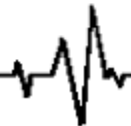

- Narrow: $\leq .04$ seconds wide
- Short: $\leq 25\%$ of the total height of the R wave



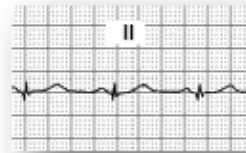
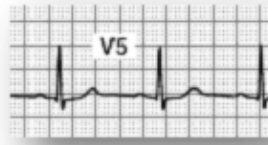
Abnormal Q Wave ECG Criteria:

- Wide: $\geq .04$ seconds wide
- Deep: $\geq 25\%$ of the total height of the R wave



Samples of Q Waves

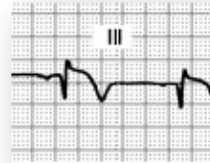
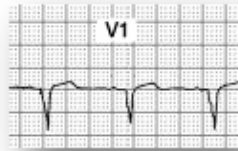Additional
Samples of
**Normal
Q Waves:**



Remember, small Q waves can be normal in lead

Samples of **Abnormal Q Waves:**

Abnormal QS
morphology
no R wave present

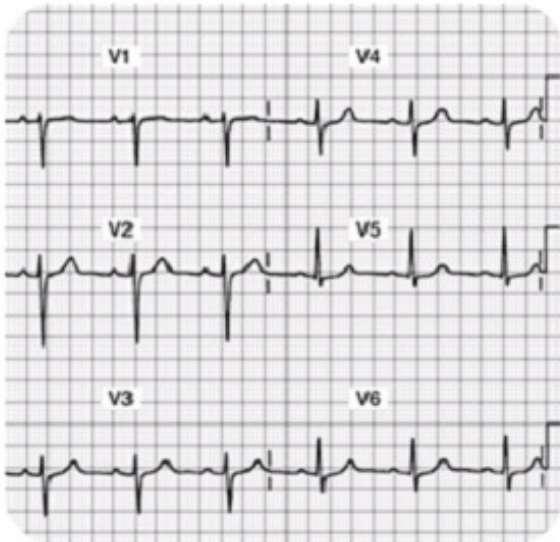


Note also the
ST segment
elevation

More Information:

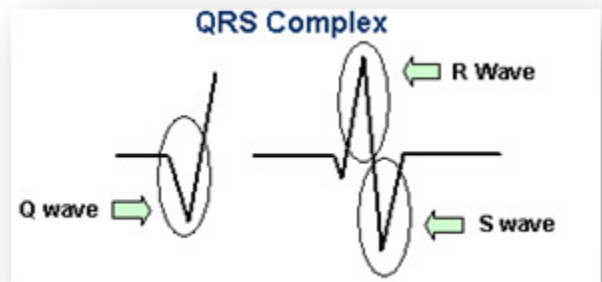
Abnormal Qs are wider and deeper than the normal "petite" Q wave. Abnormal Q waves tell the story that at some time in the past, this person has experienced heart damage and as a result, there is a loss of electrical conduction (due to old tissue damage). These Q waves are permanent and typically do not go away with time.

Normal R Waves



**Note the R wave progression
in leads V1-V4.**

There should be an R wave in each of the 12 leads except in lead aVR. Some R waves are very short (for example in V1 the r wave is "tiny," but it is present, so it counts!).



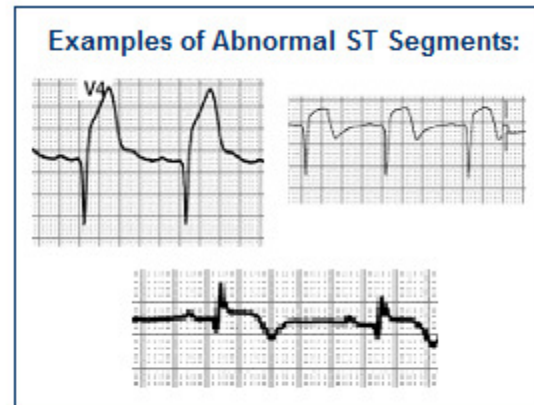
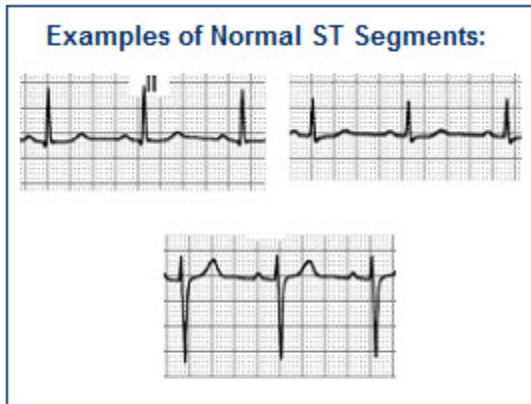
Normal R waves become progressively higher in amplitude from V1 through V4, then stabilize or gradually become smaller again through V6. Some people call this "Normal R Wave Progression."

Introduction to S-T Segments

Observe the ST segment and junction point (J-point) morphology. The J-point is located at the end of the QRS where the T wave begins.

- The ST segment should be isoelectric (i.e. neither negative, positive, nor biphasic).
- To be clinically significant the ST deviation from the isoelectric line should be greater than

(Exceptions: V1 and aVR have abnormal looking ST segments)



More information to follow about the significance of S-T segments

The Normal 12 lead ECG

Before you can interpret “abnormal,” you must be able to identify the “normal” 12 lead ECG. There are four basic items you will want to examine and assess for. The normal 12 lead ECG has specific characteristics you can look for using this process:

Step 1: Examine all 12 Leads closely with the exception of aVR.

- The aVR lead is not useful in the detection of ischemia, injury, and infarction. You now have permission to ignore the aVR lead for the remainder of this module.

Step 2: Go on a “Q wave search”

- **Q waves should be $\leq .04$ seconds wide and $\leq 25\%$ the height of the R wave.** These normal septal q waves are typically seen best in leads I, aVL, V5, and V6. Circle all Q waves which do not meet the above criteria.

Step 3: Go on an “R wave search”

- **11 out of the 12 leads should have an “R wave.” The only lead which does not have an R wave is aVR.** Some leads have tiny R waves... For example in V1, the R wave is very small, but if there is an upright deflection after the PR interval, we call it an R wave. Circle all leads which do not have an R wave, as this would be abnormal.

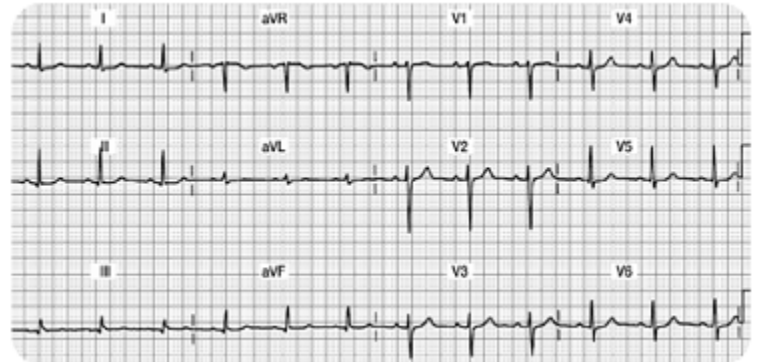
Step 4: Examine the ST segment... does it live on the isoelectric line?

- **With the exception of V1, all eleven leads should have the ST segment begin and end on the isoelectric baseline.** Mark any leads that have a ST segment that does not begin and end on the isoelectric line.

Step 5: Examine the T wave...

- T waves should be upright in all eleven leads except it might be biphasic in V1 (which is normal). Circle any T waves that are not upright.

This is an example of a normal 12 Lead



Go on a "Q wave search"

- Are the Q waves $\leq .04$ seconds wide and $\leq 25\%$ the height of the R wave? You might see small Q waves in Lead II, III, aVF, V5, and V6. These identified Q waves meet the "normal" criteria & simply record that the septum in the heart had normal depolarization.

Go on an "R wave search"

- 11 out of the 12 leads should have an "R wave." The only lead which does not have an R wave is aVR. Notice how V1 has a tiny R wave. Also, note how the R wave "grows" or gets taller as the ECG progresses from V1 through V6. This "growth spurt" or progressive height of the R wave is called, "normal R wave progression." If you find normal R wave progression, you can rest assured that this part of the myocardium is healthy and is conducting in a normal way.

Examine the ST segment... does it live on the isoelectric line?

- With the exception of V1 (which is sometimes biphasic), all eleven leads should have the ST segment begin and end on the isoelectric baseline. Note that it is normal in V2 and V3 for the ST segment to quickly transition into the T wave, thus making it a bit more difficult to critique.

Examine the T wave

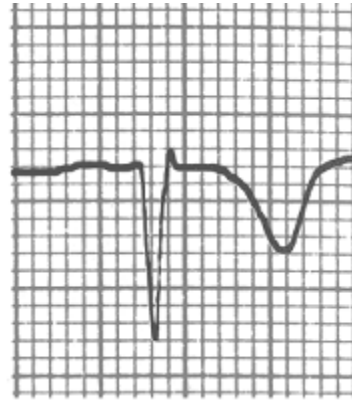
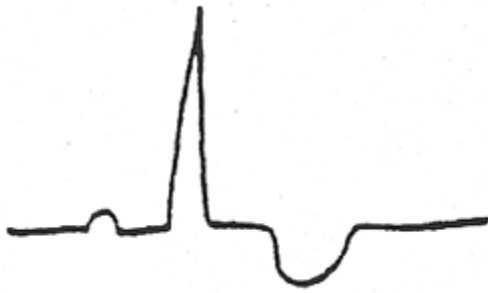
- The T waves should be upright in all eleven leads, with the exception of V1, which might be biphasic (also a normal finding).

Ischemia Injury and Infarction

Myocardial Ischemia

Ischemia is defined as a temporary or transient deprivation of myocardial oxygenation resulting in ST segment and/or T wave inversion on the ECG. The ST-T wave abnormalities typically return to the normal ST on the isoelectric line and upright T wave position when the myocardial oxygen supply meets the demand.

Ischemia: see example below of transient ST-T wave abnormalities with associated myocardial oxygen deprivation.



Ischemia, Injury, and Infarction

Scenario One:

Your patient is experiencing midsternal chest pressure; an eight (8) on a scale of 0-10. You obtain a 12 lead ECG. You note that several of the T waves are inverted on this ECG tracing. You ask the patient to remain supine; apply oxygen at 2 liters per nasal cannula, attach a cardiac monitor, and obtain IV access. Your nursing goals are to:

- Decrease oxygen demands
- Increase oxygen supply to the myocardium

The healthcare provider orders nitroglycerin (NTG) .0.4mg sublingual. NTG dilates coronary arteries and increases myocardial oxygen delivery.

The patient's blood pressure is 146/90, so you proceed with administering the nitroglycerin. A few minutes later, the patient's chest pain is gone and blood pressure is stable. **You obtain a second, follow-up 12 lead ECG. The T waves have returned to their upright, normal position.** This is an example of ischemia... not a MI, but clearly a warning sign. If the ischemia is not resolved, it can progress into an acute MI.

Test Yourself

Inverted T waves that have returned to their upright normal position after you have administered nitroglycerin 1.4mg x 3 indicate infarction.

- A. True
- B. False- Correct!**

Scenario Two:

Your patient has left your unit to undergo a diagnostic stress test on a treadmill. After increasing the speed and incline on the treadmill, the technician, nurse, and provider note new ST segment depression and T wave inversion on the 12 lead ECG recording. The treadmill is immediately stopped.

The patient rests and oxygen is applied. The abnormal ST-T waves return upright to the normal position.

This is obviously an abnormal treadmill stress and this person will likely need a coronary angiogram (cardiac catheterization) to determine the extent of coronary artery disease. This patient may ultimately need percutaneous coronary intervention (angioplasty or stent) or may need coronary artery bypass grafting surgery (CABG).

Test Yourself:

Your patient is having a stress test when you notice a new onset of ST segment depression and T wave inversion. You will:

- A. Continue with the treadmill.
- B. Stop the treadmill immediately, apply oxygen to the patient and have them rest.- Correct!**
- C. Continue with the treadmill if the patient is not complaining of any pain.
- D. Stop the treadmill and administer lidocaine.

What About Cardiac Markers

Common cardiac markers include CK, CK-MB, and Troponin I. These three lab tests will be elevated in the setting of acute myocardial tissue damage.

The previous scenarios are examples of transient or temporary myocardial oxygen deprivation resulting in abnormal ST –T waves on the ECG, called myocardial “ischemia.”

In these situations, the patient is not having a ST elevation myocardial infarction (STEMI). If the above patients were to have cardiac marker lab tests drawn (Troponin I and or CK-MB lab tests) during these episodes, the markers would **NOT** be elevated because actual myocardial cell damage has not occurred.

Test Yourself

Ischemic T wave inversions seen on the ECG may return to the “upright” (normal) position when the patient’s oxygen supply meets the oxygen demands.

- A. True- Correct!**
- B. False- Incorrect! T wave inversions may be transient (and may return upright) after oxygen demands are minimized and supply is optimized.

Ischemia is a Warning Sign

Ischemia is a WARNING SIGN and is typically accompanied with chest discomfort. Whenever you see new ST- T wave inversion in any lead, assess your patient for cardiac symptoms and always think about oxygen supply and demand. Follow standing protocols or specific MD orders, but always remember that you want to:

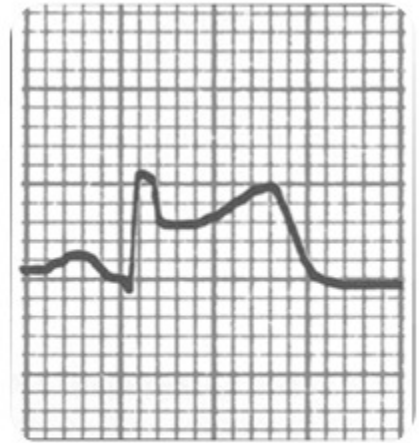
- Increase your patient’s oxygen supply
- Decrease myocardial oxygen demands
- Communicate findings to provider

Myocardial Injury

Acute myocardial injury is characterized by ST segment elevation due to acute damage of myocardial tissues. The formal name for this type of heart damage is called "ST Elevation Myocardial Infarction" or STEMI.

With myocardial injury, the greater the number of leads with ST elevation, the larger the infarct size. **With acute ST elevation, myocardial tissue destruction is occurring right before your very eyes!!**

Think about the principles of oxygen supply and demand.
How can you decrease demand and increase supply?



MONA

Immediate treatment typically includes morphine, oxygen, nitroglycerin and aspirin (MONA).

Morphine Sulfate: Morphine sulfate is the analgesic of choice for the management of chest pain associated with STEMI. Administer administered in 2 – 4 mg IV repeated at 5- to 15-minute intervals until pain is relieved. Assess B/P and respiratory rate closely.

Oxygen: Supplemental oxygen should be administered to patients with arterial oxygen desaturation (SaO₂ less than 90%) and is reasonable to administer supplemental oxygen to all patients with uncomplicated STEMI during the first 6 hours.

Nitroglycerin: Patients with ongoing ischemic discomfort should receive sublingual nitroglycerin (0.4 mg) every 5 minutes for a total of 3 doses, after which an assessment should be made about the need for intravenous nitroglycerin. Most physicians prefer nurses to begin treating chest pain with nitro. If unrelieved after 3 doses, most hospital units have protocols to progress to treating the pain with morphine sulfate (see above). (Always follow your organization protocol and physician orders)

Aspirin: Aspirin should be chewed by patients who have not taken aspirin before presenting with STEMI. The initial dose should be 162 mg which is more effective than the dose of 325 mg.

Remember
"MONA"

Morphine Sulfate
Oxygen
Nitroglycerin
Aspirin

More Information:

Warning... potential "drug-to-drug" interaction:

Before administering nitroglycerin, make sure your patient's blood pressure is above 90 systolic AND make sure your patient has NOT taken any erectile dysfunction medication within the last 24-48 hours. If you administer nitroglycerin to a patient who has taken an erectile dysfunction medication recently, the nitroglycerin may cause a dangerous refractory hypotension!

In addition to MONA

In addition to MONA, evidence based practice shows there is great benefit from adding a beta blocker medication ASAP. If not contraindicated (low b/p or heart rate), immediate beta-blocker therapy appears to reduce the magnitude of infarction and reduces life threatening ventricular tachyarrhythmias. Additional treatment includes continuous ECG monitoring, ST-segment monitoring (if available) and rest. Stay in close communication with your patient's MD.

The MD will consider the appropriateness of:

- Percutaneous coronary intervention (i.e. angioplasty/stent insertion) versus
- Systemic thrombolytic treatment versus
- Medical management (i.e. Heparin, nitroglycerin drip, beta blocker therapy).

Test Yourself:

Which of the following medication is shown to decrease the size of an infarction and reduce life-threatening tachy-arrhythmias?

- A. Statins
- B. Beta-blockers- Correct!**
- C. Aspirin

Review of Cardiac Markers

You will recall that cardiac markers peak and return to normal at different times.

Refer to the table below for a review:

Normal Lab Values for Common Cardiac Markers

Lab Test	Normal Values
Creatine Kinase (CK) Total Value	0 - 170 IU/L
CK/MB	0 - 6 mg/ml
CK Index or Ratio	0 - 1.5%
Troponin I	< 0.4 ng/ml Borderline: .4 - 2 ng/ml Elevated: > 2 ng/ml

*Lab values vary slightly from facility to facility.
Your facility's normal values may be somewhat different.*

More Information:

Marker	Times to Initial Elevation (Hours)	Peak Hours	Return to Normal Range (Days)	Comments
Creatine Kinase (CK) Normal 0 -170 ltr CK/MB Normal 0 -6	3 – 12	24	2 – 3	Elevated by non-cardiac etiologies (skeletal muscle injury)
CK/MB Ratio or Relative Index % MB Total CK value Normal 0- 1.5	3 – 12	24	2 – 3	
Troponin I Normal: <0.4 BL: 0.4-2.0 Elevated: >2	2 – 4	18 – 24	5 – 14	Not influenced by skeletal muscle trauma or renal failure
Myoglobin	1 - 2	4 – 8	1	Measured Q 1 Hr x 3 used in Urgent Care or ER setting

What is the Nurses Role

Acute ST elevation MI (STEMI) is very dangerous as this is when patients are most likely to develop sudden death [Ventricular Tachycardia (VT) and Ventricular Fibrillation (V Fib)].

As a healthcare professional, you should:

- Assess and stabilize your patient. Assess for characteristics of chest pain and hemodynamic response (B/P, pulse, cardiac rhythm). Decrease myocardial oxygen demands while increasing supply.
- Obtain the stat 12 lead ECG. Looks for new ST-T wave elevations reflecting acute injury.
- Evaluate cardiac maker labs (Troponin I, CK, CK-MB, Myoglobin). Cardiac markers will be elevated if the patient is having damage to the myocardial tissue.
- Stay in close communication with the provider.

Test Yourself:

Acute ST elevation required immediate attention.

A. True- Correct!

B. False- Incorrect! New ST elevation is a sign of new myocardial injury and requires immediate attention.

Infarction

Infarction simply means "old damage." Remember the deep and wide abnormal Q waves which develop when the heart muscle is damaged? Remember that these Q waves are permanent markers on the 12 lead. The reason why we see a deep and wide Q wave is because damaged/scarred myocardial tissue cannot conduct normally, resulting in an abnormal Q on the ECG.

In addition to abnormal Q waves, the patient may lose some or all of the voltage (or height) on the R wave. The small voltage R waves are also a result of dead tissue which cannot conduct the myocardial impulse.

Abnormal Q waves usually develop within 1-4 days of an acute STEMI. Generally speaking, the greater the number of leads with abnormal Q waves, the greater the amount of damage, however, the best way to assess cardiac function (and damaged areas) is with a two-dimensional echocardiogram (2 D-Echo).

Conclusions: Permanent deep ($\geq 25\%$ height of the R wave) and wide ($\geq .04$ seconds) Q waves seen in two or more leads is indicative of damage through the layers of the myocardium. Scarred tissue cannot conduct electrical impulses normally, thus the ECG records this abnormality with deep and wide Q waves.

Test Yourself:

Abnormal Q waves indicate temporary damage has occurred in the myocardium.

- A. True- Incorrect! Abnormal Q waves indicate permanent damage has occurred in the myocardium. They develop within a few days of new STEMI and will remain for the lifetime of a patient.
- B. False- Correct!

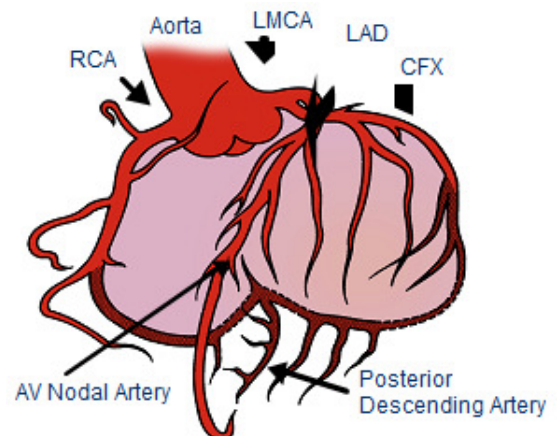
Coronary Artery Blood Supply

Normal coronary artery blood flows through three main coronary arteries. The **Right Coronary Artery** supplies blood and oxygen to the right atrium and right ventricle. The **Left Coronary Artery** has two major branches; they are called the **Left Anterior Descending (LAD)** and the **Left Circumflex (LCx)** coronary arteries. The LAD supplies blood and oxygen to the anterior portion of the left ventricle. The LCx supplies blood and oxygen to the lateral portion of the left ventricle.

Normal Coronary Artery Anatomy and Blood Flow

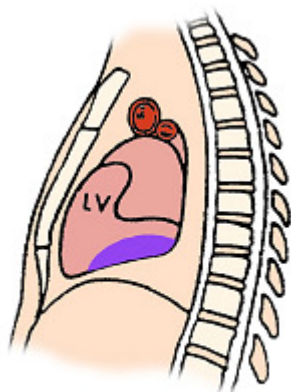
The Coronary Arteries and their Major Branches:

- Right Coronary Artery (RCA)
- Left Main Coronary Artery (LMCA)
- Left Anterior Descending (LAD) Coronary Artery
- Circumflex (CFX) Artery



Specific ST Elevation Myocardial Infarctions

This section will review three types of ST elevation myocardial infarctions (STEMIs). We will focus on the most common types of STEMI which include the acute inferior, anterior, and lateral infarcts.



Used with permission from Smart Med Ed.

Inferior Wall MI

The inferior surface (or “wall”) of the myocardium is located on the surface of the myocardium above the diaphragm.

Coronary Artery Source

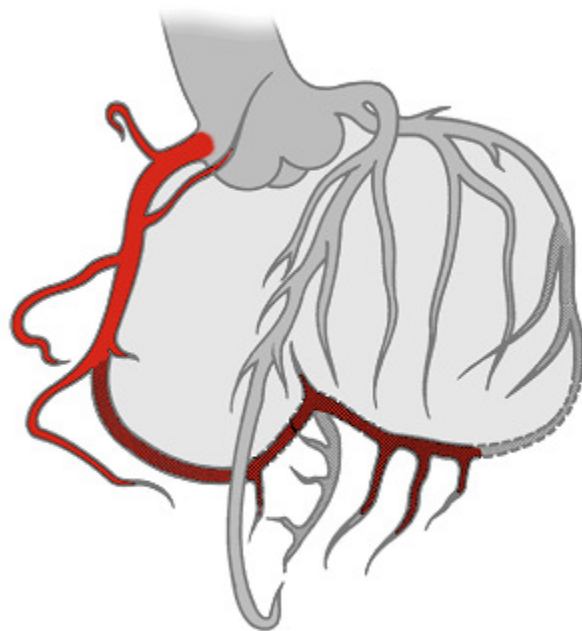
Acute inferior wall myocardial infarctions (IWMI) are classified as a STEMI and are generally the result of occlusion to the right coronary artery (RCA). Less frequently, they might be caused by disease in a dominant left circumflex artery. Inferior wall MIs are the most common type of infarct.

You need to know that the RCA supplies blood to several important structures including the AV node in 90% of the population, the Bundle of His, and the SA node in 55% of people. Therefore, when occlusion of the RCA, conduction defects may result producing AV blocks (example Mobitz I or third degree heart block). The AV blocks are usually ischemic, transient, and reversible, but can require pacemaker therapy.

Right Coronary Artery Blood Supply

The Right Coronary Artery supplies blood to:

- Right atrium.
- Right ventricle.
- SA Node in 55% of population.
- AV Node in 90% of population.
- Posterior wall in 90% of population (described as “right dominant”).
- RCA feeds into the PDA (posterior descending artery) in 85% of population. PDA feeds inferior wall.



Used with permission from Smart Med Ed.

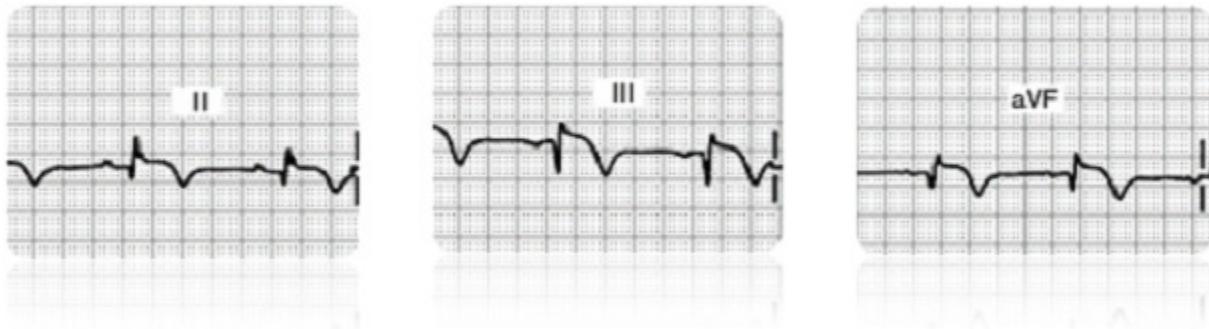
Test Yourself:

In the majority of the population, the right coronary artery supplies blood to the:

- A. Right atrium
- B. Right Ventricle
- C. AV node
- D. All of the above- Correct!

ECG Findings with Inferior Wall MIs

Do you see changes in Lead II, III, or aVF?

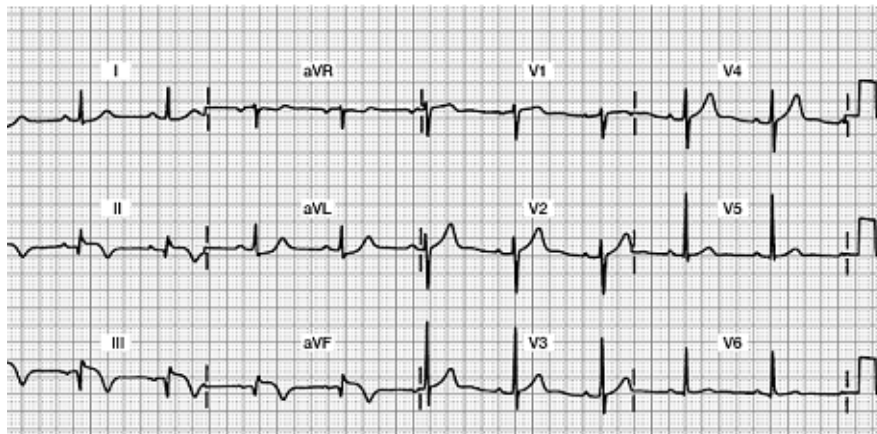


Acute Inferior Wall MI 12 Lead ECG

Focus on Leads II, III, and aVF

Do you see any abnormalities?

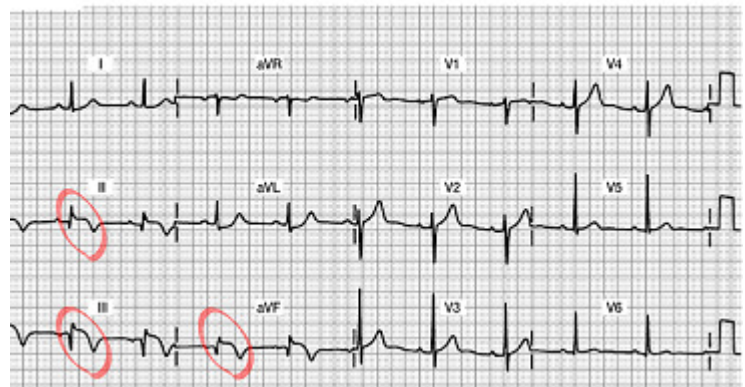
- Abnormal Q waves?
- Decreased R wave voltage?
- ST segment elevation?
- Inverted T waves?



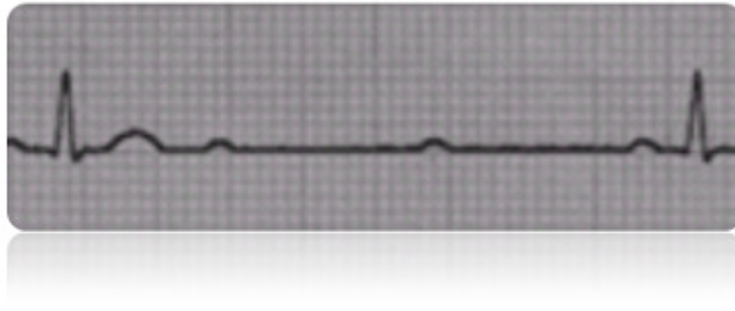
Acute Inferior Wall MI 12 Lead ECG

Do you see the 12 lead ECG abnormalities?

- Acute ST segment elevation in Leads II, III and aVF... this is a marker of “acute injury”
- Inverted T wave.... this will stay inverted for up to one month and will eventually return upright
- Abnormal Qs in Leads III and aVF... this is the beginning of the deep and wide Q waves... they will likely grow deeper as the days progress.
- Decreased R wave voltage (as the Qs grow deeper, the Rs get smaller... all the result of damaged myocardial tissue that is no longer able to conduct a normal impulse.



Potential Clinical Complications



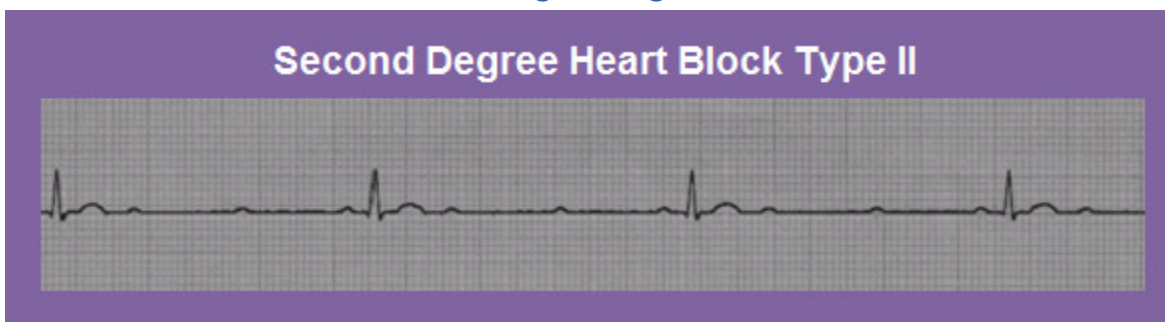
Potential clinical complications of RCA occlusion with resulting inferior wall STEMI include:

- **Sinus node disturbances:** Watch for sinus bradycardia, sinus arrest, and sinus exit blocks.
- **AV block:** Parasympathetic hyperactivity is common with IWMI so watch for first, second (usually Mobitz I), third degree conduction delays or “blocks” that may occur within hours or up through the first two days. AV conduction disturbances occur two to three times more frequently in inferior infarctions compared with anterior infarctions. Patients with second or third degree AV block have higher mortality rates.
- **Clinical Symptoms:** Nausea, vomiting and vasovagal syncope caused by enhanced vagal stimulation.
- **Suspect right ventricular damage:** The RCA also supplies the blood to the right ventricle (RV) in many individuals. Approximately one third of all inferior wall MI patients also have damage to the RV.

Early detection of RV infarction is important because therapy for right-sided heart failure is very different from therapy for left ventricular infarction. RV failure is usually treated with volume loading, whereas left ventricular failure is treated with preload reduction (i.e. diuretics, afterload reduction). RV infarction can be diagnosed with the ECG by using three leads placed on the right side of the chest or “right precordial leads,” V4R, V5R, V6R, creating a 15 lead ECG.

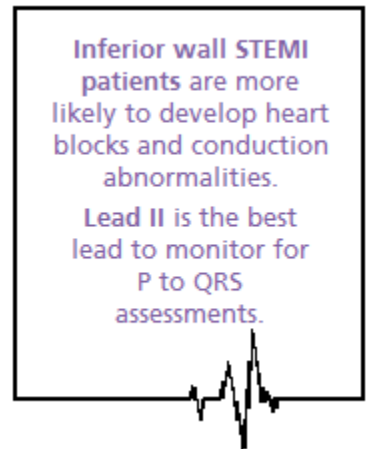
Many experts feel patients with inferior wall MIs should routinely receive right precordial lead monitoring with ECGs to detect potential RV infarction. The 15 lead ECG tracing is the standard of care at many hospitals. Other facilities may use 2-D echocardiograms to assess RV function.

[Larger Image:](#)

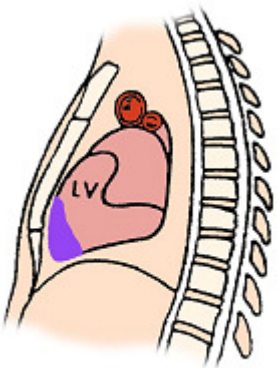


Medical and Nursing Management for Inferior Wall STEMI

- Collaborate with MD for candidacy for thrombolytic therapy or percutaneous coronary intervention (PCI) (example: angioplasty with intracoronary stent) which is performed in the cath lab. If the patient is to receive a thrombolytic, the goal is to administer this drug within 30 minutes. If the goal is to send the patient to the cath lab for a PCI, the goal is to have this started within 90 minutes. Remember that “time is muscle,” so we must work with the interdisciplinary team in a highly coordinated fashion.
- Routine post-MI care: pain relief, stress reduction, oxygen therapy, continuous monitoring for arrhythmias, heart and lung assessments.
- Monitor in Lead II; a good lead to assess for “P waves” for optimal viewing of potential heart blocks.
- Support patients who develop symptomatic bradycardia or AV blocks. Your patient may need temporary pacing, and/or IV Atropine to support a slow heart rate and resulting decrease in cardiac output.
- Incorporate concepts of contractility, preload, and afterload into bedside assessment.
- Communicate abnormal findings to provider.



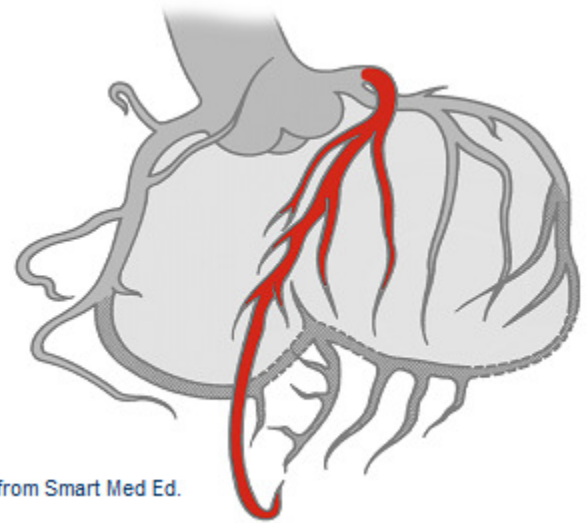
Anterior Wall MI



Used with permission from Smart Med Ed.

Coronary Artery Source: Acute anterior wall MIs (AWMI) are a form of STEMI and can be very serious since there is acute damage to the left ventricle. Damage to the anterior wall of the left ventricle is typically due to impaired blood flow from the left anterior descending (LAD) coronary artery.

Left Anterior Descending (LAD) Coronary Artery Blood Supply

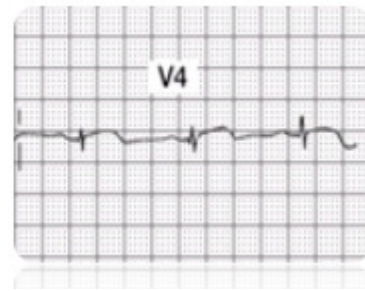
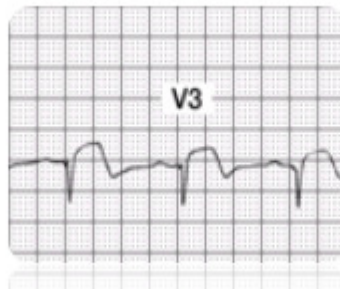
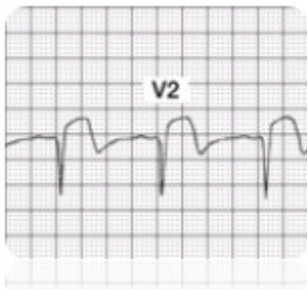


Used with permission from Smart Med Ed.

LAD Supplies blood to:

- Anterior wall LV
- Interventricular septum
- Right Bundle Branch
- Anterior division of Left Bundle Branch
- Papillary muscles to mitral valve

ECG Findings with Acute Anterior Wall MI

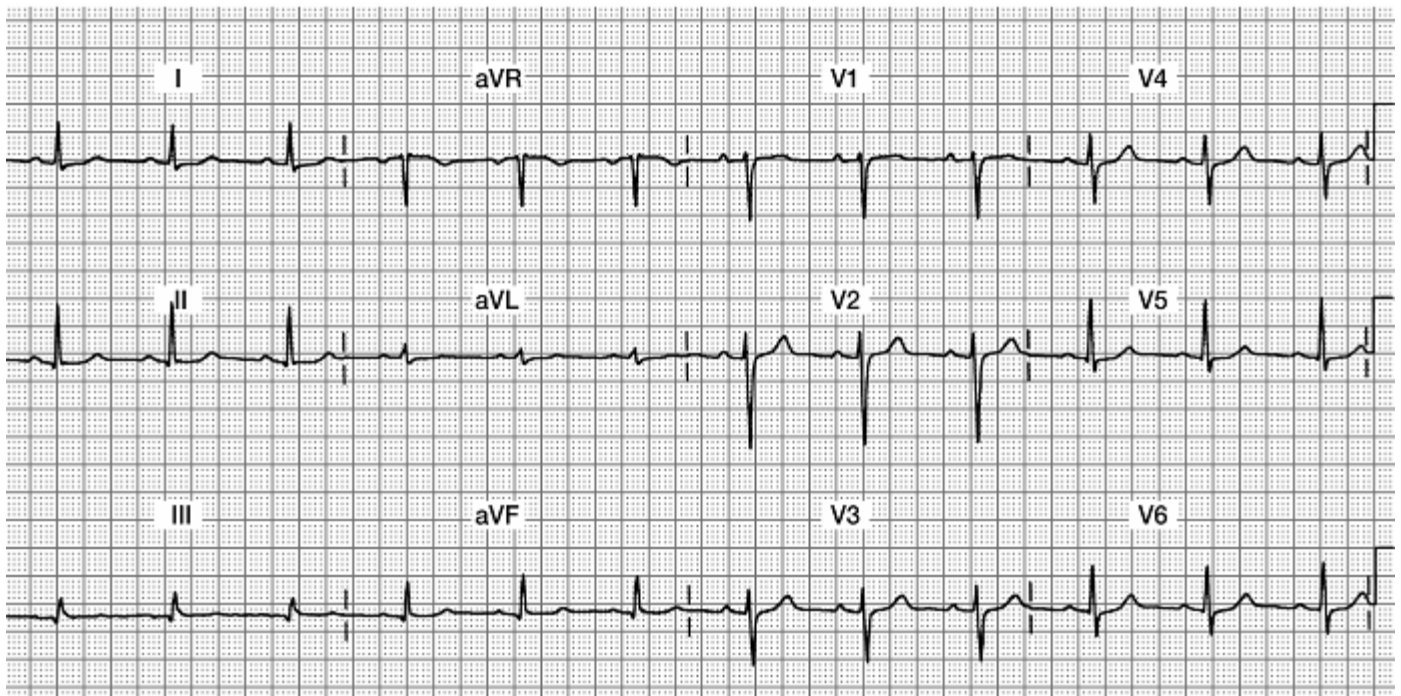


Infarcted tissue on the anterior wall of the ventricular myocardium will no longer depolarize toward the anterior chest wall (where the positive electrodes V1 through V6 are placed). Anterior wall damage is evidenced by abnormal ST segment elevation, followed by development of abnormal Q waves in **leads V1 through V4** (or possibly just V2, V3 and V4). Additionally, many patients lose their R wave voltage in these leads.

Note: To be diagnosed with an acute anterior MI, you must see these **changes in at least two out of the four V1-V4 leads**.

Acute Anterior Wall MI 12 Lead ECG

Focus on Leads V1, V2, V3, and V4



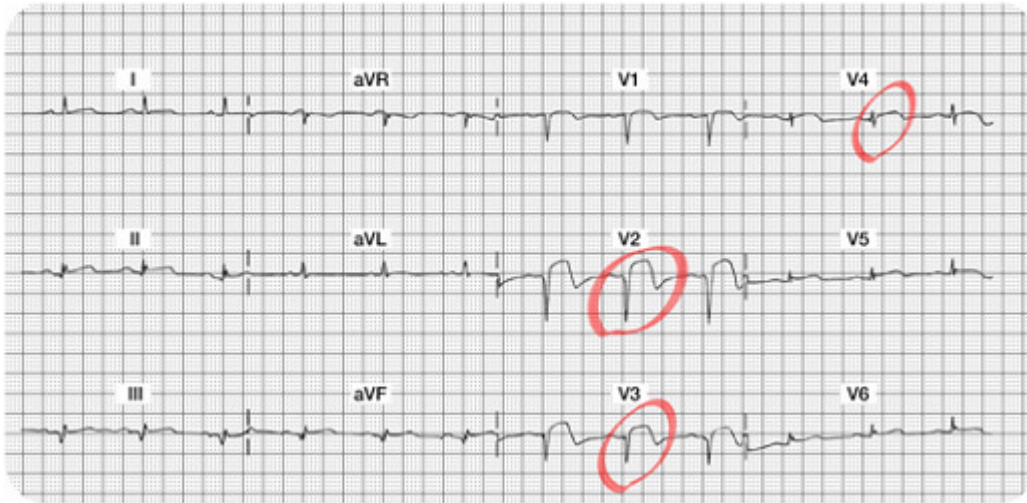
Do you see:

- Acute ST elevation?
- Abnormal Qs?
- Decreased R wave voltage?

Acute Anterior Wall MI 12 Lead ECG

Do you see the 12 lead ECG abnormalities?

- Acute ST segment elevation in Leads V2, V3, and V4... this is a marker of "acute injury."
- Abnormal Qs in V1, V2, and V3 leads... these Q waves are very deep and should be obvious.
- Decreased R wave voltage (as the Qs grow deeper, the Rs get smaller...all the result of damaged myocardial tissue that is no longer able to conduct a normal impulse). Note there are NO R waves in V1, V2, and V3... and the R wave voltage is also minimal in V4-V6. The patient will be left with permanent Q waves and a lack of "R wave progression."



Potential Clinical Complications of an Anterior Wall MI

The prognosis of patients with anterior wall MI (AWMI) is significantly worse than patients with inferior wall MI. Anterior MI is associated with more myocardial damage than inferior infarction; this damage affects LV function, a major determinant in prognostic outcome after acute MI. An infarction involving 40% or more of left ventricular myocardium is generally associated with cardiogenic shock.

Clinical complications of left coronary artery occlusion include:

- **Pump disturbances:** Weak cardiac output, low B/P, weaker pulses, lower urinary output which may lead to CHF. Unless the infarction is massive, signs and symptoms of CHF generally do not occur until a few days after the infarction. However, acute pulmonary edema may occur within the first few hours. Despite advances in medical technology, cardiogenic shock continues to have a high mortality rate.
- **Arrhythmias:** Sinus tachycardia (compensatory mechanism for lower cardiac output), PVCs (which might progress to Ventricular Tachycardia), PACs, Mobitz II heart block.
- **BBB:** New bundle branch blocks: either right or left BBB may result from occlusion to the LAD. You may also know this ECG abnormality as an intraventricular conduction delay (IVCD). When one of the two bundle branches is not conducting normally, the QRS is widened. Notify the provider if you identify the widened QRS. Patients with bundle branch block may need a pacemaker.

Test Yourself:

The prognosis of patient with an _____ wall type of acute MI is significantly worse than patients with an _____ wall acute MI.

Answer:

Anterior Wall & Inferior Wall

This is because the anterior wall damage involves the left ventricle, which is the main pumping chamber of the heart. Expect a drop in cardiac output and overall ejection fraction and stroke volume.

Medical and Nursing Management for Acute Anterior Wall STEMI

- Similar to the inferior wall MI patient, the patient may be a candidate for thrombolytic therapy or PCI. If the patient is to receive a thrombolytic, the goal is to administer this drug within 30 minutes of the onset of pain. If the goal is to send the patient to the cath lab for a PCI, the goal is to have this started within 90 minutes of hospital arrival (AHRQ, 2011)
- Routine post-MI care: pain relief, stress reduction, oxygen therapy, continuous monitoring for arrhythmias, heart and lung assessments.
- Assess for signs and symptoms of right heart failure, left heart failure or biventricular failure. A third heart sound (S3) is more common in patients with an anterior wall MI than with other types of MIs. In patients with a third heart sound during the acute phase of infarction, the mortality is 40%, as compared with 15% in patients without a third heart sound. A new S3 can indicate ventricular overload and impending pump failure.
- Monitor in the V1 lead. This lead will help you differentiate SVT versus VT (should they be having lots of ventricular arrhythmias). Patients with AWMIs might also lose blood flow to the Right Bundle Branch (supplied by the LAD coronary artery) and could develop a new RBBB. You can only diagnose a RBBB in leads V1 and V6, thus another good reason to use V1 as your bedside lead!
- Incorporate concepts of contractility, preload and afterload into bedside assessment. For example has the B/P or pulse strength changed? Is the urinary output adequate? Are there any sign of hypovolemia? Are there any changes from baseline peripheral skin circulation assessment?
- Communicate abnormal findings to provider.

Lateral Wall MI

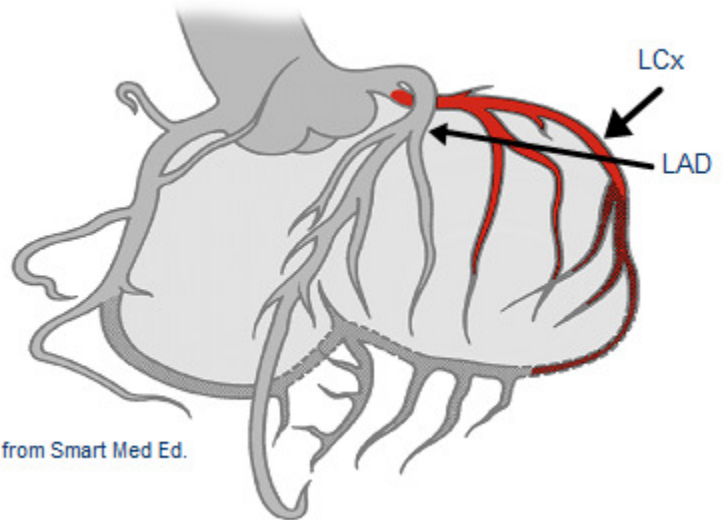
Coronary Artery Source

The left coronary artery splits in to the left circumflex (LCx) and the left anterior descending (LAD) artery. The left circumflex artery supplies the lateral (and sometimes part of the inferior) myocardium. The lateral wall of the heart faces up toward the left shoulder.

Left Circumflex (LCx) Coronary Artery Blood Supply

L Circumflex (LCx) supplies blood to:

- Lateral wall LV
- Posterior wall LV (10% of population described as "left dominant")
- SA Node in 45% of the population



ECG Findings

The leads which best visualize the lateral wall are Leads **I, aVL**, ("high" lateral wall) **V5** and **V6** ("low" lateral wall). ST segment elevations, followed by the development of Q waves are typically seen in this setting. Loss of R wave voltage may also be detected.

Note: Abnormal ST elevation and resulting Q waves may be seen in only two of the four leads but this remains diagnostically positive for a Lateral MI. For example, new abnormal ST elevation and abnormal Q waves may be seen in only the high lateral (I, aVL), or in the low lateral (V5, V6), or may be seen in all four leads.

Purely isolated "Lateral MIs" are rare. Typically, Lateral MIs are seen in association with Anterior MIs resulting in an "Anterior-Lateral MI" or "Inferior-Lateral" infarctions.

Test Yourself:

ECG changes associated with damage to the anterior surface of the heart are best seen in leads _____.

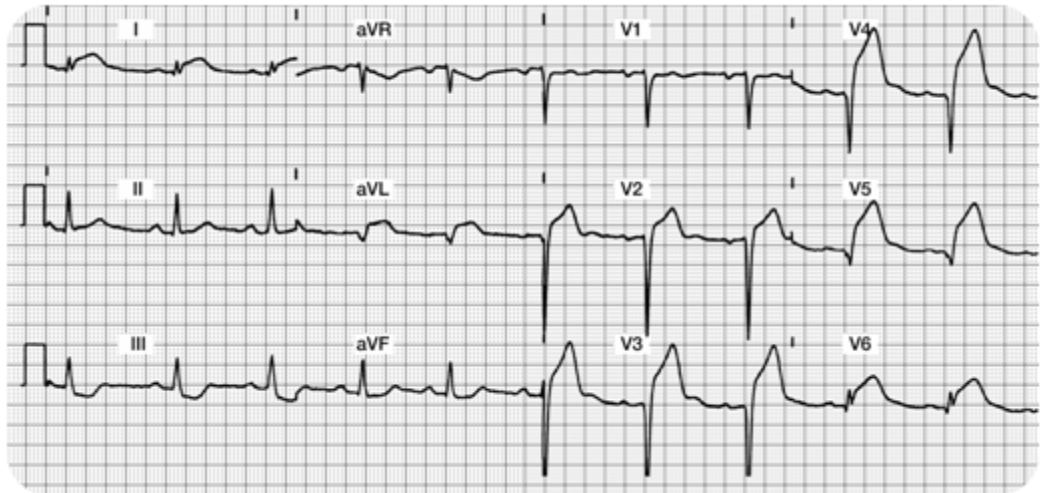
- A. Lead I, aVL, V5, V6- Correct!
- B. Lead II, aVR, V4, V5
- C. Lead I, aVF, V2, V3

Sample of an Acute Anterior Lateral Wall MI

Focus on Lateral Leads: I, aVL, V5 and V6 along with
Anterior Leads: V1, V2, V3 and V4

Do you see:

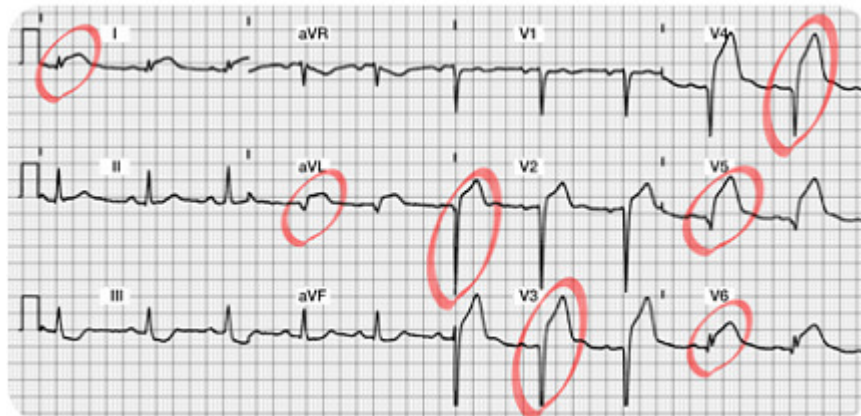- Acute ST elevation?
- Abnormal Qs?
- Decreased R wave voltage?



Sample of an Acute Anterior Lateral Wall MI 2

Do you see the 12 Lead ECG abnormalities?

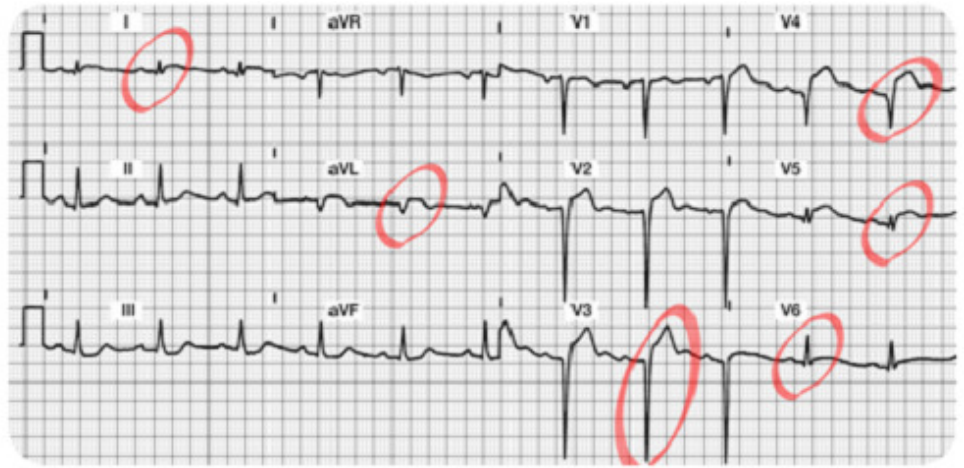
- Acute ST segment elevation in Leads I, aVL, V5, and V6 (the lateral leads!!) and also ST elevation in Leads V2, V3 and V4. This demonstrates a large area of "acute injury."
- Abnormal Qs in aVL, V2, V3 and V4 leads. These Q waves are $\geq .04$ seconds wide and $\geq 25\%$ the height of the R wave. As time progresses, the patient may also develop abnormal Qs in lead I, V5 and V6.
- Decreased R wave voltage...there are NO R waves in V2 – V5. The R wave is also missing in aVL. It looks like the patient will be left with permanent Q waves and a lack of "R wave progression."



Patient Scenario

A patient with anterior MI (refer to the 12 lead ECG featured on the previous page) is taken to the cardiac catheterization lab for a coronary angiogram. A proximal lesion in the Left Circumflex was discovered with 99% occlusion. The patient underwent a percutaneous coronary intervention (PCI) consisting of a combination percutaneous transluminal coronary angioplasty (PTCA) and the insertion of an intra-coronary stent. The vessel was successfully re-opened.

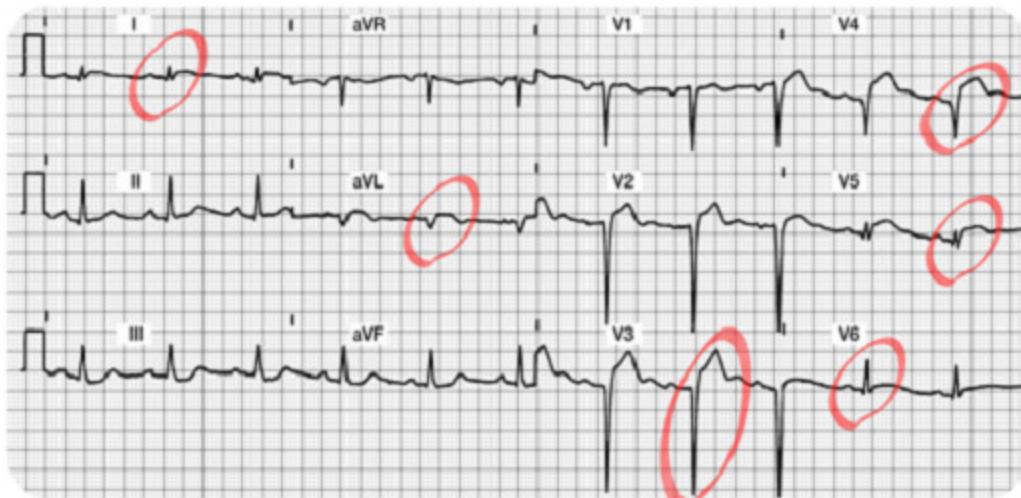
Pictured is the post-procedure 12 lead ECG taken 30 minutes following the successful revascularization of the Left Circumflex coronary artery.



Patient Scenario

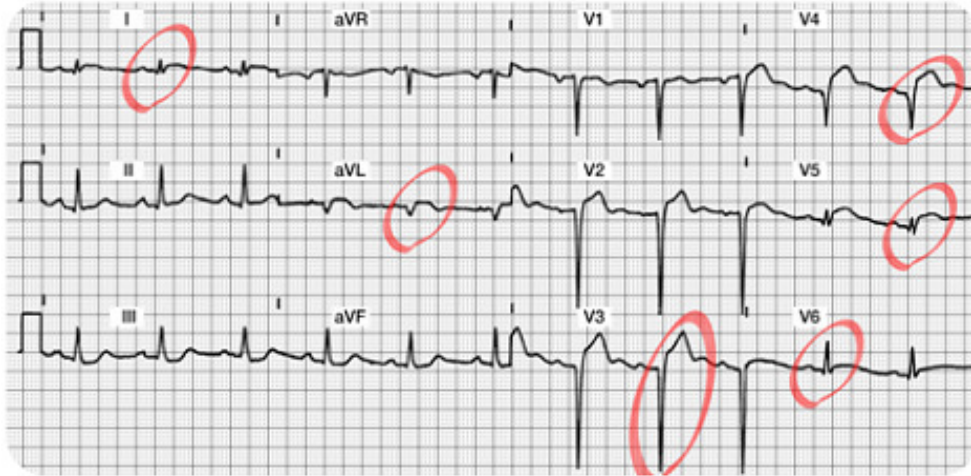Note the dramatic reduction of ST segment elevation in Leads I, aVL, V3, V4, V5 and V6.

If you do not find reduced ST elevation post PCI, notify the MD of this abnormal finding. As the myocardium is "reperfused," expect to find decreased "injury" on the ECG. The patient should be pain free.



Patient Scenario

The ST segments should be trending downward. It may take several days for the ST segments to return to baseline. The patient will likely be left with some permanent abnormal Q waves.



More Information:

You might be wondering, “How much ‘actual’ myocardial tissue damage was done?” and “Do the Q waves reflect that actual damage really did take place?”

Most cardiologists agree that the two dimensional echocardiogram (2-D Echo) is the best test to fully evaluate the effectiveness of the PCI (or results from a thrombolytic agent). The 2-D echo shows contractility and overall heart function in all four chambers.

Potential Clinical Complications

With the rare isolated “Lateral Infarct,” presenting signs and symptoms are usually benign. This type of MI usually produces minimal hemodynamic complications.

Medical and Nursing Management for acute Lateral Wall Infarctions

- Collaborate with MD for candidacy for thrombolytic therapy or PCI in the cardiac cath lab.
- Routine post-MI care: pain relief, stress reduction, oxygen therapy, continuous monitoring for arrhythmias, heart and lung assessments.
- Best leads to monitor: any of the lateral leads (I, V5 and V6 are best).
- Incorporate concepts of contractility, preload and afterload into assessment.
- Communicate abnormal findings to MD.

This table summarizes the best leads for detection of acute myocardial abnormalities.

Type of Myocardial Infarction	Best Leads
Inferior Wall	II, III, aVF
Anterior Wall	V1, V2, V3, V4
Lateral Wall	I, aVL, V5, V6
Anterior Lateral Wall	I, aVL, V5, V6, V1-V4

STEMI ECG Interpretation Format or Recipe

It is now time to practice your new skills. Try using this "format" to interpret your 12 lead ECGs. Remember, if you follow a systematic approach, your success rate will be enhanced!

Step 1. Assess the Lateral Leads (I, aVL, V5, and V6).

- Begin with Lead I. Look for normal or abnormal Q waves. Is the ST segment on the baseline? If not, is it depressed/inverted (i.e. ischemia) or elevated (i.e. injury)?
- Is there an R wave in every lead (except aVR, which we are ignoring)?
- Continue to look at all of the Lateral Leads as if they were a family grouping. Examine leads I, aVL, V5 and V6 again. Do you find changes in at least two of the four leads? Continue to examine the Q, R, and ST segments.
- Write down your "summary of the lateral wall" ... You are now read to progress and evaluate the inferior wall.

Step 2. Assess the Inferior Leads (II, III, aVF).

- Look for normal or abnormal Q waves.
- Is there an R wave in all three leads? (There should be although the amplitude in lead III and aVF may be small).
- Is the ST segment on the baseline? If not, is it depressed/inverted (i.e. ischemia) or elevated (i.e. injury)?
- Look at the inferior leads as a family. You must find changes in at least two out of three leads.

Step 3. Examine the Anterior Leads (V1-V4).

- Are there any abnormal Q waves?
- Do you see upright R waves in all leads? Do the R waves grow or become progressively larger in amplitude? (they should).
- Are the ST segments on the baseline in all leads except V1 which is biphasic? Evaluate the anterior leads as a family. Are there changes or abnormalities in at least two of the four leads?

Good Job!! Now you are ready to prioritize and summarize!

Step 4. Identify Acute Injury (if present).

- This is the most dangerous and requires immediate attention.
- Remember acute injury is characterized by ST segment elevation which must be seen in the majority of the "lead groupings" (e.g. ST elevation seen in two thirds of the inferior leads II, III, and aVF).

Step 5. Identify Patterns of Ischemia (if present).

- Remember ischemia is recorded as ST or T wave inversion. This typically reflects an inadequate oxygen supply to meet the myocardial demands.
- This is an opportunity to intervene and prevent a transmural or STEMI.

Step 6. Identify any "old" acute MI patterns.

- Old MIs are permanently recorded on the ECG as **abnormal Q waves with normal ST**

segments and T waves. The wide and deep Qs will never go away.

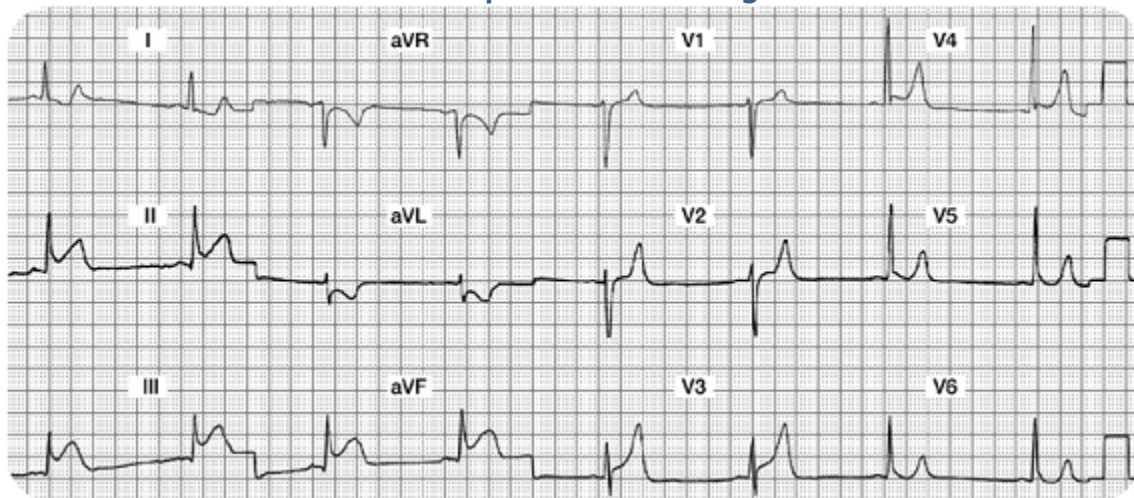
- Remember that loss of R wave voltage may also be seen in these same leads.

Let's Practice!!

Case Study One

Mr. A is admitted to your unit with the diagnosis of chest pain, rule out MI. He is currently pain free with stable vital signs. After returning from the bathroom, he complains of severe indigestion in the retrosternal area of his chest. He rates his "indigestion" as 9 on a scale of 0 - 10. Mr. A tells his nurse he is very scared. He is diaphoretic and his initial vital signs are 88/58, RR 20.

Please interpret the following ECG:



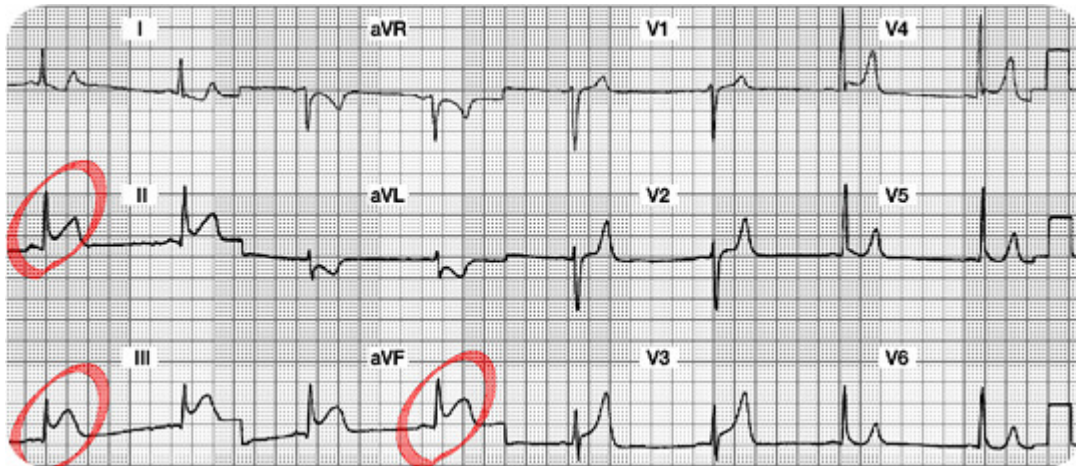
Your 12 Lead Worksheet:

1. Summary of the Lateral Leads (I, aVL, V5, and V6):
2. Summary of the Inferior Leads (II, III, aVF):
3. Summary of the Anterior Leads (V1, V2, V3, V4):
4. Interpretation:
5. Which coronary artery is probably occluded?
6. What potential complications are you looking for?
7. What bedside lead should you select to monitor this patient?
8. What are your nursing priorities?

Case Study One: 12 Lead Worksheet Answers

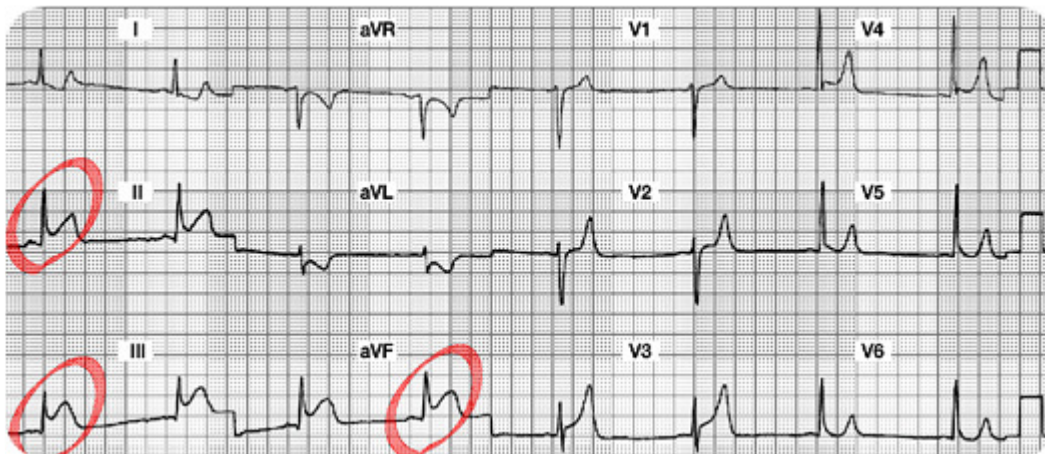
1. Summary of the Lateral Leads (I, aVL, V5 and V6):

Lead I and aVL have ST segment depression (? Ischemia). Leads V5 and V6 are normal. All Lateral leads do not have abnormal Q waves.

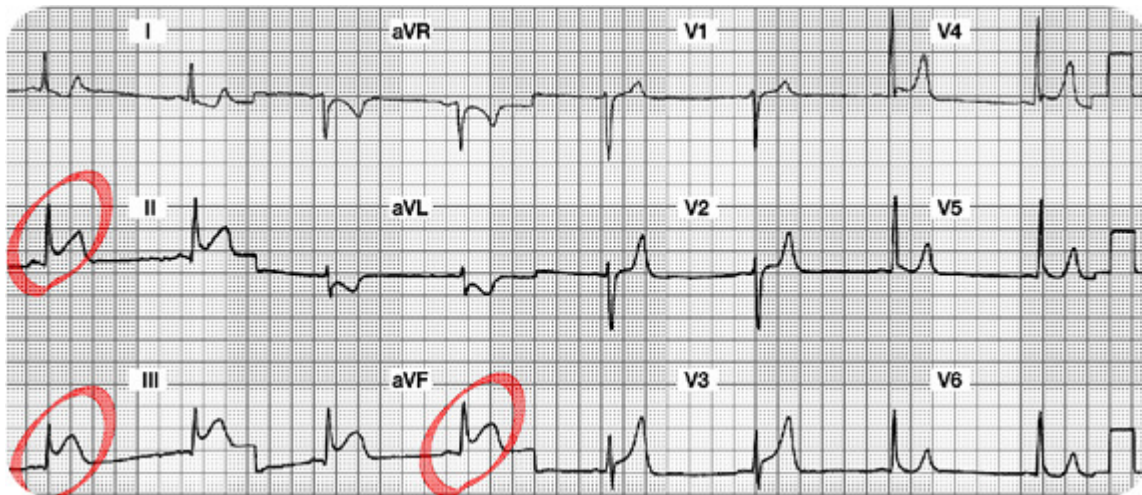


2. Summary of the Inferior Leads (II, III, aVF): ST elevation in all three leads. No abnormal Q waves.

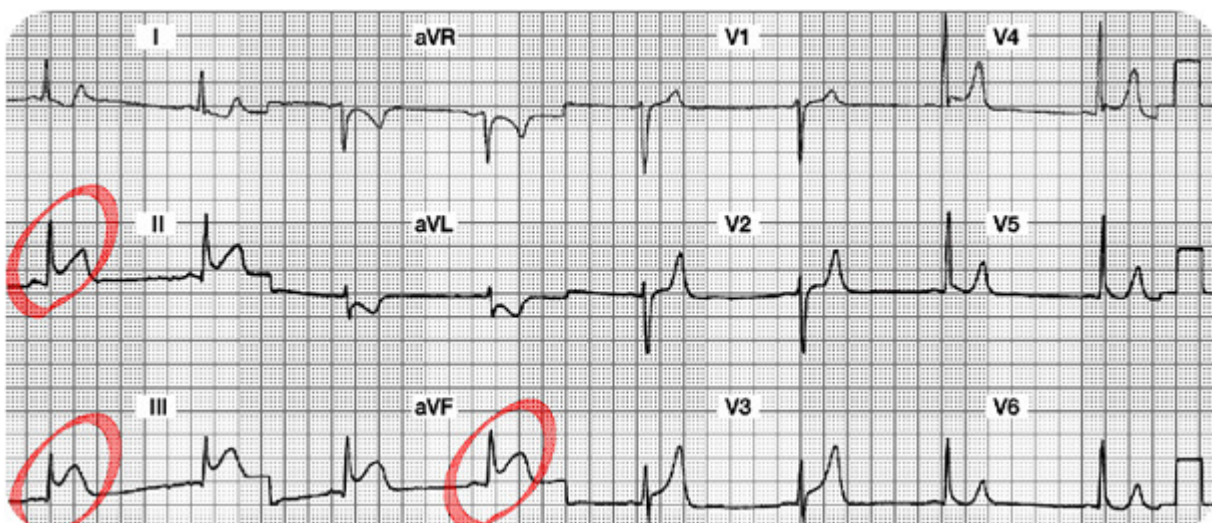
3. Summary of the Anterior Leads (V1, V2, V3, V4): Good R wave progression. No abnormal Q waves. ? ST segment elevation in V3 and V4 versus large T waves throughout the anterior leads.



4. **Interpretation:** Acute Inferior Wall STEMI (or injury).
(We will keep an eye on the ST segments in V3 and V4, but the predominant problem lies with the inferior wall.)
5. **Which coronary artery is probably occluded?** Right Coronary Artery

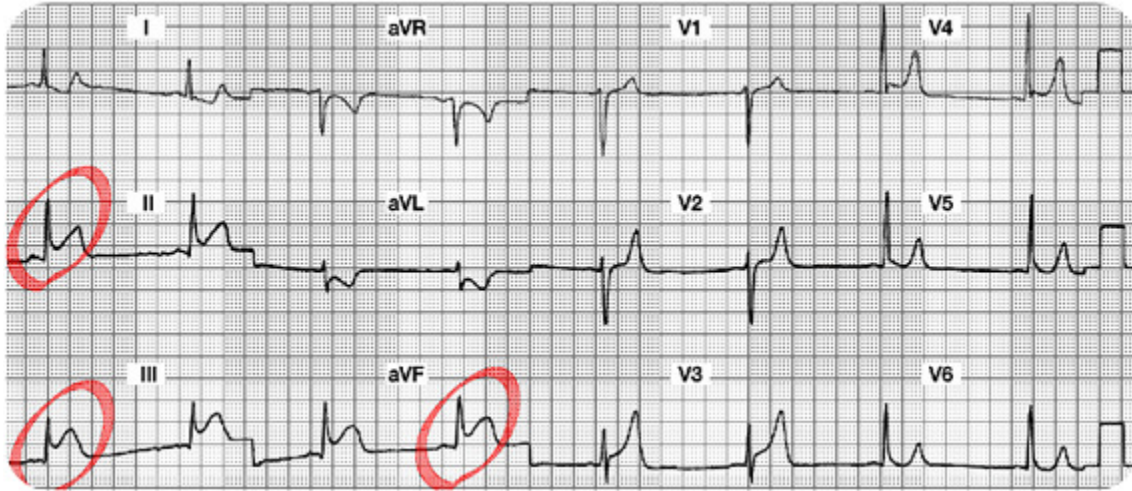


6. **What potential complications are you looking for?**
Conduction abnormalities such as heart blocks, and/or damage to the Right Ventricle.
7. **What bedside lead should you select to monitor this patient?** Lead II



8. What are your nursing priorities?

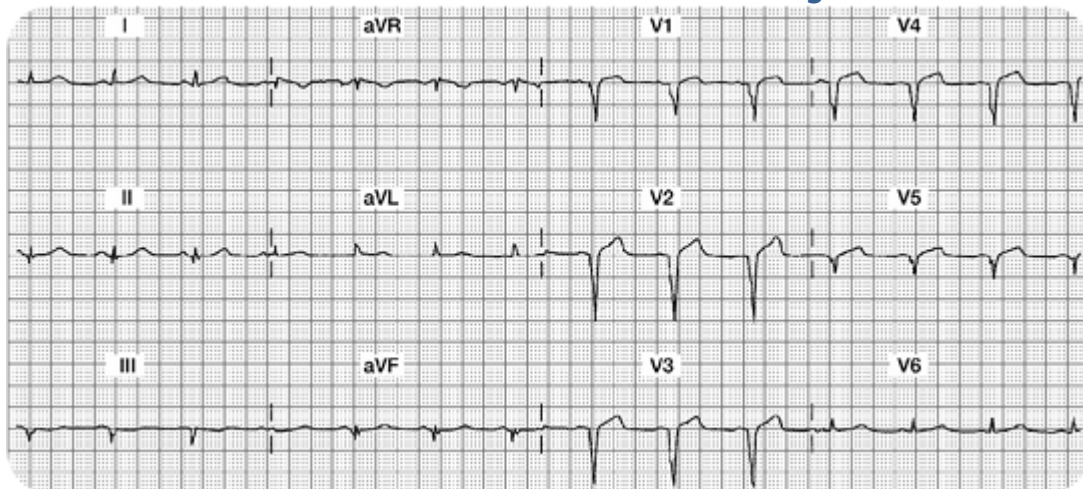
- Relieve chest pain by decreasing myocardial oxygen consumption (e.g. rest) and increase oxygen supply (e.g. aspirin, oxygen, nitrates, morphine, etc).
- Consult with MD regarding candidacy for either a) systemic IV thrombolytic medication or b) a trip to the cath lab for PCI.



Case Study Two

Mrs. B. is transferred to your unit from acute care with new onset chest discomfort. Her hemodynamics are stable. Cardiac marker lab results are pending.

The 12 lead ECG shows the following:



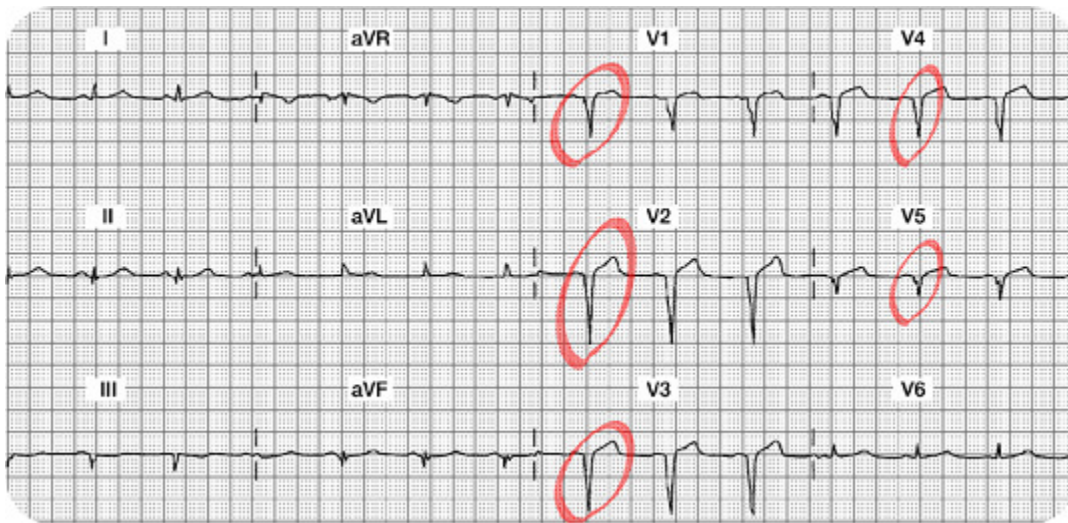
Your 12 Lead Worksheet:

1. In this setting, would you expect the cardiac marker labs to be positive or negative?
2. What bedside lead should you select to monitor this patient?
3. What are your nursing priorities?

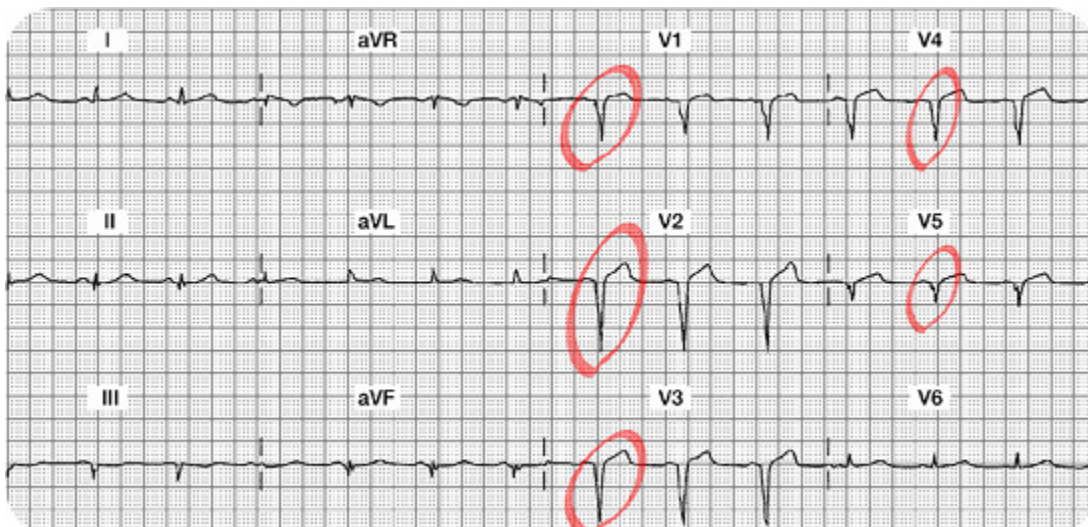
4. Summary of the Lateral Leads (I, aVL, V5, and V6):
5. Summary of the Inferior Leads (II, III, aVF):
6. Summary of the Anterior Leads (V1, V2, V3, V4):
7. Interpretation:

Case Study Two: 12 Lead Worksheet Answers

1. **Summary of the Lateral Leads (I, aVL, V5 and V6):** Leads I and aVL both have a normal ST segment on the isoelectric line. T waves are normal. V5 is has an abnormal Q wave but normal ST segment. The R wave is also missing in V5. V6 has a normal ST segment and no abnormal Q waves.

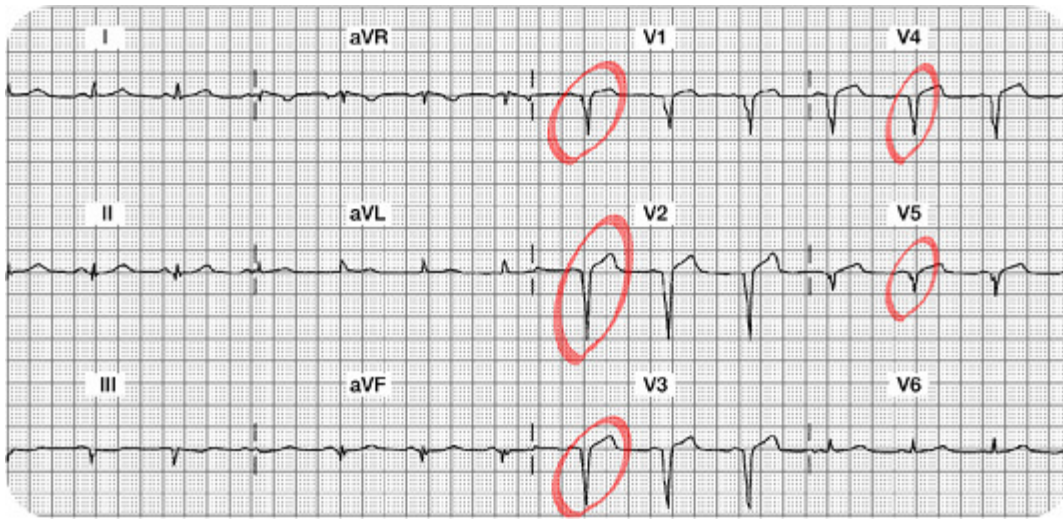


2. **Summary of the Inferior Leads (II, III, aVF):** All three leads are a bit difficult to evaluate because they are small in size. Lead II has a normal small Q wave, a small upright R wave and a normal ST segment and T wave. Lead III has an abnormal QS morphology, loss of R wave and a flat versus slightly inverted T wave. Lead aVF has a small (normal) Q, small R wave and normal ST segment and T wave.



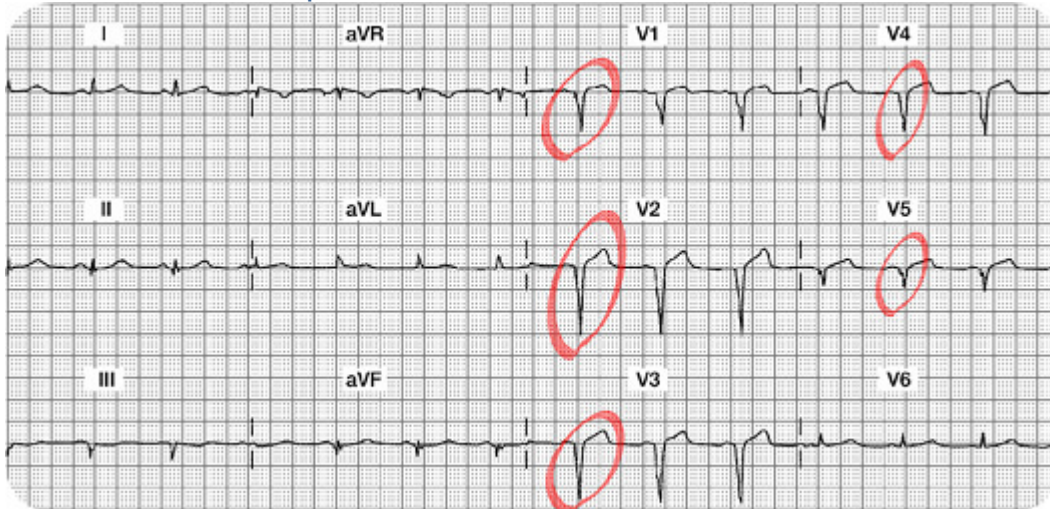
3. Summary of the Anterior Leads (V1, V2, V3, V4): V1, V2, V3 and V4 do not have any R waves. Instead, there are abnormal Q waves in all four leads or otherwise called a QS morphology. The ST segment and T waves are normal.

4. Interpretation: Old (chronic) Anterior Wall MI. This MI is "old" because in addition to the permanent Q waves, the ST segment, and T waves are normal.



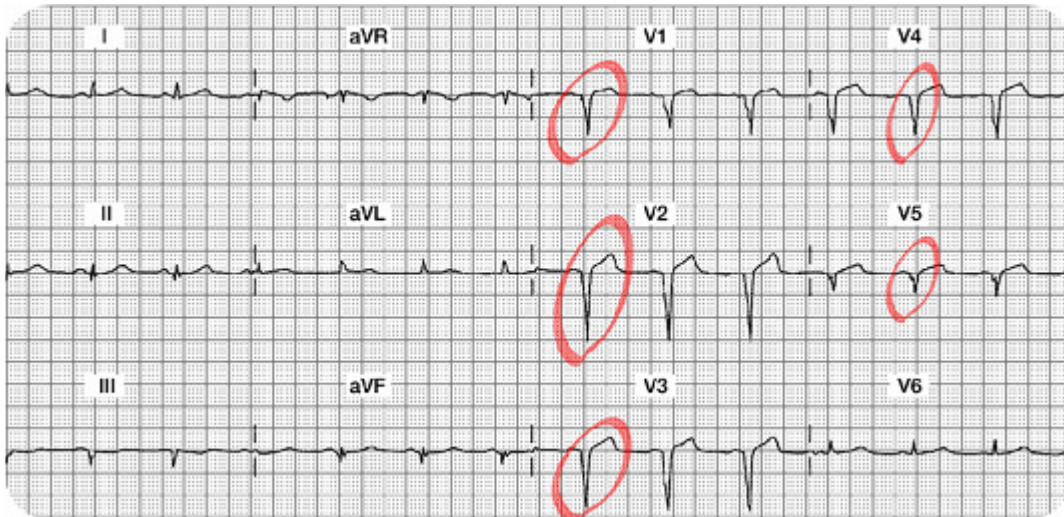
5. In this setting, would you expect the cardiac marker labs to be positive or negative?

6. What bedside lead should you select to monitor this patient? Since there are no acute changes, any bedside lead is acceptable.



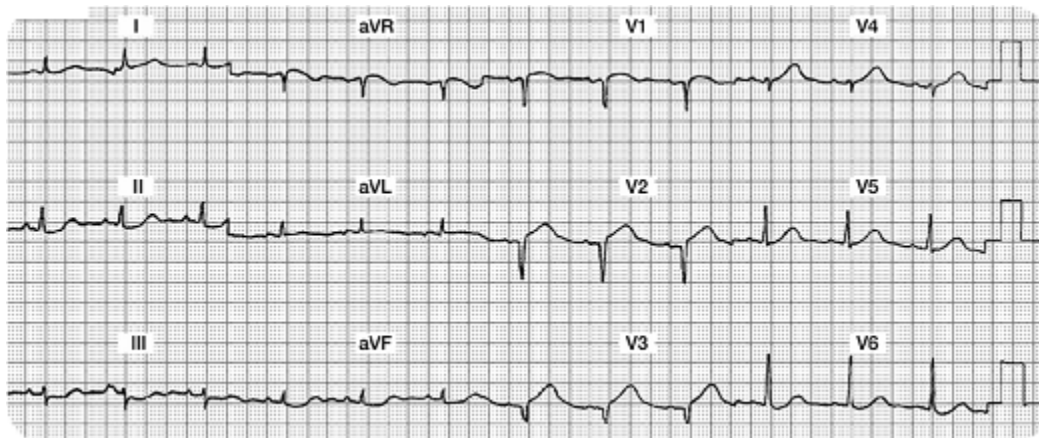
7. What are your nursing priorities?

1. Compare this 12 lead to a previous 12 lead from an old chart. Look to see if these abnormal Q waves were there before.
2. Monitor cardiac markers to be sure this is all old stuff.
3. Search for other possible causes of this chest discomfort.
4. Confirm that there is no new damage.



Case Study Three

Two hours after returning from the cath lab status post intracoronary stent insertion to his LAD, Mr. W. c/o some chest and left arm discomfort. You administer oxygen and sublingual NTG per unit protocol and obtain the following 12 lead ECG:



Your 12 Lead Worksheet:

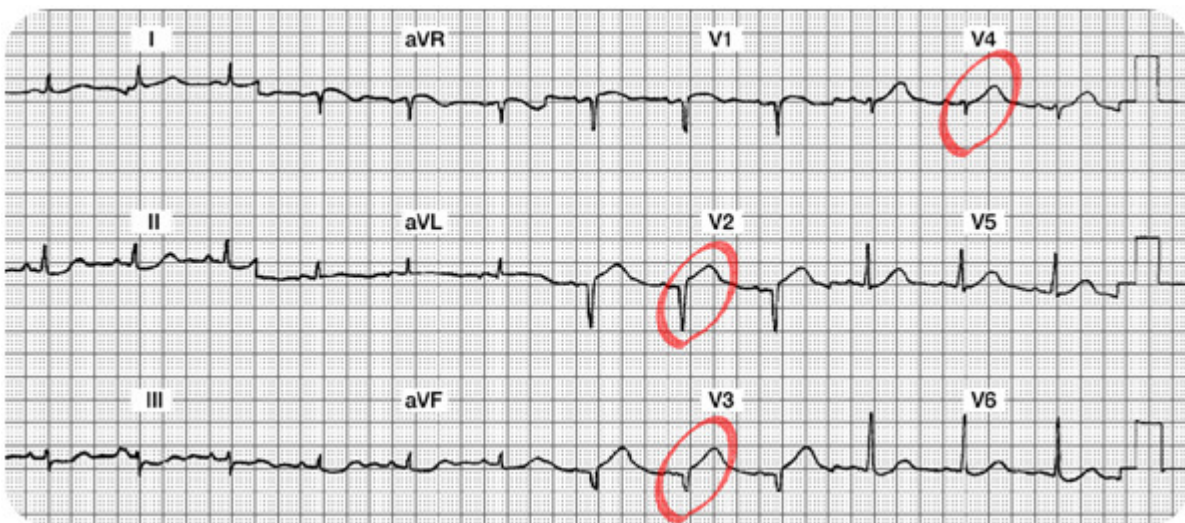
1. Which coronary artery is probably occluded?
2. What bedside lead should you select to monitor this patient?
3. What are your nursing priorities?
4. Summary of the Lateral Leads (I, aVL, V5, and V6):
5. Summary of the Inferior Leads (II, III, aVF):

6. Summary of the Anterior Leads (V1, V2, V3, V4):

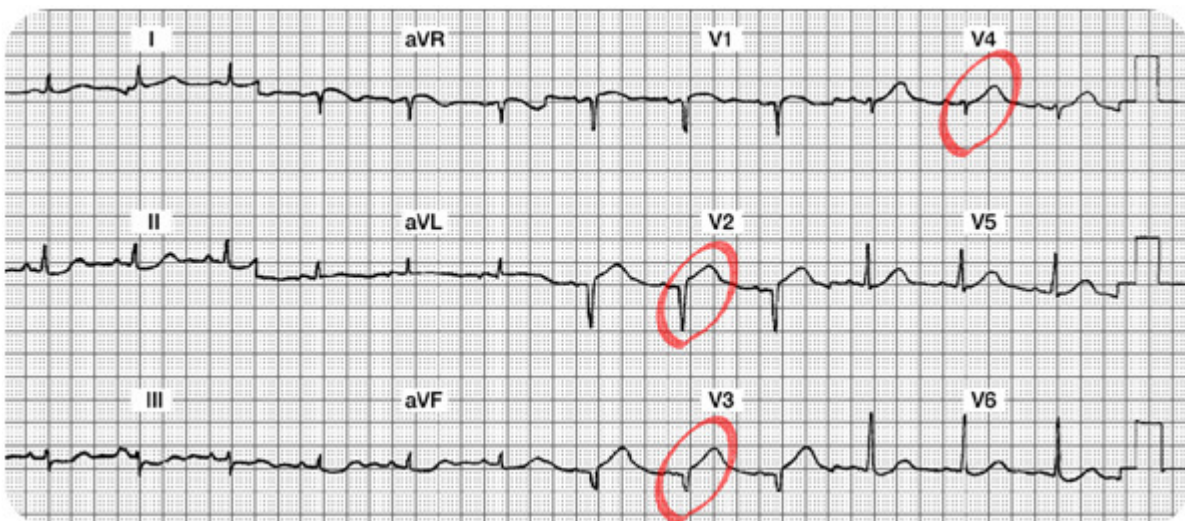
7. Interpretation:

Case Study Three: 12 Lead Worksheet Answers

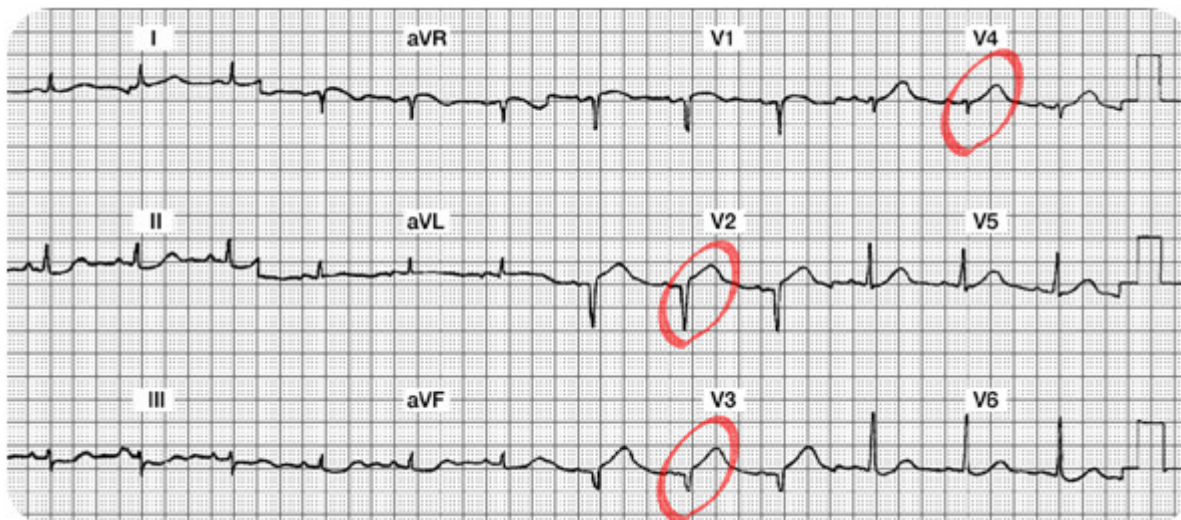
1. **Summary of the Lateral Leads (I, aVL, V5 and V6):** Leads I, aVL, V5 and V6 are all normal. There are no abnormal Q waves, no ST-T abnormalities. There is a wandering baseline in Lead I (making it a bit more difficult to read... remind the patient to lie very still when the 12 Lead ECG is being recorded).



2. **Summary of the Inferior Leads (II, III, aVF):** All three inferior leads have small complexes and there is a wandering baseline or artifact (making it harder to read). However, there are no abnormal Q waves, normal R waves (small, but present), and the ST-T segments and waves appear normal.

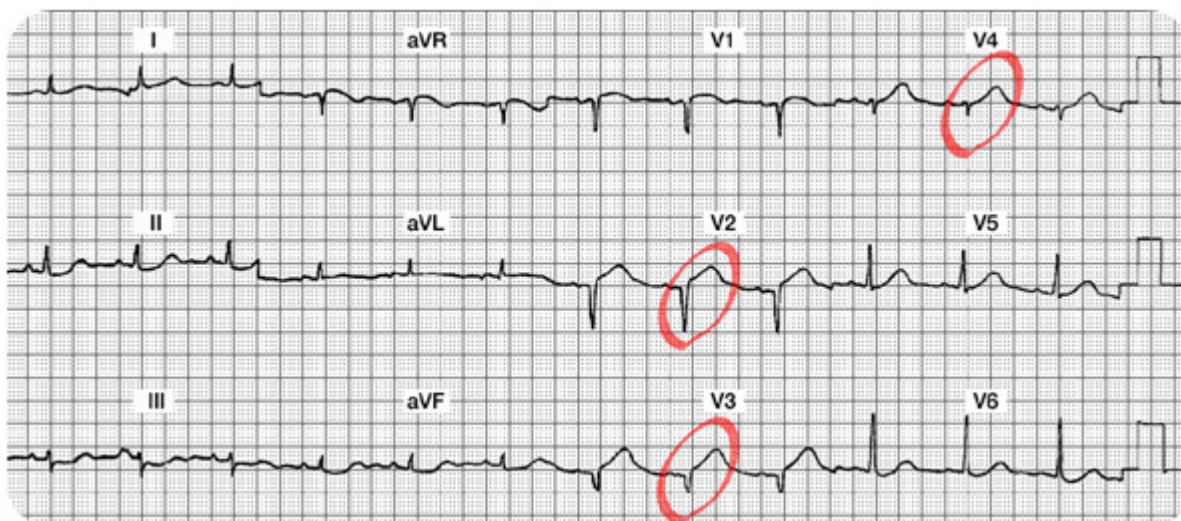


3. **Summary of the Anterior Leads (V1, V2, V3, V4):** V1 might have a small R wave, but it is difficult to see. The ST-T in V1 looks normal. V2 and V3 are missing their R waves and both have abnormal Q waves with new ST segment elevation. V4 has a small R wave and a small amount of ST elevation.



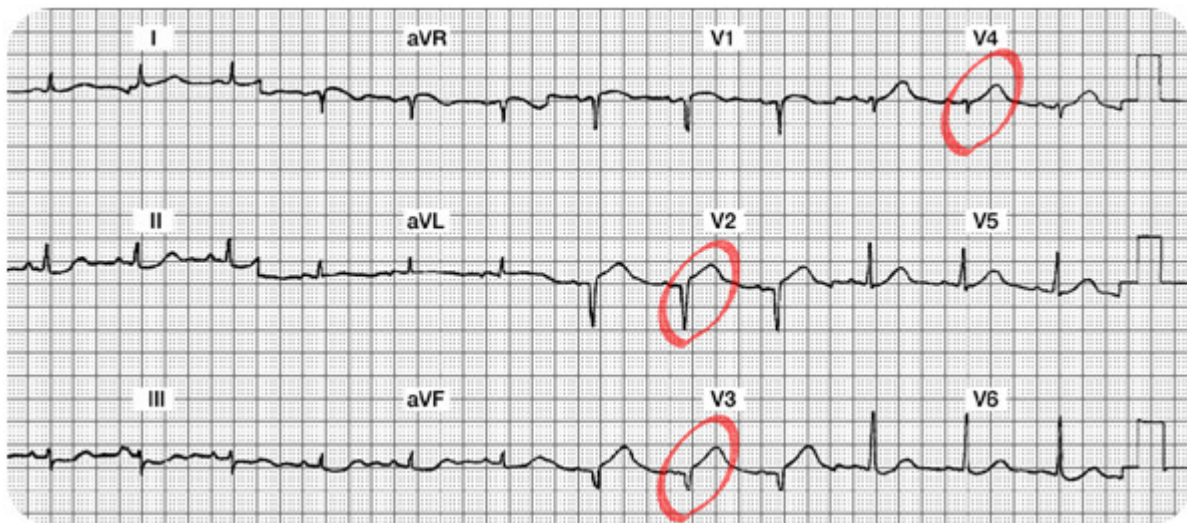
4. **Interpretation:** New Anterior STEMI or acute Anterior wall MI

5. **Which coronary artery is probably occluded?** The LAD feeds the anterior surface of the myocardium.



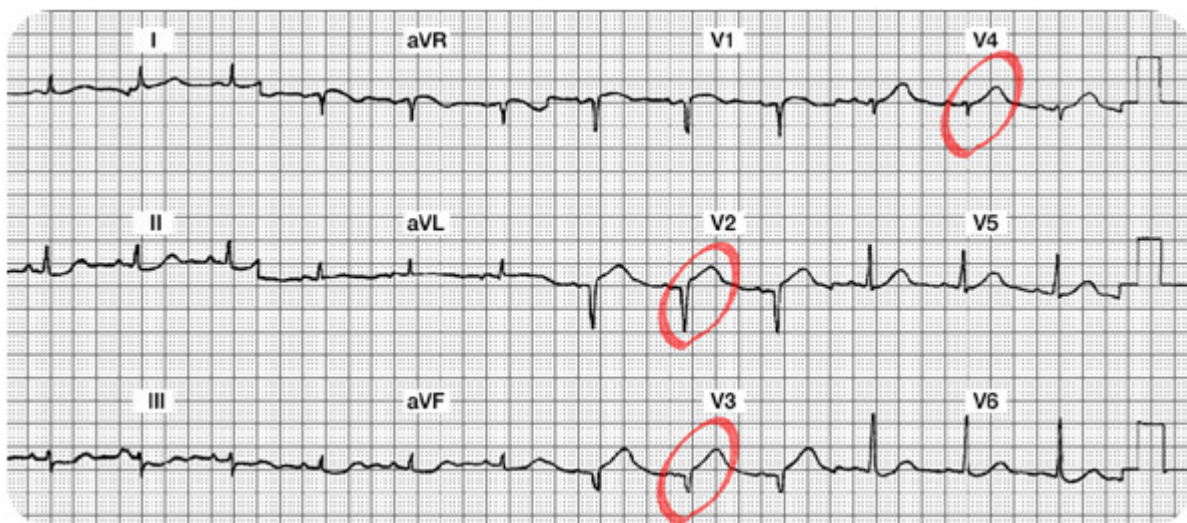
6. What bedside lead should you select to monitor this patient?

V1. In this lead you can monitor for changes in ST segments, potential new right bundle branch block, and can use ECG criteria to differentiate potential Supraventricular Tachycardia (SVT) versus Ventricular Tachycardia (VT).



7. What are your nursing priorities?

- 1) Relieve chest pain by decreasing myocardial oxygen consumption (e.g. rest) and increase oxygen supply (e.g. oxygen, nitrates, morphine, etc).
- 2) Consult with MD regarding candidacy for either a thrombolytic or PCI.



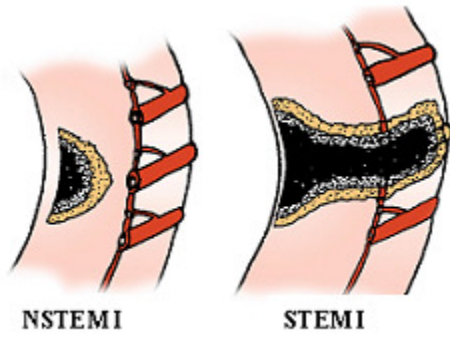
Non ST Elevation Myocardial Infarctions

Overview

Thus far, this module has focused on patient experiencing a ST elevation MI. This type of infarction was previously called a "transmural" MI, but newer terminology is now used, so it is called "STEMI".

As we know, most patients with this disease process have damage through all layers of the myocardium. With a STEMI, patients will have both ST elevation in select leads and positive (or abnormal) cardiac marker lab results.

There is a second type of acute infarct which is now called a "Non ST elevation MI" (NSTEMI). This patient is also having a myocardial infarction, but it may not be through all layers of the myocardium. This clinical syndrome was previously called "non transmural MI" or "subendocardial MI." In this setting, patients will also have positive cardiac lab results, but they will not show ST elevation.



The illustration on the left depicts a NSTEMI. Note the cross section of the ventricle from the epicardium to the endocardium and an area of non-transmural necrosis. The illustration on the right depicts a cross section of the ventricle with transmural damage (all layers) resulting in a STEMI.

Used with permission from Smart Med Ed.

Pathophysiology

The Non ST elevation MI (NSTEMI) is most often the result of reduced myocardial perfusion that results from coronary artery narrowing. The narrowing is usually caused by a nonocclusive thrombus that developed on a disrupted atherosclerotic plaque. Microembolization of platelet aggregates and components of the disrupted plaque are believed to be responsible for the release of myocardial cardiac lab markers (i.e. elevation of CK, CK-MB, Troponin I) in many of these patients.

ECG Abnormalities of a Non ST Elevation MI

The NSTEMI does not have ST elevation on the 12 lead ECG. Instead, they have **ST-T wave changes similar to the patient with transient ischemia**. We see ST segment depression and/or T wave inversion on the 12 lead ECG. The ST segment depression and/or flipped T waves are sometimes seen in "regional" areas (example: T wave inversion seen in Leads II, III and aVF) or they may be detected in "global" areas (example: T wave inversion seen in inferior, anterior and lateral leads).

Another ECG difference in this patient population is the absence of abnormal Q waves along with normal R waves. The NSTEMI patient does not lose their R wave voltage and does not develop Q waves on the ECG.

Test Yourself:

A person with a NSTEMI will have ST – T wave abnormalities and positive cardiac marker lab results.

- A. True- Correct!
- B. False

A person with a NSTEMI will benefit from an IV thrombolytic.

- A. True
- B. False- Correct!

Summary of ECG Changes with NSTEMI

- Regional or Global ST segment depression and/or T wave inversion
- No abnormal Q waves
- No loss of R wave voltage
- Elevated cardiac marker labs (CK-MB, Troponin I)

Test Yourself:

A person with a NSTEMI will eventually develop abnormal Q waves reflecting an old or chronic MI.

- A. True- Incorrect! STEMI patients do not typically develop Q waves. The formations of Q waves are in conjunction with STEMI patients.
- B. False- Correct!

Treatment Modalities for NSTEMI

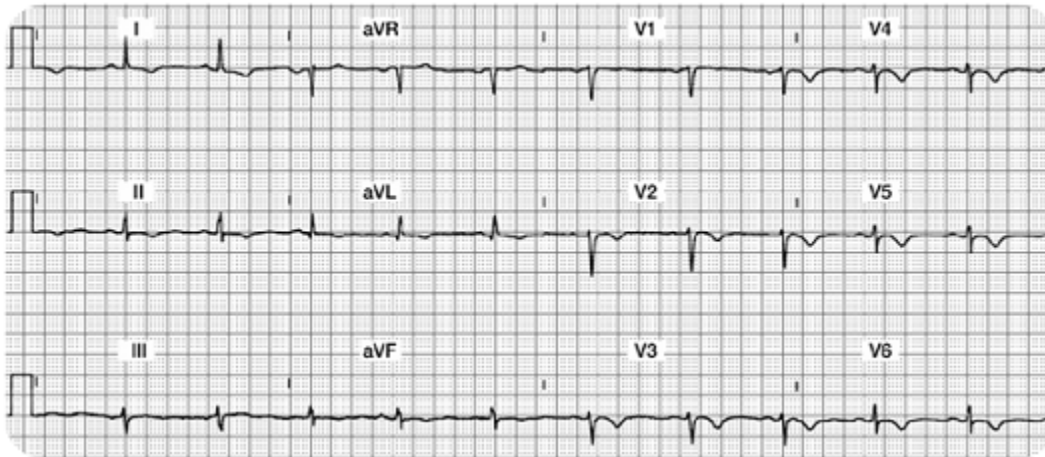
Studies have shown that thrombolytic therapy is of little benefit in the NSTEMI patient. According to the American College of Cardiology, treatment guidelines have been inconsistently implemented, resulting in inconsistent medical practices for the NSTEMI patient. Nurses must be knowledgeable in understanding how the treatment guidelines differ between the STEMI and NSTEMI patient populations.

Treatment priorities for the NSTEMI patient should include:

- Prompt antiplatelet therapy. Aspirin is best, but clopidogrel will be given if patient is allergic to aspirin.
- Heparin or Low Molecular Weight Heparin may be used on a short term basis.
- Administer a platelet glycoprotein (GP) IIb-IIIa antagonist (in addition to heparin and aspirin). Examples of these drugs are: Abciximab (ReoPro), Eptifibatide (Integrilin) and Tirofiban (Aggrestat). This category of medication helps to inhibit platelet aggregation and have been shown lower death rates in the NSTEMI patient population.
- Beta blockers are initiated unless contraindicated.
- Add angiotension-converting enzyme (ACE) Inhibitors or angiotension-receptor blocker (ARB) if patient has high blood pressure, signs of heart failure, diabetes, or abnormal ejection fraction.
- Cardiac catheterization is indicated if patient is unstable, but in general is not indicated.
- At discharge, statins should be added to the regimen.

Case Study 4

Mr. H. has a history of COPD and chronic renal insufficiency requiring hemodialysis. He puts on his call light complaining of chest, back, and arm pain. You obtain a 12 lead ECG.



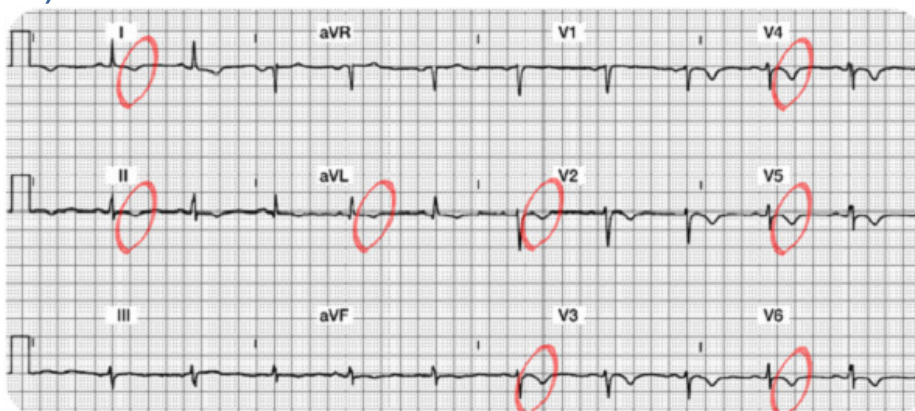Case Study Lead Worksheet

Your 12 Lead Worksheet:

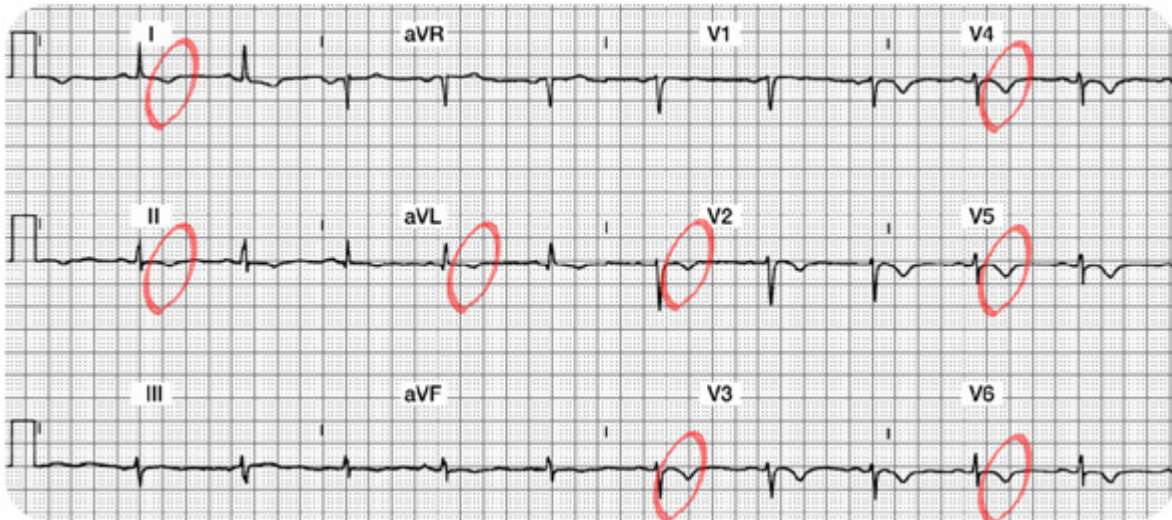
1. Summary of the Lateral Leads (I, aVL, V5 and V6):
2. Summary of the Inferior Leads (II, III, aVF):
3. Summary of the Anterior Leads (V1, V2, V3, V4):
4. Interpretation:
5. Which coronary artery is probably occluded?
6. What bedside lead should you select to monitor this patient?
7. What are your nursing priorities?

Case Study 4 Lead Worksheet Answers

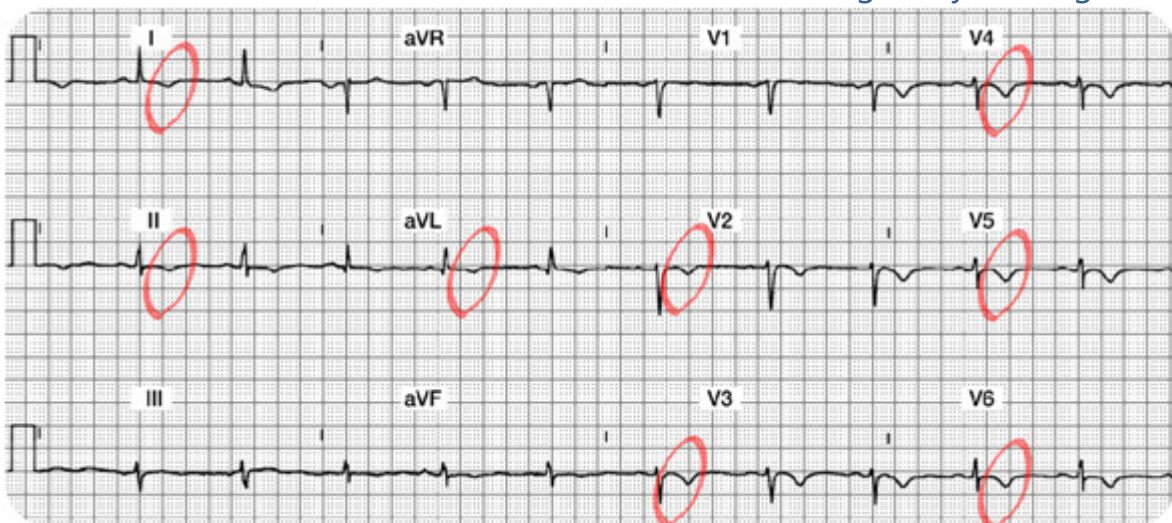
1. **Summary of the Lateral Leads (I, aVL, V5 and V6):** In Lead I, there is a normal Q and R wave. The ST segment is slightly depressed and the T wave is inverted. In aVL, the Q, R and ST segments are normal, but the T wave is inverted. V5 and V6 have R waves (a bit small, but present nonetheless). Both leads have T wave inversion.



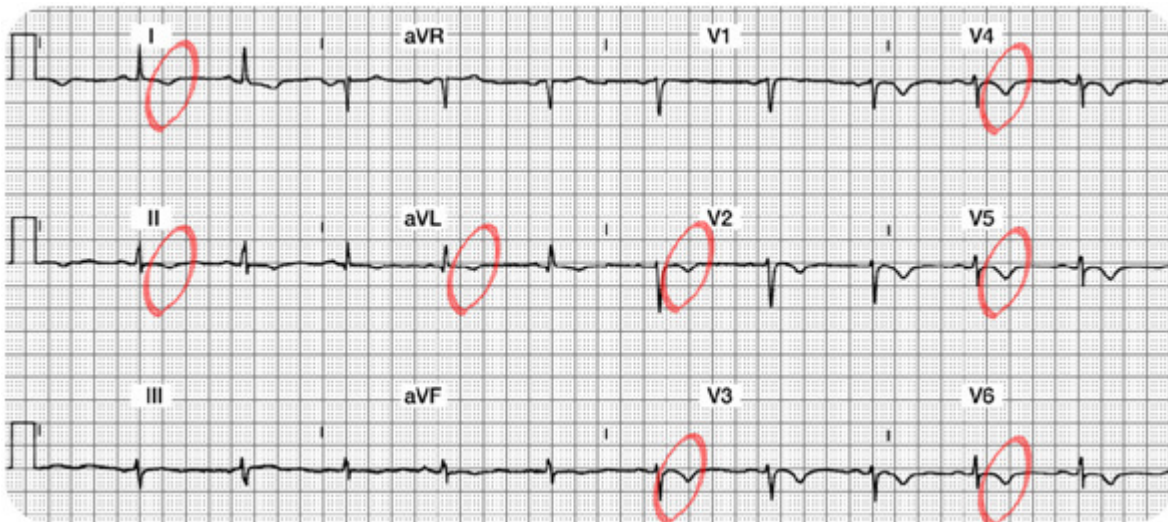
2. **Summary of the Inferior Leads (II, III, aVF):** All three leads are normal EXCEPT they have inverted T waves.
3. **Summary of the Anterior Leads (V1, V2, V3, V4):** V1 is normal. V2-V4 have no abnormal Q waves, R waves (a bit small and not really "progressing" as planned, but all 3 leads have T wave inversion).



4. **Interpretation:** Diffuse ischemia versus a Non-ST elevation MI (STEMI). **How do you diagnose ischemia versus NSTEMI?** Look at the cardiac marker labs. If they are positive, this is a NSTEMI. If they are negative (and especially if these T wave inversions are transient), it is ischemia. This is tricky as both ischemia and NSTEMI look alike. The lab results will guide your diagnosis.

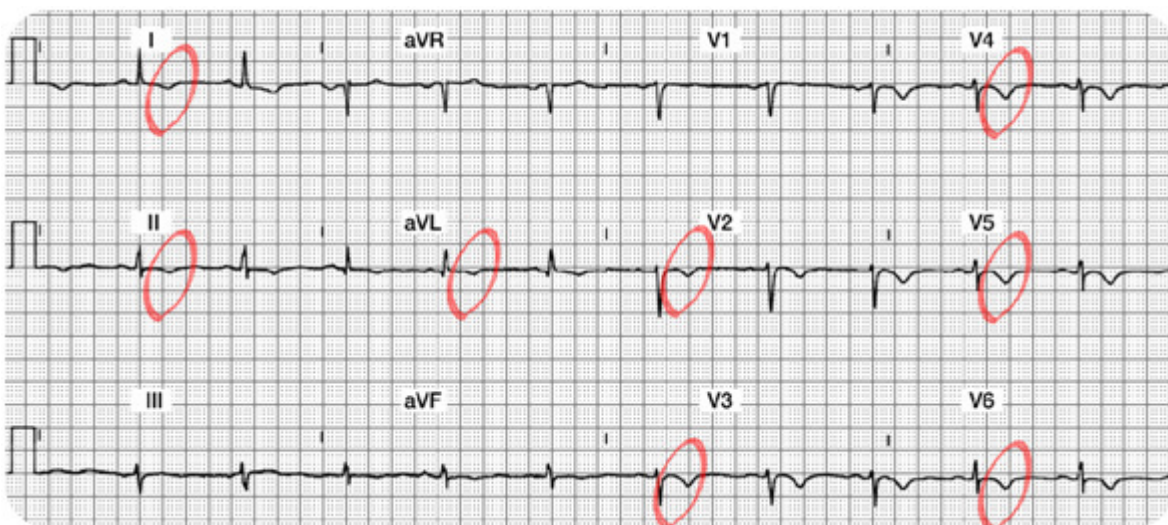


5. Which coronary artery is probably occluded? Not easy to predict as changes are diffuse and found in many leads.
6. What bedside lead should you select to monitor this patient? A combination of Lead II and V1 should cover most potential events.



7. What are your nursing priorities?

1. Relieve chest pain by decreasing myocardial oxygen consumption (e.g. rest) and increase oxygen supply (e.g. oxygen, nitrates, morphine, etc.).
2. Closely monitor serum cardiac marker lab results. If the markers are negative, the T wave inversion is likely to be from ischemia. If the markers are positive for damage, these T waves are likely a clue that this patient is having a NSTEMI. Remember that NSTEMI patients have not been shown to benefit from thrombolytic therapy. Treatment for NSTEMI will include aspirin, heparin, and possibly a IIb/IIIa platelet inhibitor.



Conclusion

Rapid assessment and treatment of acute myocardial infarction is key for initiation of appropriate therapy and preserving myocardial tissue. The module provides the nurse caring for the patient with a systematic system to examine the 12-lead ECG to determine acute or chronic changes.

The module has focused on identification and management of acute ischemia, injury, and infarction with an emphasis on STEMI patterns to the inferior, anterior, and lateral surfaces of the heart. Infarct types were correlated to the coronary artery blood supply with an understanding of potential complications resulting from each STEMI infarct. Non-ST elevation myocardial infarction (NSTEMI) patterns and treatments were also reviewed. Due to the complexity of this material, the learner is encouraged to routinely practice the knowledge learned in this module.

References

AHRQ, 2011 Acute myocardial infarction: median time from hospital arrival to primary PCI in acute myocardial infarction (AMI) patients with ST-segment elevation or LBBB on the ECG performed closest to hospital arrival time. Retrieved July 15, 2011 from <http://www.qualitymeasures.ahrq.gov/content.aspx?id=27393>

American Heart Association

(2007). 2007 Statistical Fact Sheet: American Heart Association.

http://www.americanheart.org/downloadable/heart/1166711577754HS_StatsInsideText.pdf

Antman EM, Anbe DT, Armstrong PW, Bates ER, Green LA, Hand M, et al. (2004). ACC/AHA guidelines for the management of patients with ST-elevation myocardial infarction. American College of Cardiology and American Heart Association Task Force on Practice Guidelines. *Circulation*. 110(5): 588-636.

Bavry AA, Kumbhani DJ, Quiroz R, Ramchandani SR, Kenchaiah S, Antman EM. (2004). *Am J Cardiol*. 2004. Invasive therapy along with glycoprotein IIb/IIIa inhibitors and intracoronary stents improves survival in non-ST-segment elevation acute coronary syndromes: a meta-analysis and review of the literature. 1;93(7):830-5.

Conover, M. (2003). *Understanding Electrocardiography*. 8th ed. St. Louis, Mosby.

Cummings, R.O. (Ed.) (2002) *Advanced cardiac life support provider manual*. Dallas: American Heart Association.

Dubin, D. (2000). *Rapid interpretation of EKG's*. (6th ed.). Tampa, FL: Cover Publishing Company.

Hazinski, M.F., Cummings, R.O. & Field, J.M. (2004). *Handbook of Emergency Cardiovascular Care for Healthcare Providers*. American Heart Association.

Medline. (2011). Definition of chest pain. Retrieved August 10, 2011 from <http://www.nlm.nih.gov/medlineplus/ency/article/003079.htm>.

National Heart, Lung and Blood Institute, 2011. Acute MI Statistics. Retrieved on July 16, 2011 from <http://www.nhlbi.nih.gov/health/>.

Purdie, R. B. & Earnest, S. (1997). *Pure practice for 12-lead ECGs: A practice workbook*. St. Louis, MO: Mosby.

Ryan TJ, Antman EM, Brooks NH, Califf RM, Hillis LD, Hiratzka LF, et al. (1999). 1999 update: ACC/AHA

guidelines for the management of patients with acute myocardial infarction. A report of the American College of Cardiology/American Heart Association Task Force on Practice Guidelines. J Am Coll Cardio, 34(3), 890-911.

Springhouse. (2002). Mastering ACLS. Philadelphia: Lippincott, Williams & Wilkins.

Swearingen, P.L. & Keen, J.H. (Eds). (2001). Manual of critical care nursing: Nursing interventions and collaborative management. St. Louis, MO: Mosby.

Topol, E.J. (Ed). (2001). Acute coronary syndromes (2nd ed.). New York: Marcel Dekker.

Wagner, G.S. & Marriott, H.J.L. (2001). Marriott's practical electrocardiography. (10th ed.). Philadelphia: Lippincott, Williams & Wilkins.

At the time this course was constructed all URL's in the reference list were current and accessible. rn.com. is committed to providing healthcare professionals with the most up to date information available.

© Copyright 2003, AMN Healthcare, Inc.

IMPORTANT INFORMATION:

This publication is intended solely for the educational use of healthcare professionals taking this course from RN.com in accordance with RN.com [terms of use](#) . The guidance provided in this publication is general in nature, and is not designed to address any specific situation. As always, in assessing and responding to specific patient care situations, healthcare professionals must use their judgment, as well as follow the policies of their organization and any applicable law. Organizations using this publication as a part of their own educational program should review the contents of this publication to ensure accuracy and consistency with their own standards and protocols. The contents of this publication are the copyrighted property of RN.com and may not be reproduced or distributed without written permission from RN.com.

Healthcare providers, hospitals and healthcare organizations that use this publication agree to hold harmless and fully indemnify RN.com, including its parents, subsidiaries, affiliates, officers, directors, and employees, from any and all liability allegedly arising from or relating in any way to the use of the information or products discussed in this publication.