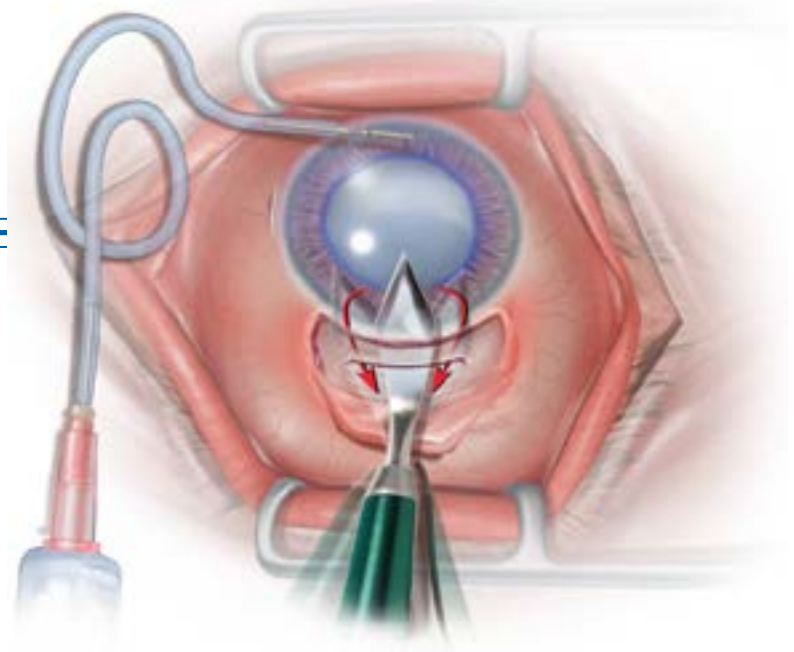


# Manual Small Incision Cataract Surgery

*A novel strategy for cataract removal*



The material in this booklet is based on the experience of:

Ravi Thomas, M.D.  
Prashant Garg, M.D.  
*L.V. Prasad Eye Institute*  
*Hyderabad, India*

Edited by:

Eugene M. Helveston, M.D.  
D. Hunter Cherwek, M.D.

Technical Support:  
Lynda M. Smallwood

Artist:  
Sharon Teal

January 2006

ORBIS International  
520 8th Avenue, 11th floor  
New York, New York 10018

PLEASE SEE ADDITIONAL TECHNIQUES, LECTURES, AND  
INSTRUCTIONAL VIDEOS OF SMALL INCISION CATARACT SURGERY ON  
CYBERSIGHT:

[WWW.CYBERSIGHT.ORG](http://WWW.CYBERSIGHT.ORG)

cybersight

IT IS PREFERRABLE TO BEGIN BY DOING THE PROCEDURE EXACTLY AS SHOWN.  
MODIFICATIONS ARE POSSIBLE AND SHOULD COME LATER

# Manual Small Incision Cataract Surgery “MSICS”

## Introduction

Cataract surgery has undergone significant changes beginning with the abandonment of intracapsular surgery, and continuing with the advent of intraocular lenses, and continuing variations in extracapsular lens removal. Extracapsular cataract surgery employing a 10 mm incision at the limbus and requiring wound closure with sutures is considered a "fall back" technique that is easier to perform but has limitations. Phacoemulsification is used by most surgeons in developed countries and enables the most elegant surgery but at a high cost. A third technique, **manual small incision cataract surgery (MSICS)**, retains most of the advantages of "phaco" but can be delivered at lower cost and is more readily applied in high volume programs. In the following, "Phaco" and **manual small incision cataract surgery** are compared and then a step-by-step description of the **MSICS** is presented.

### The goal of modern cataract surgery:

- Rapid patient mobilization
- Minimal induced astigmatism
- Early visual rehabilitation

### Two techniques which meet these criteria:

#### 1. Phacoemulsification

- Pro
  - 2.8-3.5 mm incision - sutureless
  - can implant foldable lens
  - fast - can be done  $\pm$  10 minutes
- Con
  - difficult with hard nucleus
  - difficult with hypermature cataract
  - expensive, high maintenance equipment required
  - expensive disposables required
  - many countries do not do foldable lenses even with phaco; would seem a waste to do surgery with 3 mm and then enlarge to 6 mm

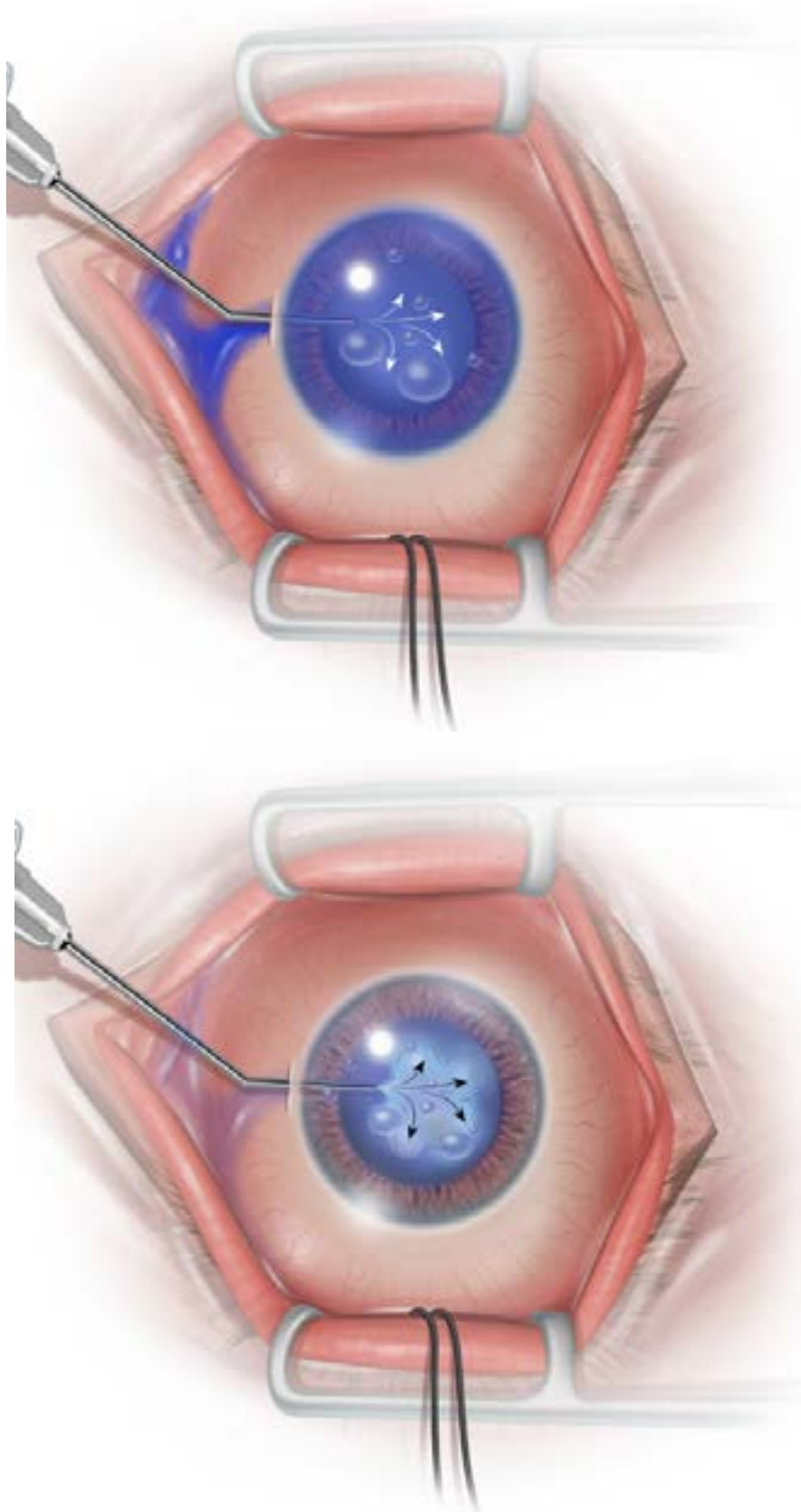
#### 2. Manual small incision cataract surgery

- Pro
  - small incision 5.5 mm - sutureless
  - implant rigid lens - "low cost"
  - fast - can be done  $\pm$  6 minutes
  - faster patient "turn around" for "high volume"
  - low cost equipment and "disposables"
  - successful in more than 99% of cases
- Con
  - larger incision than "phaco"
  - must use rigid lens

There are MSICS techniques that allow removal through a 3.5 mm incision





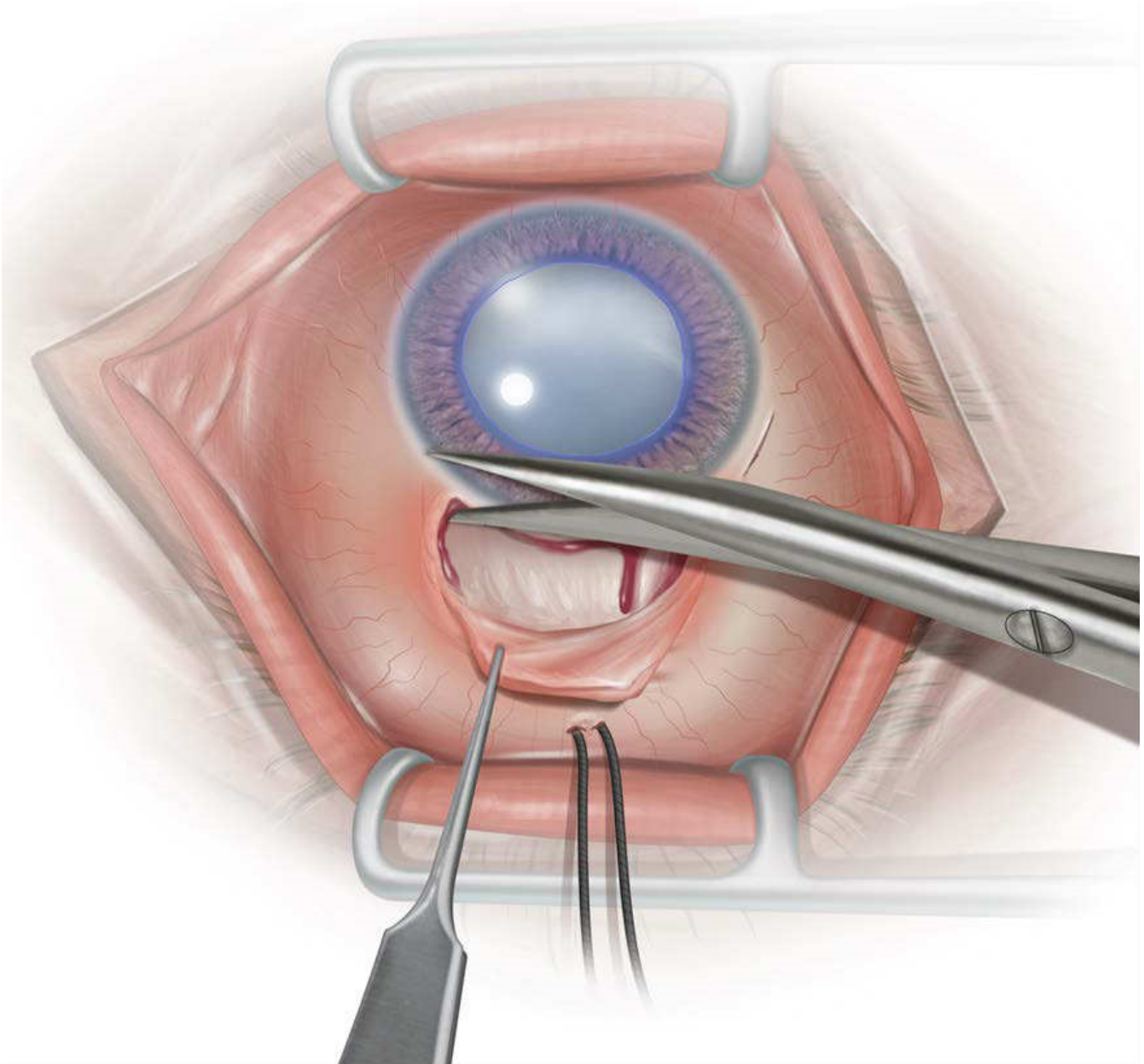


### **Step 3: Forming the AC with Viscaïn/Viscoelastic**

Viscoelastic material (for example, 2% methylcellulose) is injected through the paracentesis to form the anterior chamber and protect the corneal endothelium.







### **Step 5: Conjunctival Peritomy**

The conjunctiva and Tenon's capsule is dissected from the superior limbus for approximately 4 clock hours and reflected to expose bare sclera. Any bleeding vessels on the sclera are cauterized with wetfield cautery, if available, so that there is a relatively dry field for later wound construction.

.....

.....

.....

.....

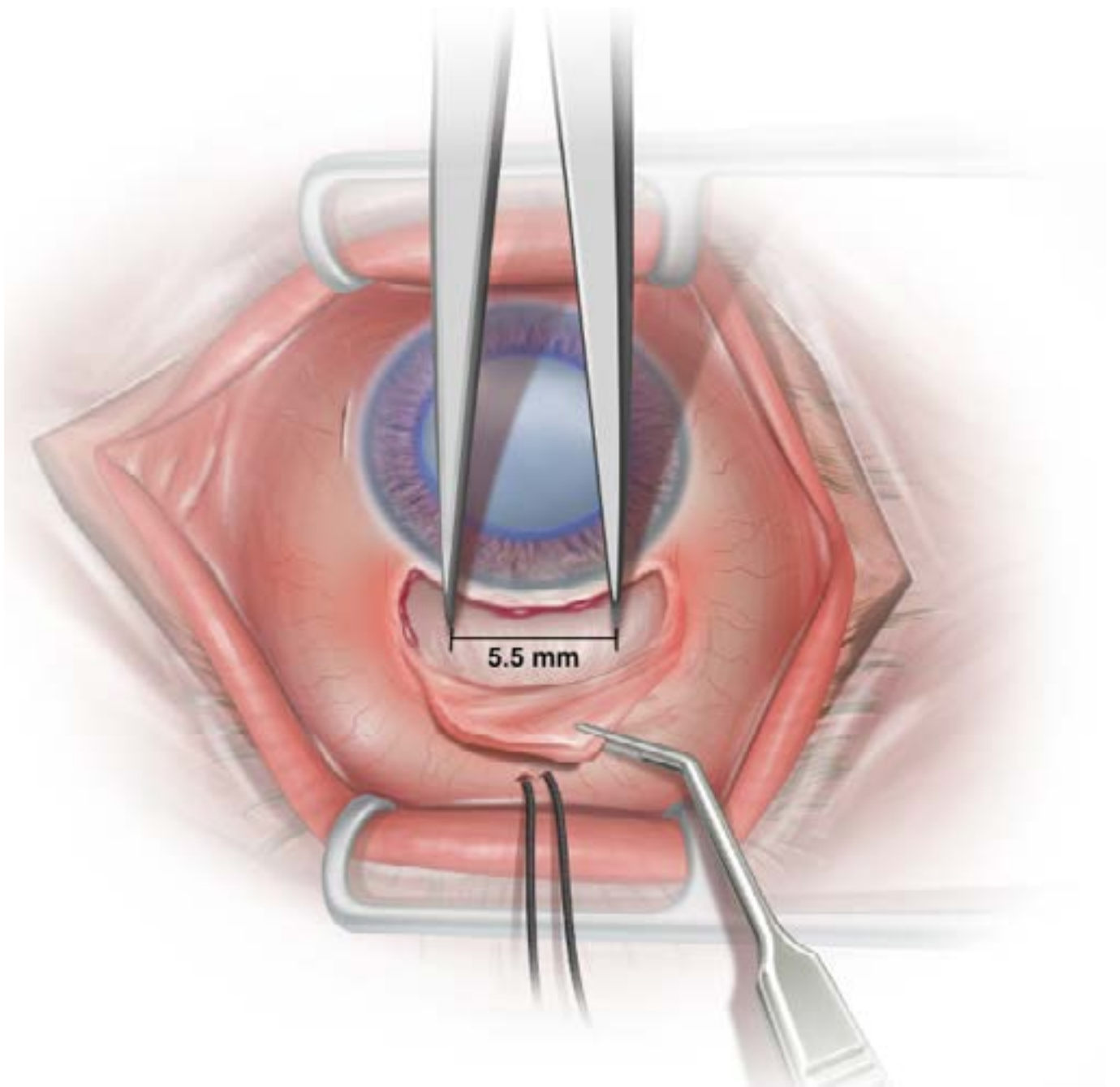
.....

.....

.....

.....

.....



### **Step 6: Wound Construction**

The 5.5 mm track for the future scleral wound is measured 1mm behind the limbus and the endpoints of the wound are marked by indenting the sclera using surgical calipers.

.....

.....

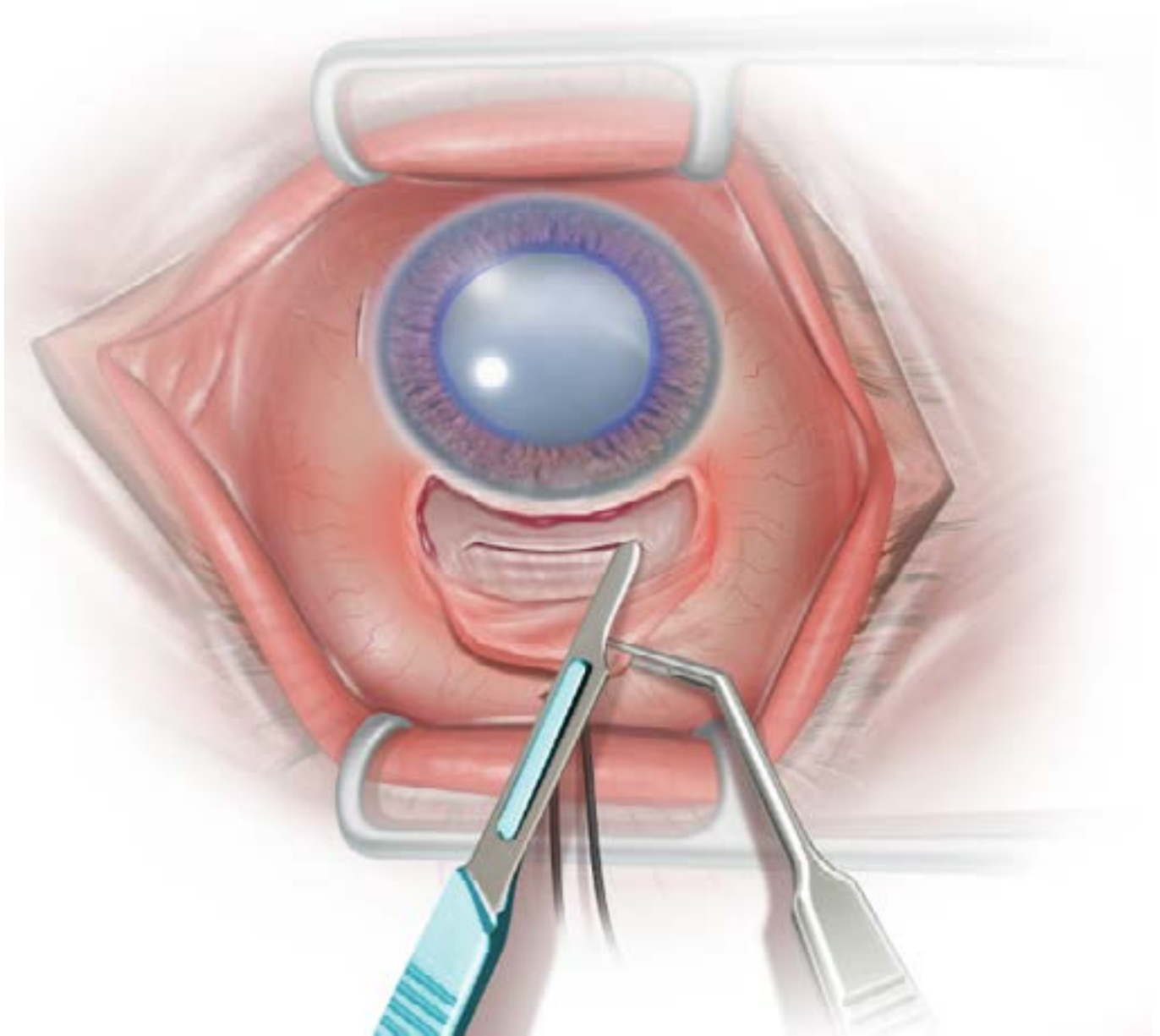
.....

.....

.....

.....

.....



### Step 7: Wound Construction

Using a 15 or similar blade a straight, approximately 1/2 thickness, scleral groove is made with two backward extensions at each edge.

*Note:* the two backward cuts of 1-1.5mm (radial to the limbus) are made from each end of the wound.

.....

.....

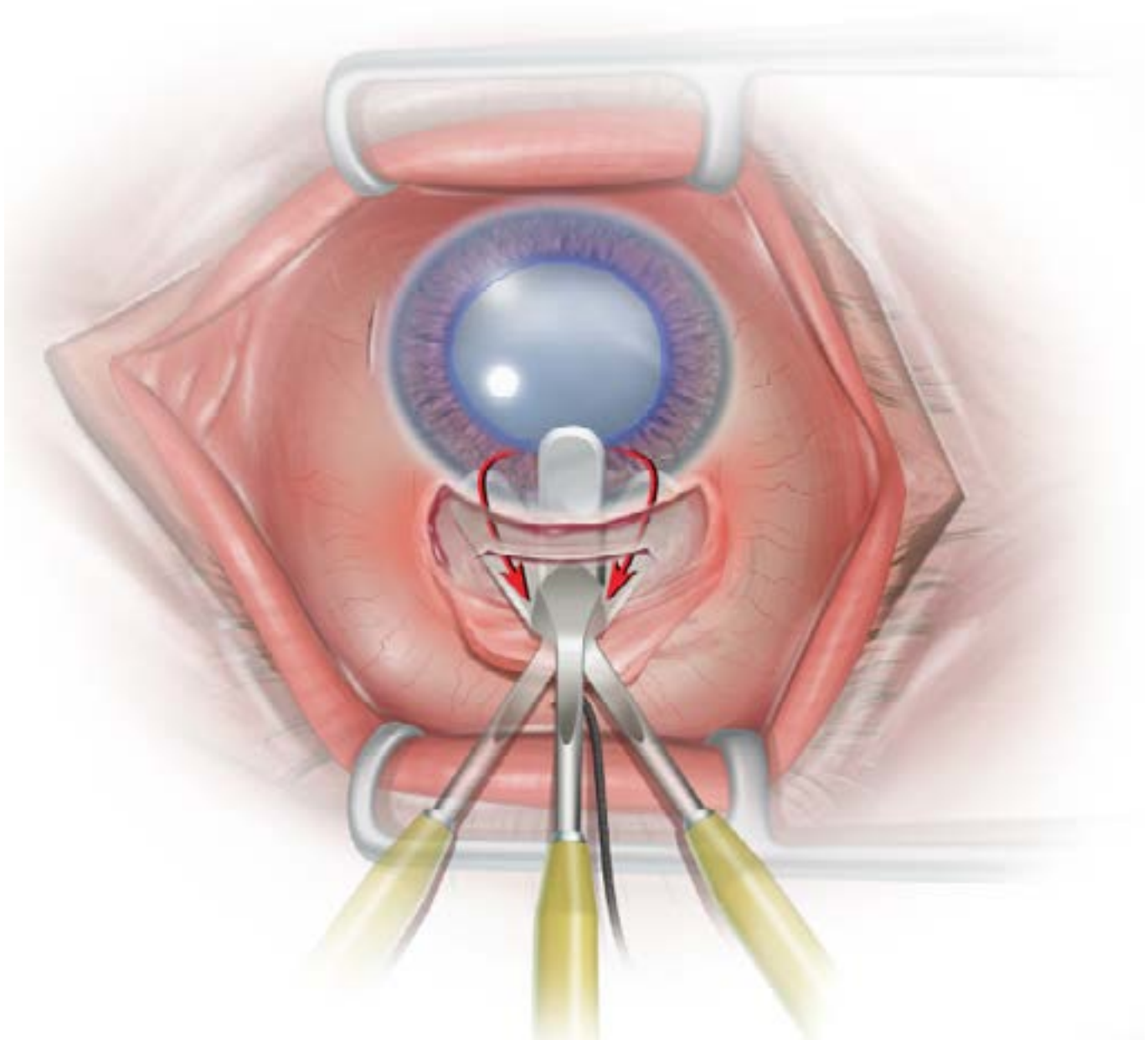
.....

.....

.....

.....

.....



### Step 8: Wound Construction

A scleral tunnel is then constructed using an angled crescent blade. The incision extends approximately 2-2.5mm into the cornea. The dissection is carried out towards the limbus on both sides to create a funnel-shaped "pocket". The crescent blade is then angled to cut backwards to incorporate the backward cuts into the pocket.

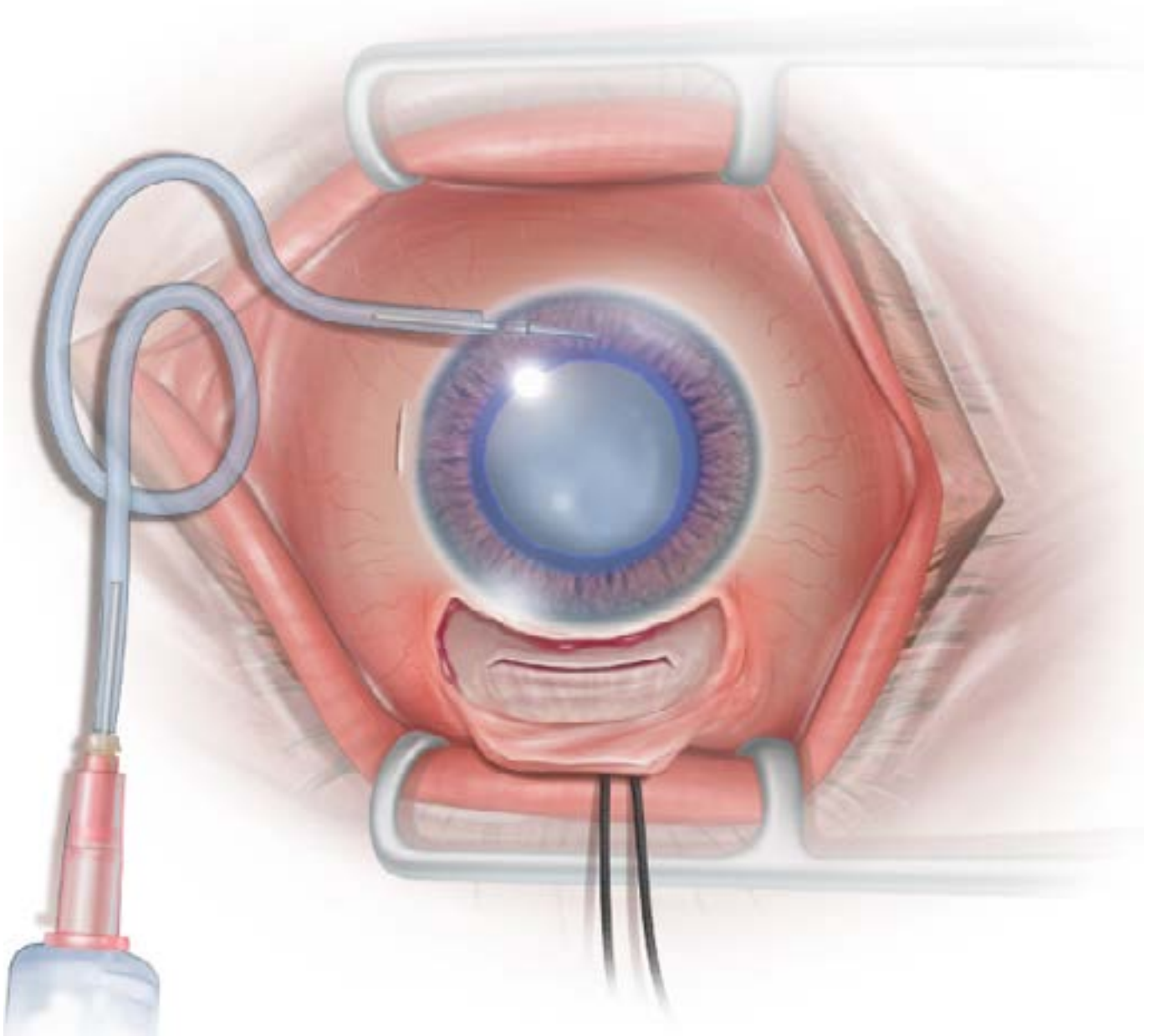
.....

.....

.....

.....

.....



### **Step 9: Anterior Chamber Maintainer (ACM)**

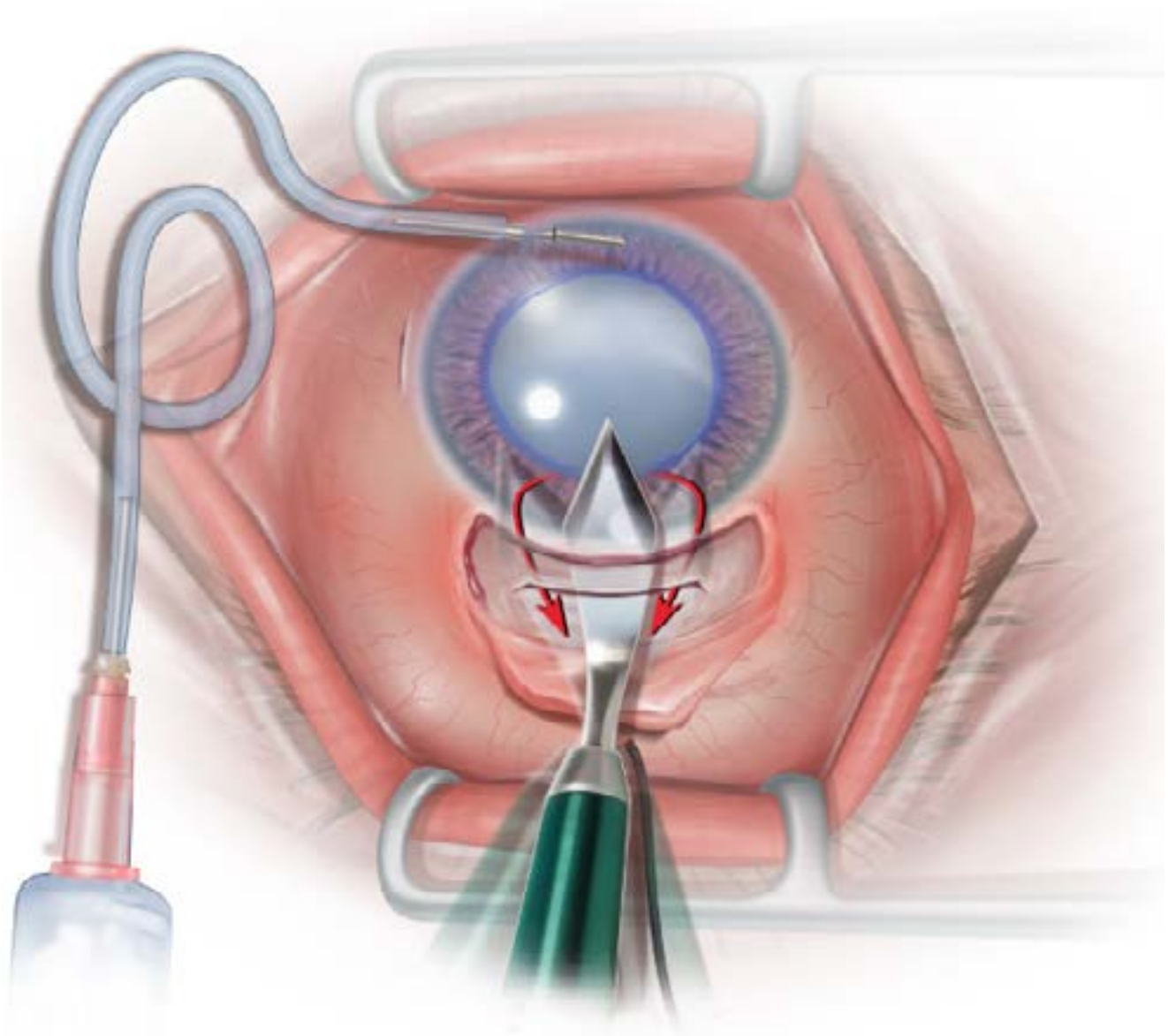
The myringotomy or similar blade is used to make a paracentesis at the 6 o'clock position.

The paracentesis is made parallel to the limbus, but can be made radial.

The intrastromal length of the incision is about 1.5 mm.

A flat corneal AC maintainer (Visitech Instruments; catalogue number: 58514) connected to a bottle of irrigating fluid is introduced through this incision. No stay sutures are needed.

*Note:* This can be the first step of surgery. The CCC can be done with the chamber formed by the anterior chamber maintainer.



### Step 10: AC Entry

The anterior chamber is entered using the appropriate size keratome. The keratome is directed to include the dissected area that has been pre-formed with the crescent blade.

This means that the internal opening of the funnel is larger than the external opening (this configuration makes it much easier to deliver the nucleus, and retain a watertight wound without sutures. Any cutting is only done on the down stroke (i.e. into the AC).

All cuts are made on the “down stroke”. Do not cut on the upstroke.

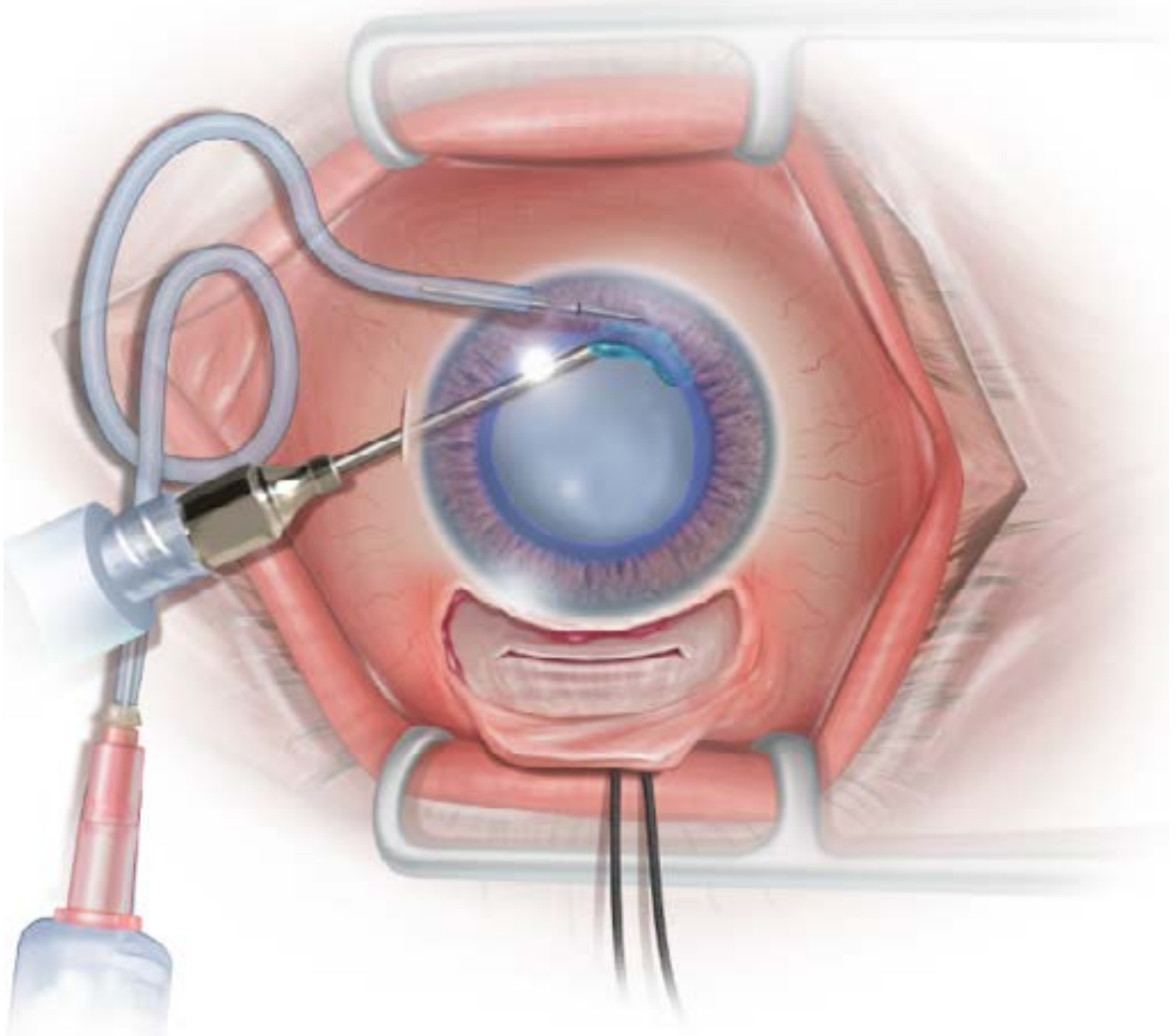
.....

.....

.....

.....

.....



### **Step 11: Hydrodissection**

An irrigating cannula is introduced through the paracentesis. The tip is placed just under the capsule at the 6.30 position; fluid will be seen perfusing under the capsule.

The cannula is extended about 1-2 mm under the capsule.

Gentle hydrodissection with a 1-2 cc syringe is performed until the upper pole of the nucleus prolapses. Please do not use a syringe with more than 2 cc volume in this step.

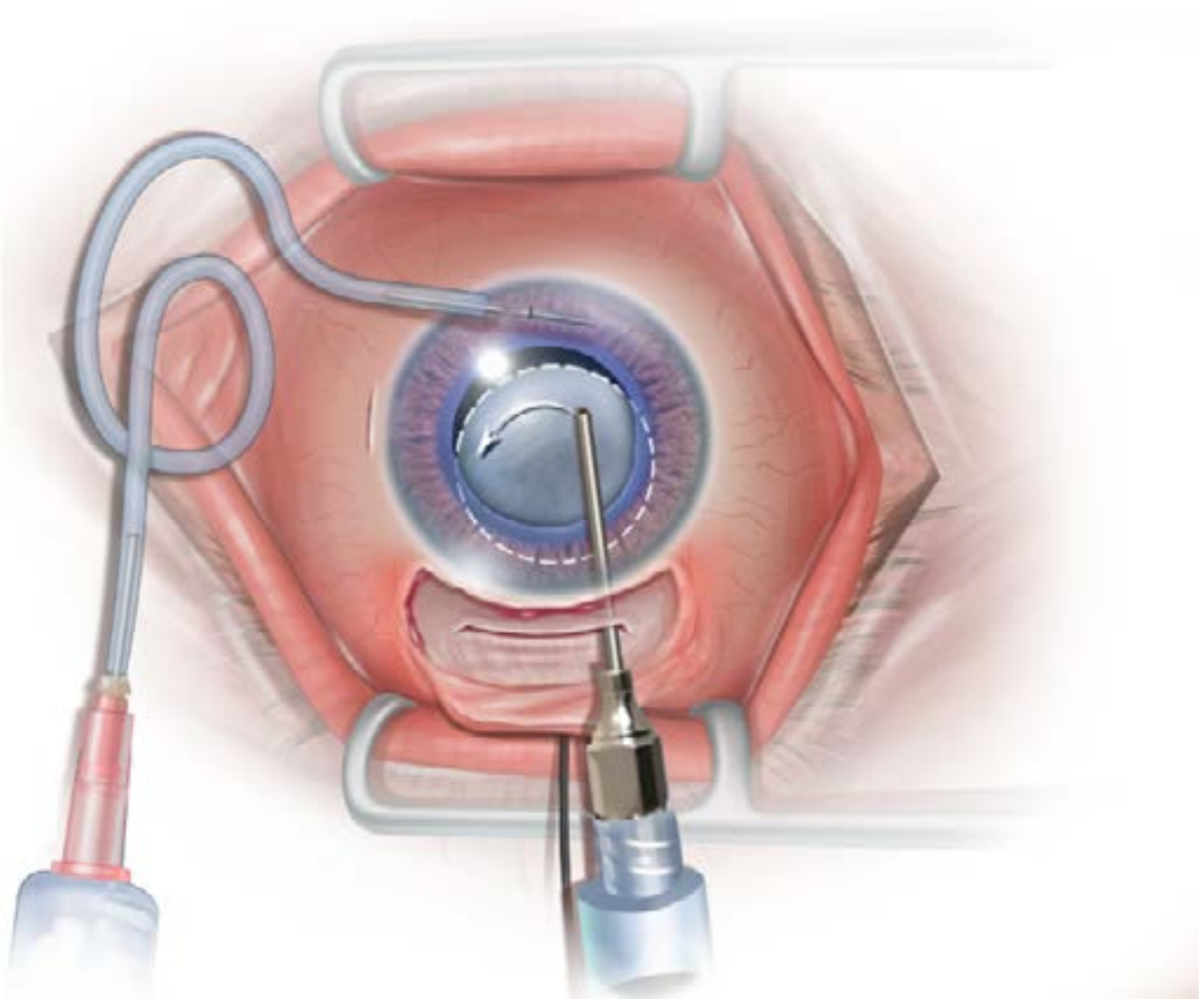
.....

.....

.....

.....

.....



### Step 12: “Freeing” the Nucleus

A cannula enters the anterior chamber from the left side of the wound and engages the equator of the prolapsed nucleus. It is now rotated to the right hand side of the wound. Rotating the nucleus in the bag now “frees” up the nucleus for delivery.

The nucleus freed from cortical material is shown above in 12A.

.....

.....

.....

.....

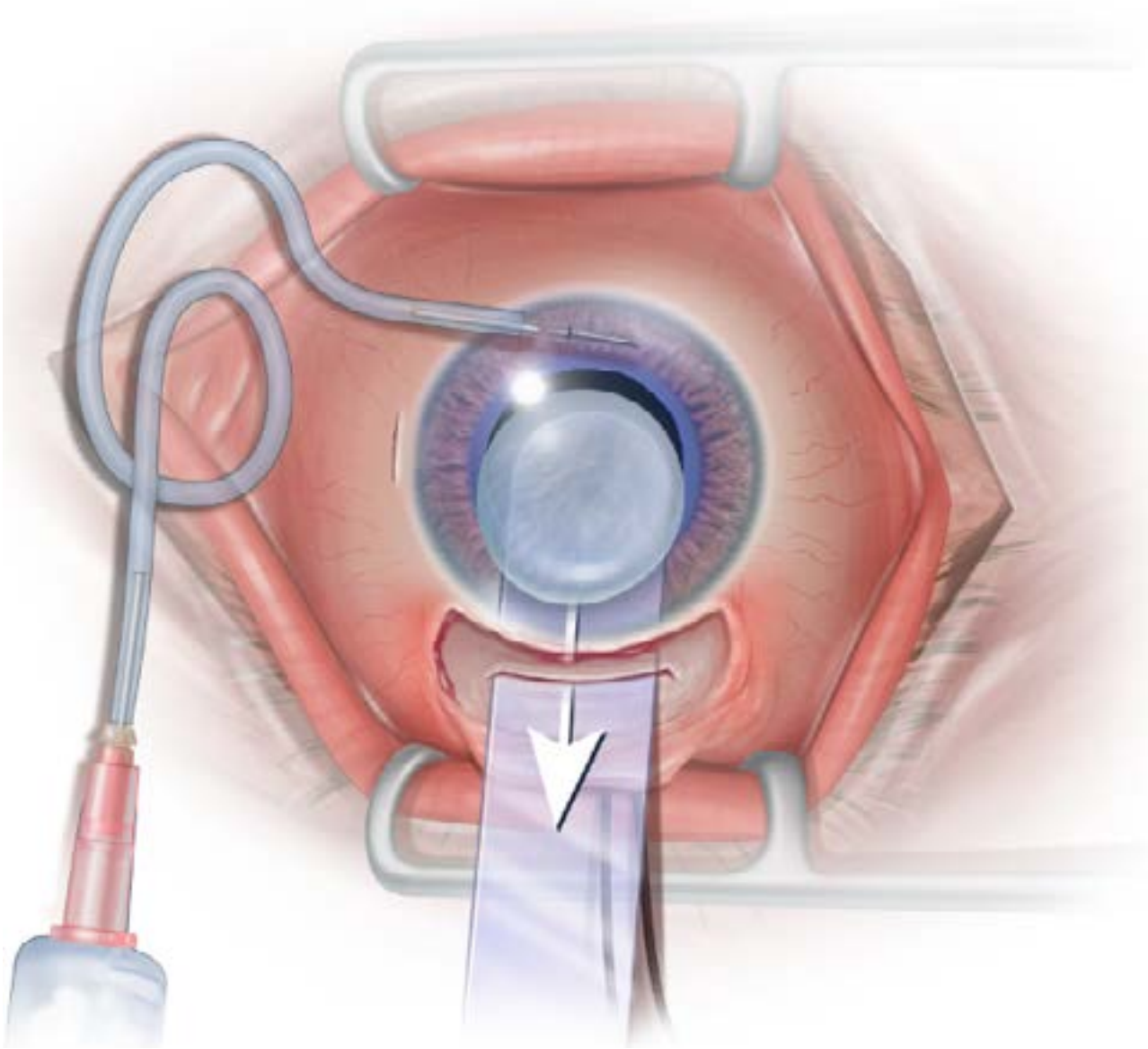
.....

.....

.....

.....





### **Step 13: Sheet's Lens Glide**

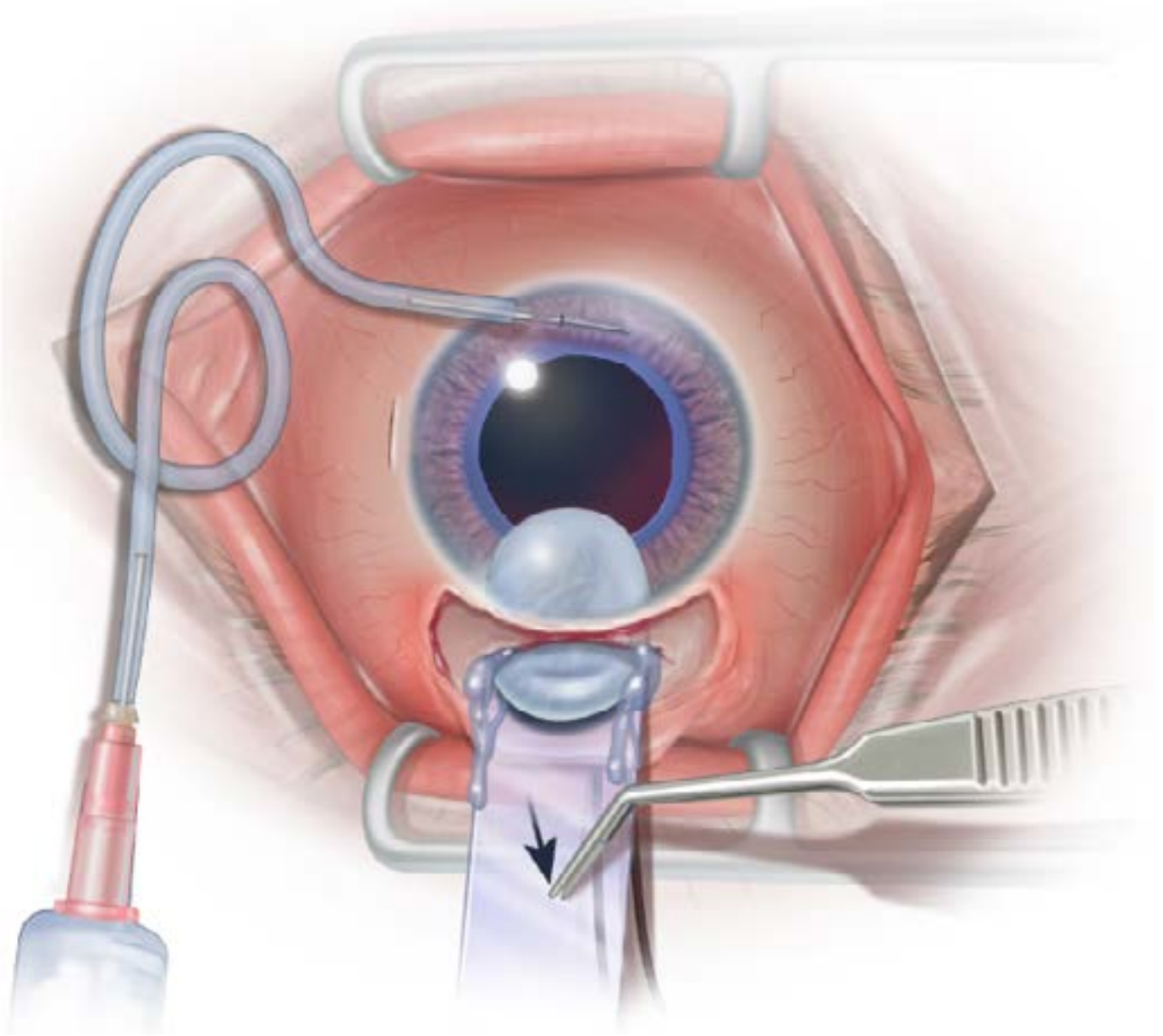
A Sheet's lens glide (BD-Visitec instruments: catalog number 581033) is then inserted between the nucleus and the posterior capsule. The glide is only to guide the nucleus through the wound. Do not insert more length than required to support the nucleus in the anterior chamber.

.....

.....

.....

.....



### Step 14: Nucleus Delivery

A McPherson forceps presses on the Sheet's glide as shown. This causes aqueous to leak and allows the nucleus to engage in the wound. Further pressure is exerted on the Sheet's glide posterior to the tunnel (14A). The nucleus is slowly expressed out of the wound by hydrodynamic expansion.

*Note:* Following nucleus engagement, subsequent pressure should not be in the anterior part of the tunnel. This will only cause further leakage of aqueous and prevent a tight seal. Without a tight seal, the nucleus will not be expressed.

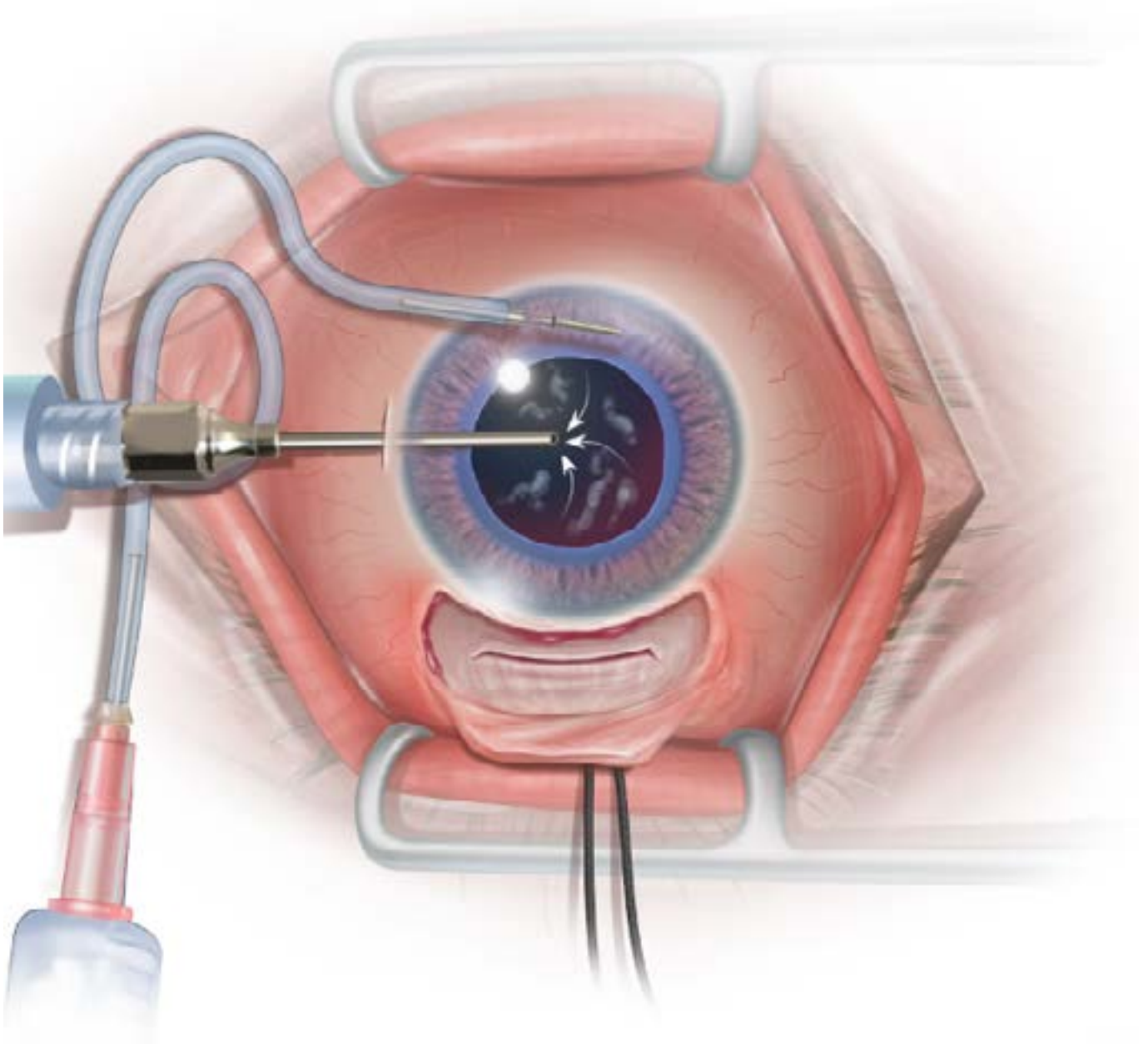
.....

.....

.....

.....

.....



### **Step 15: Cortex Removal**

Cortex extraction is safely performed with a single port aspirating cannula on a syringe, through the paracentesis, in the closed, well-maintained chamber provided by the ACM.

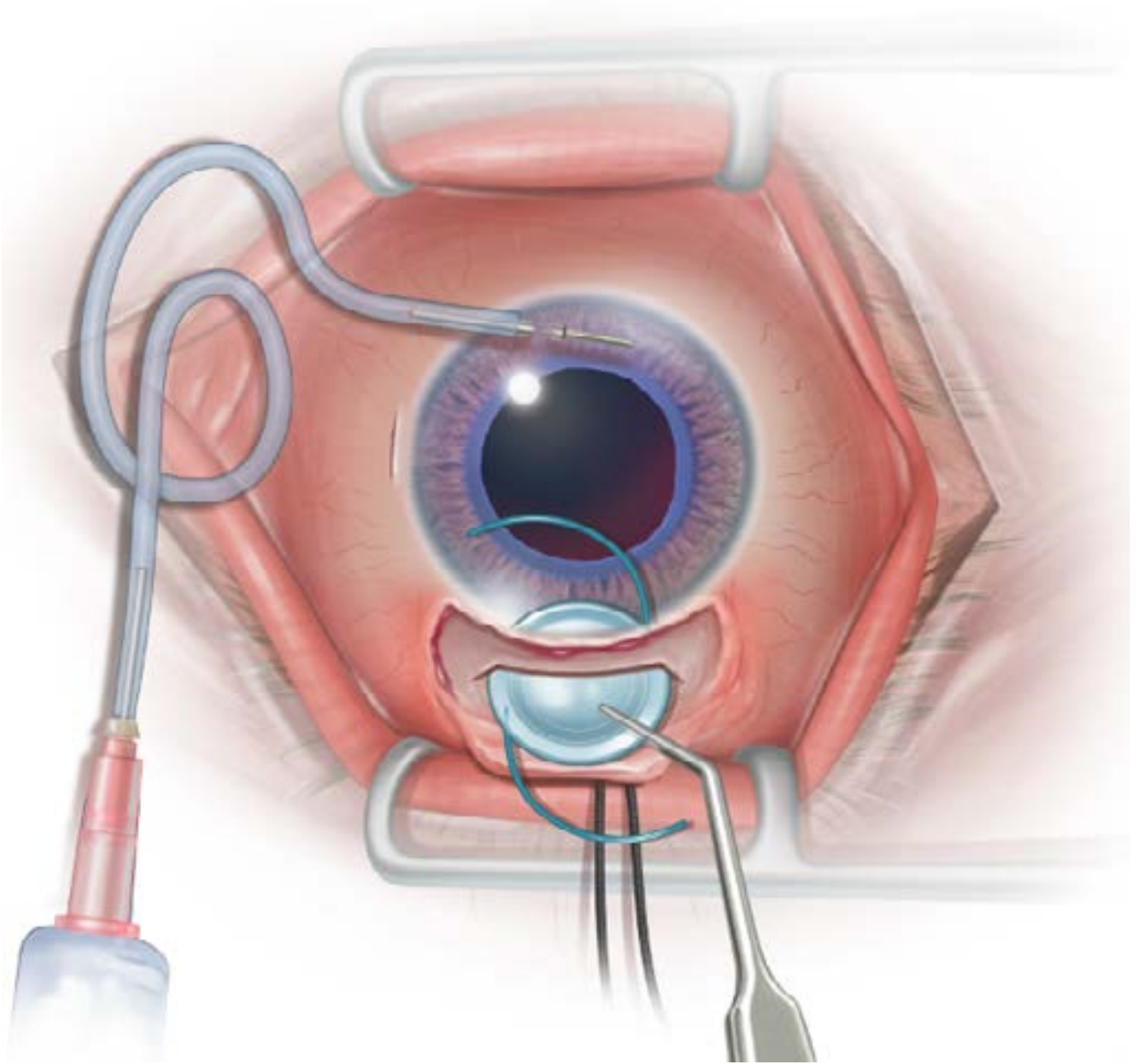
.....

.....

.....

.....

.....



### Step 16: IOL Insertion

A 6-6.5 mm rigid lens is inserted into the AC through the wound.

*Note:* the ACM is used to keep the AC deep and prevent tears in the posterior capsule. Alternatively, viscoelastic agents can be used as well, in which case the ACM is turned off.

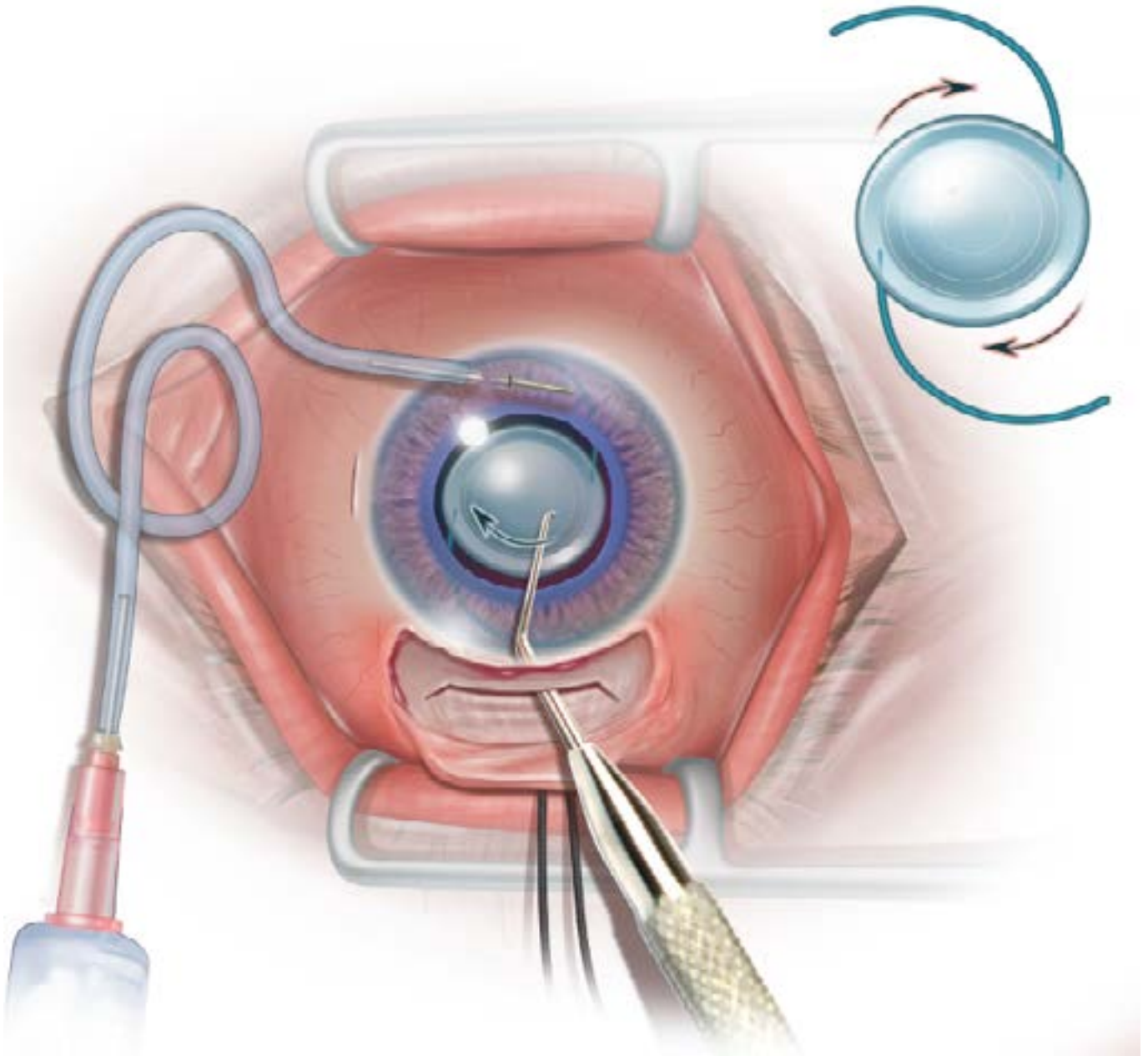
.....

.....

.....

.....

.....



### Step 17: IOL Implantation

The haptics of the IOL are dialed into the capsular bag in a clockwise direction. A Sinskey hook, or similar, is used for this.

.....

.....

.....

.....

.....

.....

.....

.....



# cybersight

Trypan blue can be injected into the anterior chamber under an air bubble for capsular staining in cases of a white cataract.

An anterior chamber maintainer with irrigating fluid can be used to maintain the anterior chamber in place of viscoelastic from the stage of the CCC.

Viscoelastic may be used to maintain the anterior chamber without the use of an anterior chamber maintainer and irrigating fluid.

A continuous curvilinear capsulorrhexis (CCC) may be performed either before or after wound construction.

The nucleus may be delivered without the use of a Sheet's lens guide. Sometimes a lens loupe can be used and at other times the lens is simply expressed.

Surgical access to the anterior chamber may be from the superior 12 o'clock position or temporally at the 9 o'clock position for the right eye and the 3 o'clock position for the left eye.

A variety of different techniques can be employed for nucleus prolapse.

Initially, please use the technique as described. Once you are comfortable, by all means make improvements. The authors would appreciate a note about these improvements, so as to improve their own technique.

Additional techniques, surgeries and webinars can be viewed in the Cybersight video library.

## Towards Achieving Small-Incision Cataract Surgery 99.8% of the Time

*Ravi Thomas, MD; Thomas Kuriakose, DNB; Ronnie George, DO*

**A surgical approach designed to reliably attain the modern goal of small incision cataract surgery 99.8 % of the time is described. Phacoemulsification as well as a manual small incision technique is utilised to achieve the desired outcome as often as possible and for all types of cataracts. The logic, and required surgical steps are described and illustrated. This surgical technique allows the advantages of small incision surgery to be reliably achieved. The method is flexible and allows decisions and steps to be modified depending on the skill and comfort zone of the individual surgeon.**

**Key Words:** Cataract surgery, small-incision, phacoemulsification, manual

Reprinted from: *Indian J Ophthalmol* 2000;48:145-51

---

Schell Eye Hospital, Christian Medical College, Vellore, India. Reprint requests to Dr. Ravi Thomas, Department of Ophthalmology, Schell Eye Hospital, Christian Medical College, Ami Road, Vellore - 632 001, India. E-mail: <ravi@cmcvellore.ac.in>  
Manuscript received: 26.05.1999; Revision accepted: 29.11.1999

---

Phacoemulsification allows cataract surgery through a small incision that is stable and usually sutureless. The resultant advantage of rapid patient mobilisation and visual rehabilitation has established phaco-emulsification's deserved current popularity in cataract surgery. Manual small-incision techniques for cataract surgery are also available. However, while some manual techniques like phacosection<sup>1</sup> can be performed through smaller incisions, most manual methods require incisions larger than 5.5mm. The major advantage of phacoemulsification over manual techniques, therefore, is the ability to implant a foldable intraocular lens (IOL) through the smaller incision, with the attendant potential benefits. What, then, about the really hard, black or dark brown nucleus? Or the hypermature cataract? While such situations are not a trial for the very experienced phaco surgeon, others may balk at the thought of attempting phacoemulsification in such cases. However, even in such situations, a small sutureless incision is certainly a desirable goal. *But how do we achieve it? How do we shift the risk-benefit ratio in the patient's (and our) favour?* While we may all want to achieve the manufacturers' ideal of "100% phaco", unfortunately, there are instances when we have to convert from phacoemulsification to standard extracapsular surgery. While most average surgeons face this situation occasionally, even experts are all bound to face such scenarios at one time or another. Converting to a standard extracapsular results in a larger, more unstable wound than a planned extracapsular. Either way, it compromises the goal of rapid rehabilitation provided by a small, self-sealing incision; more so, perhaps, with a clear cornea approach.

How often does this happen? If an experienced surgeon had to convert 3.7% of the time<sup>2</sup> it might happen to the less experienced surgeon just a little more frequently. While the final vision in these



cases was reported to be "satisfactory", the resultant astigmatism, uncorrected visual acuity and delay in visual rehabilitation were not discussed.<sup>2</sup> *How do we obtain a small incision 100% of the time?* The truth is, we cannot. We can only provide a surgical approach designed to reliably (repeatably) achieve a small-incision surgery 99.8 % (more modestly 99.5%) of the time. This figure is based on our own unpublished experience. The approach can be tailored to the skills and comfort zone of the individual surgeon. Indeed there are cases where our comfort zone dictates a standard extracapsular, or even an intracapsular surgery.

To escape that fate and for the purposes of this article, we will assume that the surgeon can perform a phacoemulsification and a manual small-incision (MSI) technique. Whether one is used routinely in preference to the other is the individual surgeon's choice. While this approach is probably suitable for any manual technique, we will describe a (modified) technique that we are familiar with.<sup>3</sup> While some necessary details are provided, a minute description of the actual procedure of phacoemulsification or MSI, a detailed discussion of the relative merits of the two, or the individual surgeon's acceptance of the larger wound associated with the MSI is beyond the scope of this article.

## **Technique**

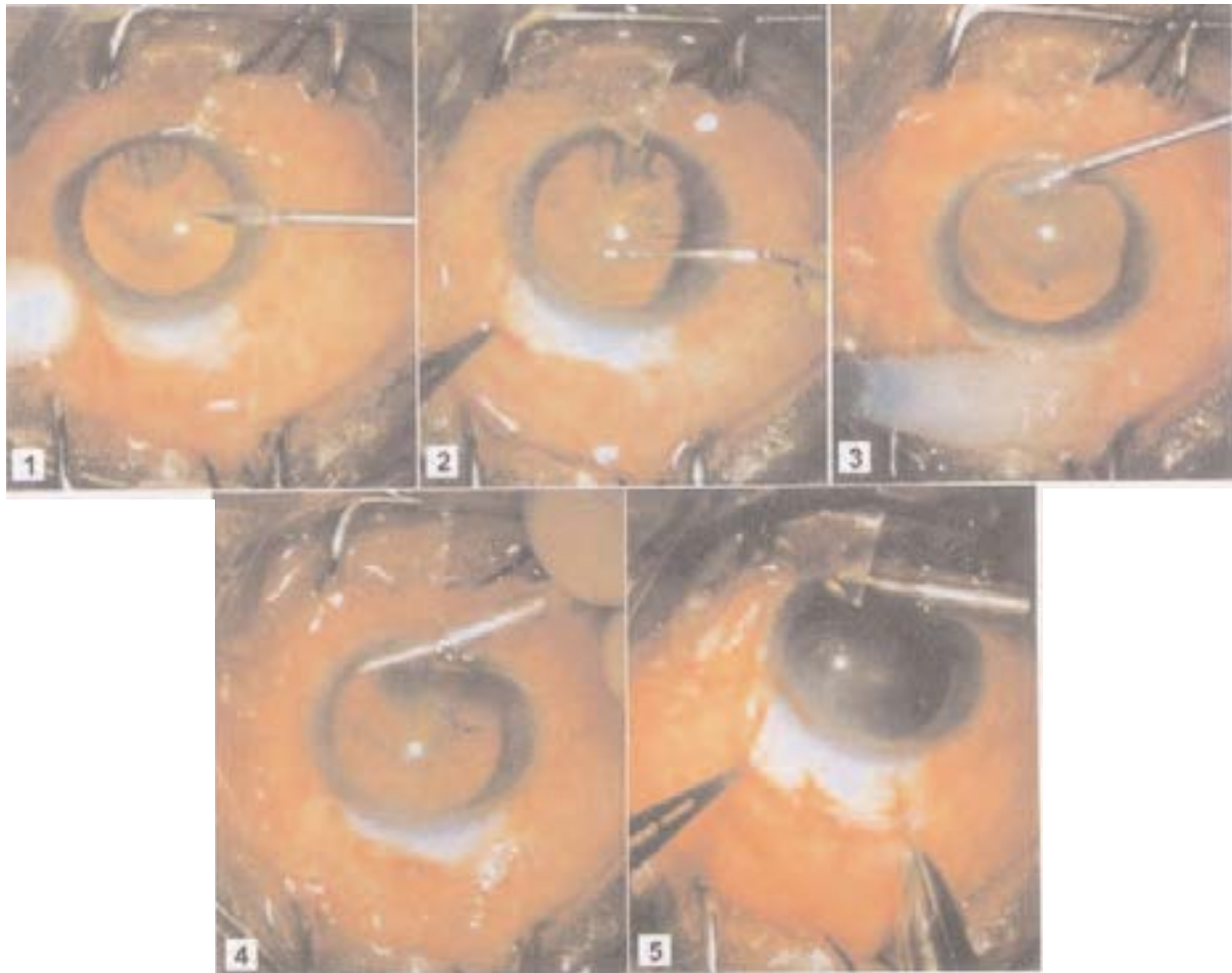
### **Step 1: Continuous curvilinear capsulorrhexis (CCC)**

For reasons explained later, this is the first step. A bevelled paracentesis incision is made with a myringotomy blade at 9.30 o'clock position (Figure 1). The globe can be steadied with a cotton-tipped applicator as shown, or by the surgeon's preferred technique. The chamber is deepened with 2% methylcellulose or viscoelastic. The CCC is performed through the paracentesis, using a bent capsulotomy needle (Figure 2). The size of the capsulotomy depends on the surgeon's "first choice" technique for the particular type of cataract. If the surgeon feels comfortable with phacoemulsification for that cataract, a 5mm CCC is acceptable. If for some reason an MSI is planned for that particular case, a larger, preferably 6-6.5mm CCC is desirable.

If the CCC is achieved, and the plan was phacoemulsification, we go ahead with it. If however, a CCC is not obtained, we have a choice. If the break in the CCC occurs superiorly, and the cataract is "not too hard", we may proceed with phacoemulsification. If the break in the CCC is inferior and the cataract is hard, we may elect to opt for a manual small incision. The choice depends on the individual surgeon and his comfort zone. This is one reason why the CCC, and not the incision, is the first step. There are other reasons, which we will talk about later.

### **Step 2: Anterior chamber maintainer (ACM)**

The myringotomy blade is used to make a paracentesis straddling the 6 o'clock position. The intrastromal length of the incision is about 1.5 mm (Figure 3). A flat corneal anterior chamber maintainer (Visitech Instruments Fl, USA; catalogue number: 58514) connected to a bottle of irrigating fluid is introduced through this incision (Figure 4). Stay sutures are not needed. The AC maintainer has numerous advantages other than sheer maintenance of the anterior chamber. These include a constant outward flow from the AC, reducing chances of contamination, continuing hydrodissection, loosening the nucleus, making rotation easier, and safer cortical aspiration in a deep AC. Its use is mandatory for the manual technique that we use. Since the ACM has numerous other advantages, including the fact that we can almost forget about foot positions and "phaco" even the last hard, pointed quadrant in relative comfort, we use it for phacoemulsification too.

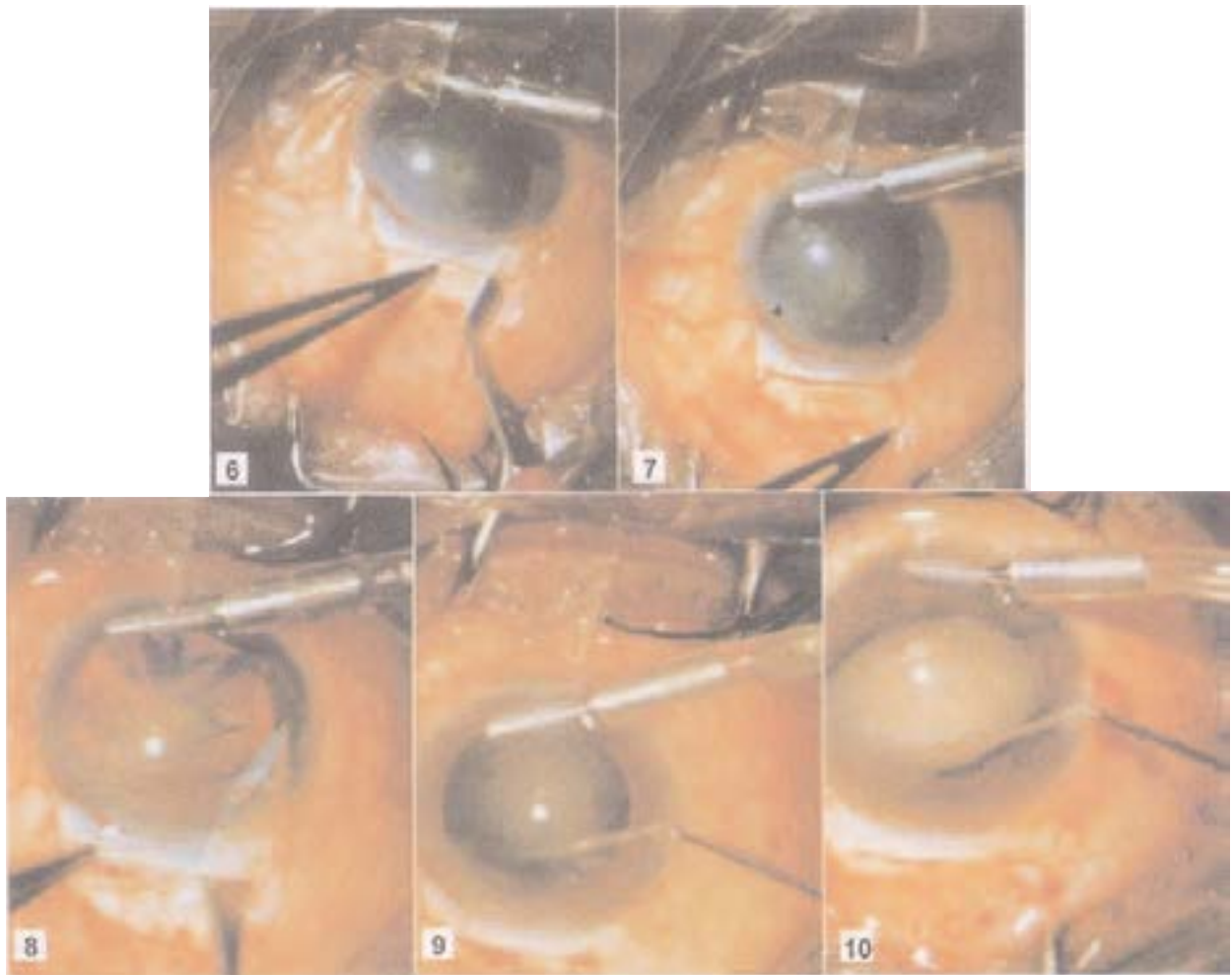


**Figure 1.** A paracentesis is made at the 9.30 position with a myringotomy blade. It starts just at the limbus and is bevelled. The cotton bud is used to "fixate" and manipulate the globe into a comfortable position, as well as increase the pressure to aid penetration. **Figure 2.** The CCC is performed with a bent 27 gauge needle introduced through the paracentesis into a chamber artificially deepened with methylcellulose. This step can be done with the ACM alone. **Figure 3.** The paracentesis for the anterior chamber maintainer is made in the peripheral cornea, inferiorly. Notice the long intra stromal length. This is achieved by introducing the entire width of the knife intrastromally prior to penetration into the anterior chamber. **Figure 4.** The anterior chamber maintainer is introduced into the anterior chamber through the inferior paracentesis. **Figure 5.** The scleral groove with two backward cuts.

For the cost-conscious, the CCC can be done using the ACM alone. The mechanics of the CCC are different, but can be learnt and the use of methylcellulose or viscoelastic can be totally eliminated in most cases.

### Step 3: Scleral incision

We prefer a fornix-based flap, and at the moment, the surgical philosophy requires a scleral tunnel incision.<sup>3</sup> The incision for the manual technique is described first. A 5.5mm scleral groove is fashioned 1mm behind the limbus. This is best done with a "pre-set" blade, but an ordinary blade fragment wielded a bit more carefully is certainly acceptable. A backward cut of 1-1.5mm, radial to the limbus is made from each edge of the incision (Figure 5). A scleral tunnel is fashioned with a crescent blade in the usual manner. The incision extends approximately 2-2.5mm into the cornea. The dissection is carried out toward the limbus on both sides to create a funnel shaped "pocket". The blade



**Figure 6.** The crescent blade is angled backwards to incorporate the backward cuts into the dissection. The same manoeuvre is performed on the other side of the incision. **Figure 7.** The extent of the dissection is clearly seen, in this case fortuitously delineated with a little blood (arrow shows anterior extent of dissection). **Figure 8.** The Keratome cut is directed to include the dissected area (almost to the limbus). Cutting is done on the down stroke only. The same technique is used on the opposite side of the wound. **Figure 9.** The Blumenthal cannula is introduced to hydrodissect under the anterior capsule at the equator between 10 and 12 o'clock and manipulates the upper pole of the nucleus into the anterior chamber. **Figure 10.** Manipulation of the upper pole in a "white" cataract.

is then angled to cut backwards so as to incorporate the backward cuts into the pocket. (Figure 6). Notice how far the incision extends into the cornea (Figure 7). While this makes for a very strong self-sealing wound, it can interfere with the visualisation needed for a CCC if it is delayed till after the incision. This is an additional reason for doing the CCC first. If we decide to proceed with phacoemulsification, the incision is a little different. We like to phaco using the "between nine and twelve" or "BENT" location. Hence, for phacoemulsification, the incision (again 5.5mm length) is fashioned in the BENT location. The only difference is that compared to the incision for the manual technique, it starts a little posteriorly in the sclera and extends less anteriorly into the cornea. This prevents undesirable striae and oar locking. If during phacoemulsification it becomes necessary to convert, the dissection allows for the nucleus to be delivered manually while preserving the small-incision nature of the wound. The incision also allows the implantation of a 6.5mm PMMA lens.

#### **Step 4: Anterior chamber entry**

The anterior chamber is entered using the appropriate size keratome in the usual manner. If the plan is phaco, the internal wound is not extended. If, however, the manual technique is planned, the internal incision is extended to include the area of dissection that has been performed with the crescent blade, that is, almost to the limbus (Figure 8). Any cutting is done on the downstroke (towards the AC) only. No cutting is used during the upstroke (withdrawal of the knife from the AC). A sawing movement is frowned upon.

Why not do the incision and AC entry first? Well, like some other surgeons, we prefer to "phaco" using the "between nine and twelve" or BENT incision. Also, as we have seen, the phaco incision is started slightly posterior (with a more posterior entry into the anterior chamber), compared to the manual technique. If conversion to the manual technique is required, this phaco incision is adequate. Finally, the incision is easier and best made in a globe firmed up with the ACM.

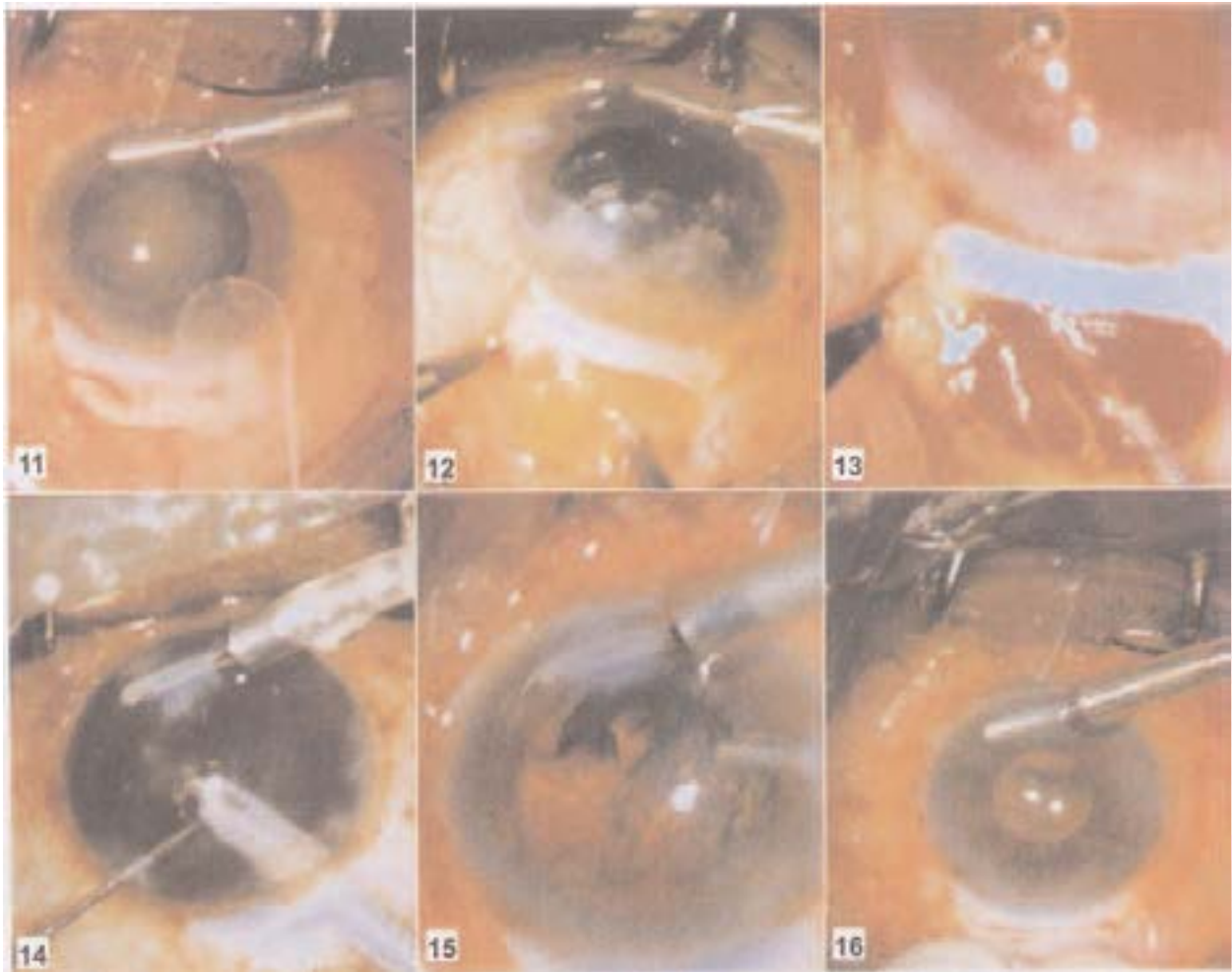
*Suppose the incision is made first, before attempting the CCC, and the CCC cannot be accomplished.* If the surgeon is now outside his comfort zone and wants to switch to the small-incision preserving manual technique, the difference in clock-hour location and site on sclera may make life just that little bit more difficult for the average surgeon. For the same reason, the paracentesis for the "second instrument" used for phacoemulsification, the location of which is dependent on the main incision, is also delayed till this stage. This additional paracentesis also helps in cortex extraction. Another reason for not making this paracentesis earlier is to avoid leakage of the methylcellulose and shallowing of the AC during CCC.

#### **Step 5: Nucleus management**

If a manual small-incision technique is planned, hydrodissection is performed and the superior pole of the nucleus is brought into the anterior chamber using the method of Blumenthal and his cannula (Visitech Instruments Fl, USA: catalogue number 585107 Figure 9). Briefly, the Blumenthal cannula is introduced through the paracentesis and insinuated just under the anterior capsule to the equator between 10 and 12 o'clock. Hydrodissection is performed and the cannula moved, in the same plane (or slightly posteriorly), towards the pupil and then anteriorly, to manipulate the upper pole of the nucleus into the anterior chamber. Figure 10 shows the same manoeuvre for a "white" cataract. A Sheet's glide (Visitech instruments, Fl, USA: catalogue number: 581033, Figure 11) is then inserted between the nucleus and the posterior capsule and the nucleus extracted by hydrodynamic expression (Figure 12). Again, briefly, pressure on the glide applied with forceps within the scleral tunnel causes the nucleus to engage the wound; the nucleus is expressed by the pressure of the ACM (hydrodynamic expression) helped by gentle pressure with forceps tip applied posterior to the scleral wound.

We feel that 99.8% of nuclei can be removed in this manner through a 5.5mm incision (Figure 13). With experience most surgeons could reduce the incision by another millimetre. In this case harder nuclei may require pie-shaped fragments to be chopped off before being expressed. We have not ventured below 5mm.

Minute details of the technique are beyond the scope of this article, but any manual technique should lend itself to this approach. If the plan is phacoemulsification, this is performed using the surgeon's preferred technique through an appropriately sized internal opening within the existing tunnel (Figure 14). We prefer the "stop and chop". Should there be a problem during phacoemulsification requiring conversion (hard nucleus, posterior capsular rupture, machine failure, etc.), the nucleus or its remnants can be manipulated into the anterior chamber with a cannula, with or without viscoelastic, and expressed as with the Blumenthal technique, or removed with forceps.



**Figure 11.** The Sheet's glide used for hydrodynamic expression. **Figure 12.** The nucleus is hydrodynamically expressed using a Sheet's glide inserted between the nucleus and the posterior capsule. **Figure 13.** A dark brown cataract is hydrodynamically expressed through a 5.5 mm incision. **Figure 14.** Phacoemulsification is performed using a small internal opening within the existing sclera tunnel. **Figure 15.** Cortex is safely extracted using a single port cannula introduced into the anterior chamber through a paracentesis. The anterior chamber remains well formed. **Figure 16.** The wound is checked for a leak; it usually withstands pressure even on the posterior aspect of the wound. The slight haze at 9 o' clock is caused by stromal hydration performed to seal the paracentesis.

### Step 6: Cortex removal

There is a major advantage in using the AC maintainer for this step. Cortex extraction is safely performed with a single port aspirating cannula on a syringe, through the paracentesis, in the closed, well maintained chamber provided by the ACM (Figure 15). With experience, only one paracentesis is needed for this step; however an additional paracentesis, at 2.30 o' clock helps provide better access to the cortex, especially for the less experienced surgeon. With phacoemulsification, the "second instrument" port is used for this purpose. Cortex, including 12 o' clock is safely and easily managed in this manner. There is no turbulence and variation in the depth of the AC, as frequently happens with the automated irrigation aspiration (the step where most posterior capsular ruptures occur with phacoemulsification); or indeed during the actual act of phacoemulsification.

## Step 7: Lens implantation

If a manual technique has been used (by choice or surgery-induced circumstances), a 6-6.5mm IOL is easily implanted through the incision. If a phacoemulsification was performed and a PMMA lens planned, the internal wound is extended at this stage. We usually perform lens insertion using the ACM. Viscous or viscoelastic agents can be used for this purpose if desired. In that case, the ACM is closed during this step. If a foldable lens was planned, and phacoemulsification has been uneventful, the incision then is not enlarged. The foldable IOL is implanted using the initial internal anterior chamber entry (2.8-3.2mm depending on the machine) used for phacoemulsification. If, however for some reason the foldable lens implantation is abandoned, the internal wound is extended as for the PMMA lens, and such a lens is used. We have no idea what the construction of a 5.5mm wound, with use of only 3mm as internal opening does to induced astigmatism, but reason that at the worst, it might be as bad as that with 5.5mm.

## Step 8: Closing up

The wound is tested for a leak (Figure 16). The ACM is removed. If there is any leakage from the paracentesis, these are hydrated by intrastromal injection of irrigating fluid. The opacification that occurs disappears by the next day. The conjunctiva is apposed with cautery or simply repositioned to the limbus.

## Complications and Management

While we would like to claim otherwise, complications peculiar to this approach do, regrettably, occur. There are several complications, like those related to creating the scleral tunnel, that are shared by other techniques. Only complications peculiar to our approach will be mentioned here.

Complications related to the paracentesis ports include inappropriate length, premature entry, leak, stromal hydration leading to poor visualisation and Descemet's membrane detachment. These can be avoided by using sharp myringotomy blades and good technique. If the port for the anterior chamber maintainer does not have a long intra stromal component, the maintainer may tend to slip during surgical manipulations.

Small Descemet's detachments at the smaller paracentesis are invariably inconsequential. One that occurs at the ACM site can be a real cause for worry. It is best prevented, but if it occurs, is managed as described in standard texts. In addition to what is needed, if there has been a Descemet's detachment, we tend to leave air in the anterior chamber.

Sometimes the nucleus just will not express and we have to contemplate "bailing out" to standard extracapsular surgery. Given the wound construction, this is difficult. Again it is best prevented by initially staying within one's comfort zone and using a larger (6- 6.5mm) incision; with increasing experience the size is easily and safely decreased. *What if we have to convert?*

If we have to, we must, and there are two options. The backward cuts in the incision are ignored. The horizontal partial thickness limb of the incision is extended to 8-9 mm parallel to the limbus and the nucleus removed using a vectis. Alternatively, the original wound is closed, with sutures if necessary, ignored, and another, larger corneal wound is fashioned, perhaps temporally. Obviously, in the type of situation we are talking about, these manipulations are easier said than done.

If there is a posterior capsular rent, or a vitreous loss, the presence of the ACM is a double-edged sword. On the one hand, it facilitates vitrectomy through the paracentesis port and frees one hand to hold another instrument or a light pipe to sweep the vitreous or perform other manipulations. On the other hand, especially if the bottle height has not been lowered, it can extend the capsular rent as well

as contribute to loss of cortex or epinucleus into the vitreous. This can be prevented by decreasing the bottle height as soon as a tear is noticed, as well as using a "dry" cortical aspiration technique.

## Discussion

Small-incision surgery is certainly a desirable modern goal. We have described an approach even less experienced surgeons can use to reliably achieve it. The approach we describe has evolved over several years and continues to evolve. Initially, for a planned manual small incision, the comfort zone may require a larger incision size and may dictate relaxing incisions in the CCC. A temporal approach, when necessary or combination with filtration is already being done and is not counted. As far as the incision is concerned, the backward cuts need not be "pre-placed". They can be initiated after completion of the tunnel and dissection, by angling the blade and cutting backwards as described for the pre-placed cuts; just needs only a very sharp blade. Should the blades be less than sharp, the pre-placed cuts are an advantage. An exaggerated "frown" incision works just as well; the technique we describe, in our hands, is more reproducible and easier to teach.

Those committed to a foldable lens may elect to start with the 3mm incision (scleral or temporal clear corneal, if the surgeon so desires) and convert to the 5.5mm manual only if needed. If this need arises with a temporal clear corneal section, a new wound should be fashioned. Either way, the dissection and manipulations at this stage, (especially in the high pressure situations where this becomes necessary) are possible with a firm globe (ACM helps here too) and excellent instrumentation, but are perhaps easier for inherently gifted surgeons. If the nucleus is already in small pieces when the need for bailout arises, we can use forceps through the smaller incision itself to "bail out". With increasing experience improvements are always made.

Readers who decide to adopt this surgical philosophy will find their own "best" way. Some may use it only to maintain the small incision whenever phaco fails. Some may decide to stick with the manual technique for all cases, and others may use it the way we have described.

One question that will no doubt be asked is "*Shouldn't we discourage persisting with the manual small- incision technique only? How about induced astigmatism?*" Our own unpublished data show a difference in induced astigmatism of 0.4 diopters between the two incision sizes. There is published evidence that 3.2mm incisions induce "statistically significantly" less astigmatism than 5.5mm wounds.<sup>4</sup> Yes, but if we look at the actual difference in the induced astigmatism that produced a "statistically significant" result, it is about 0.3 D of cylinder.<sup>4</sup> After all, we are in a developing country and a 3.2mm incision costs 10 times as much, in terms of the lens alone. Be that as it may, there is no one "correct" way; to each his own. The authors have been formally trained in phacoemulsification and use as well as teach it routinely.<sup>5,6</sup> We just like to have several techniques in our armamentarium and tailor the surgery according to the individual patient's needs.

As with any approach, anticipated and unexpected problems are bound to crop up. Despite our best efforts, happen, they will. *How do we avoid problems? Can we fix it so that we always achieve a manual small incision?* The truth is we can't. That is why we deliberately titled this article "Achieving small incision surgery 99.8% of the time". As our "scientific" bible states "absolute certainty is limited to theologians and like minded physicians".<sup>7</sup> We can only strive to improve what is currently possible. That, we believe, our approach achieves.

## References

1. Kansas P. Phacofracture. In: Rozakis G W, editor. *Cataract Surgery- Alternative Small Incision Techniques*. New Jersey, USA: SLACK Incorporated.1990. pp 45-70.
2. Dada T, Sharma N, Vajpayee R B, Dada V K. Conversion from phacoemulsification to extracapsular cataract extraction: Incidence, risk factors,and visual outcome. *J Cataract Refract Surg* 1998;24:1521-24.
3. Blumenthal M, Askenazi I, Fogel R, Assia E I. The gliding nucleus. *J Cataract Refract Surg* 1993;19:435-37.
4. Oshika T, Nagahara K, Yaguchi S, Emi K, Takenaka H,Tsuboi S, et al. Three year prospective, randomized evaluation of intraocular lens implantation through 3.2 and 5.5 mm incisions. *J Cataract Refract Surg* 1998;24:509-14.
5. Thomas R, Braganza A, Raju R, Lawrence, Spitzer K H. Phacoemulsification - A senior surgeon's learning curve. *Ophthalmic Surg* 1994;25(8):504-9.
6. Thomas R, Naveen S, Jacob A, Braganza A. Visual outcome and complications of residents learning phacoemulsification. *Indian J Ophthalmol* 1997;45:215-19.
7. Sackett D L, Haynes R B, Guyatt G H, Tugwell P. *Clinical Epidemiology*, Little, Brown & Company, Boston, 1991.