

BRONCHOSCOPY AND ASSOCIATED PROCEDURE CODING IN ICD-10-PCS AND CPT

WHY AND HOW IS A BRONCHOSCOPY PERFORMED?

A bronchoscopy is a test to view the airways and diagnose lung disease. It may also be used during the treatment of some lung conditions. A bronchoscope is a device used to see the inside of the throat, larynx, trachea, airways and lungs. The scope can be flexible or rigid. A flexible scope is almost always used. It is a tube less than 1/2-inch wide and about 2 feet long. In rare cases, a rigid bronchoscope is used. This is done when there is bleeding in the airway that could block the flexible scope's views or to remove large tissue samples for biopsy. A rigid scope may also be used to clear food or other objects in the airway.

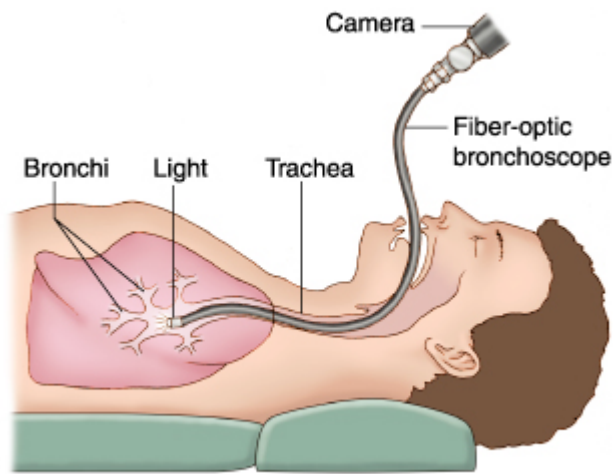
Here is how the bronchoscopy is performed:

The scope is passed through the mouth or nose through the windpipe (trachea) and into the lungs. Going through the nose is a good way to look at the upper airways. Going through the mouth allows the doctor to use a larger bronchoscope. If a flexible bronchoscope is used, the patient will probably be awake but sedated.

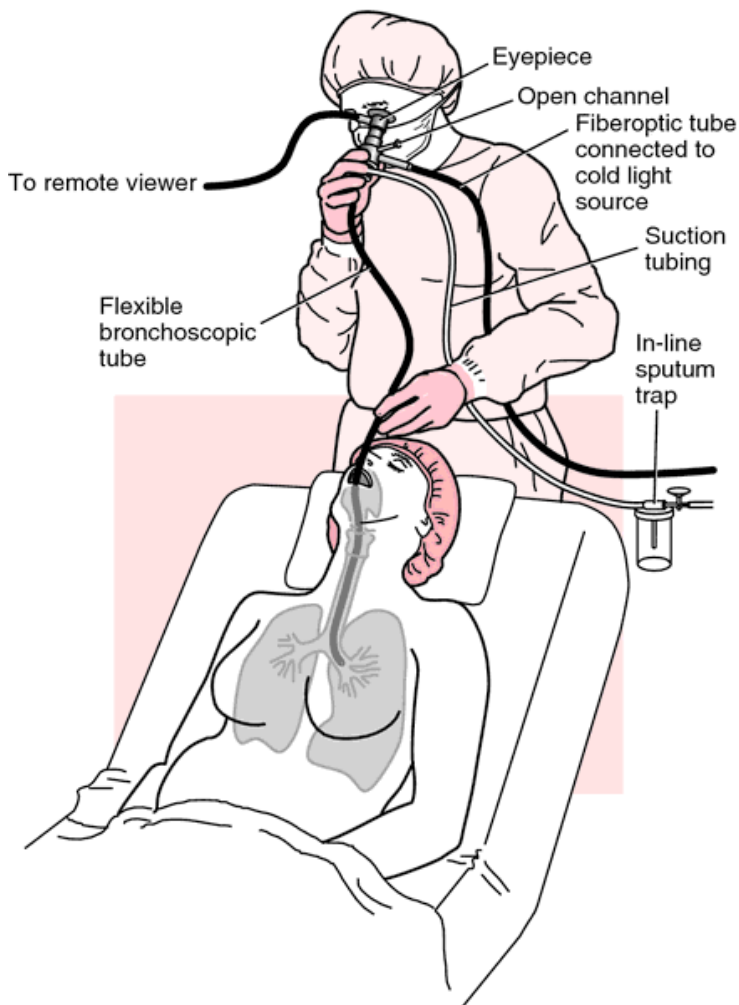
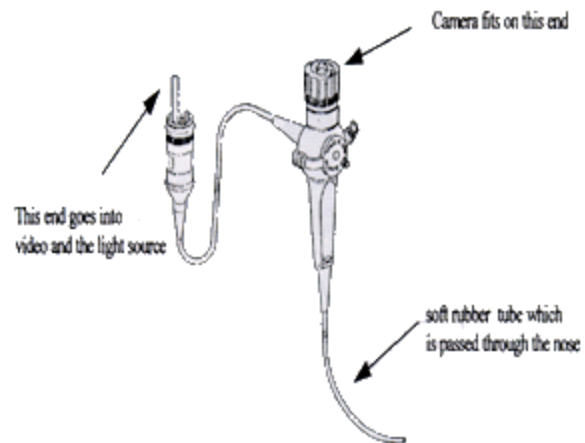
During the procedure:

- The patient will likely get medicines through a vein (intravenously) to help them relax. Or the patient may be put under general anesthesia, especially if a rigid scope is used.
- A numbing drug (anesthetic) will be sprayed in the mouth and throat. If bronchoscopy is done through the nose, numbing jelly will be placed in one nostril.
- The scope is gently inserted. It will likely make the patient cough at first. The coughing will stop as the numbing drug begins to work.
- The doctor may send saline solution through the tube. This washes the lungs and allows the doctor to collect samples of lung cells, fluids, and other materials inside the air sacs. This part of the procedure is called a lavage.
- Sometimes, tiny brushes, needles, or forceps may be passed through the bronchoscope to take very small tissue samples (biopsies) **from the bronchial tissue within the bronchus**. At times a forceps or other instrument such as a needle may be passed **through the bronchial wall into nearby lung tissue proper** or lymph nodes. This is usually done under fluoroscopy so the physician can see where to guide the instrument. The coder should really search the operative note for this information as it makes a difference.
- The physician can also place a stent in the airway or view the lungs with ultrasound during the procedure.
- Sometimes ultrasound is used to view the lymph nodes and tissues around the airways.

The below photos depict how a bronchoscopy is performed:



BRONCHOSCOPE



ANATOMY OF THE BRONCHUS AND LUNGS AND THE RELATION TO CODING

The respiratory system is composed of various structures. It is important for the coder to be able to differentiate these different structures as bronchoscopic procedures can be performed on bronchial tissue, lung tissue, lymph nodes, and other structures. Physicians sometimes use the term "lung" loosely when they actually are addressing bronchial tissue. They many times use "lung" and "bronchial" or "bronchus" interchangeably. This makes it very confusing for the coder to choose the correct code, especially in ICD-10-

PCS because there are body part values for both bronchial tissue and lung tissue by segment. This is a frequent error for coders, coding to lung tissue when the physician is actually biopsying bronchial tissue. Looking at the pathology report can sometimes be helpful however many pathologists use the terms “lung” and “bronchial” tissue interchangeably as well in the headers. Coders must read the entire pathology report to ascertain what tissue was taken. It rests with the coder to accurately identify the specific site of the procedure or to query when it is not easily discernable within the medical record.

Photo 1: This first photo is basic, however it does show that there are three lobes on the right and two lobes on the left. When coding in ICD-10-PCS there are body part values for both the lung and the bronchus in each of these areas.

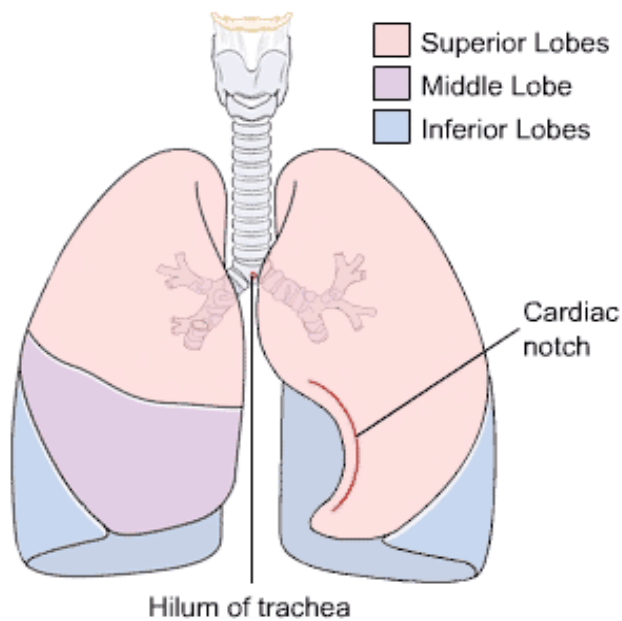


Photo 2: Next we have a simple diagram of the segments within the bronchi and lungs.

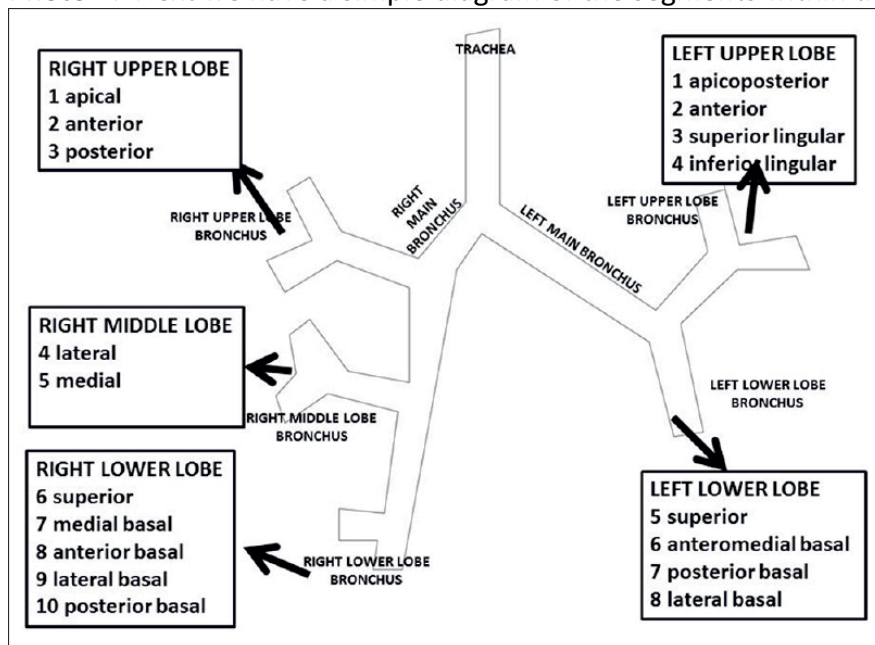


Photo 3: The below is an excerpt from ICD-10-PCS to show the coder the body part values in the respiratory body system. Note that there are separate body part values for both the bronchus and lung by lobe. We have also broken out the different bronchopulmonary segments for each lung following the excerpt.

Body Part	Approach	Device	Qualifier
1 Trachea 2 Carina 3 Main Bronchus, Right 4 Upper Lobe Bronchus, Right 5 Middle Lobe Bronchus, Right 6 Lower Lobe Bronchus, Right 7 Main Bronchus, Left 8 Upper Lobe Bronchus, Left 9 Lingula Bronchus B Lower Lobe Bronchus, Left C Upper Lung Lobe, Right D Middle Lung Lobe, Right F Lower Lung Lobe, Right G Upper Lung Lobe, Left H Lung Lingula J Lower Lung Lobe, Left K Lung, Right L Lung, Left M Lungs, Bilateral	0 Open 3 Percutaneous 4 Percutaneous Endoscopic 7 Via Natural or Artificial Opening 8 Via Natural or Artificial Opening Endoscopic	Z No Device	X Diagnostic Z No Qualifier
N Pleura, Right P Pleura, Left R Diaphragm, Right S Diaphragm, Left	0 Open 3 Percutaneous 4 Percutaneous Endoscopic	Z No Device	X Diagnostic Z No Qualifier

The right lung has 10 bronchopulmonary segments:

Superior/Upper lobe:

Apical
 Anterior
 Posterior

Middle lobe:

Medial
 Lateral

Inferior/Lower lobe:

Superior
 Anterior basal
 Posterior basal
 Medial basal
 Lateral basal

The left lung has 8 to 10 bronchopulmonary segments:

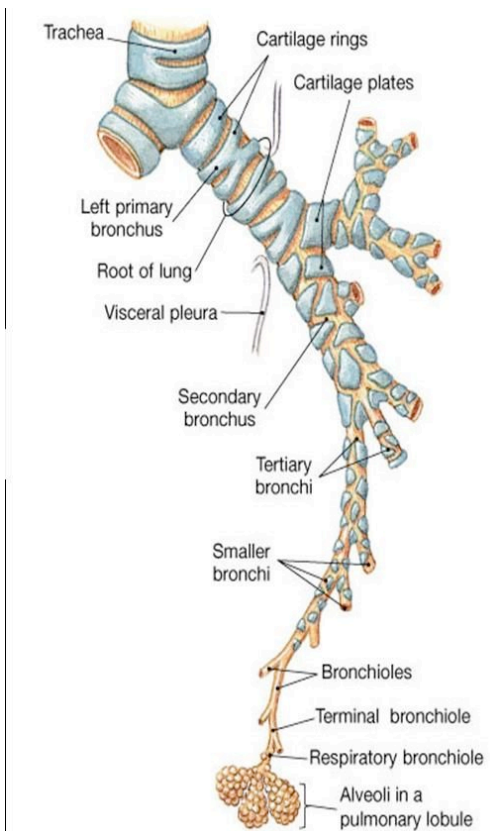
Superior/Upper lobe:

- Apical (may be combined with posterior to form apicoposterior)
- Posterior
- Anterior
- Superior lingular
- Inferior lingular

Inferior/Lower lobe:

- Superior
- Anterior basal (may be combined with medial to form anteromedial basal)
- Medial basal
- Lateral basal
- Posterior basal

Photo 4: The photo below depicts the branching out of the bronchus out to the alveoli. The bronchioles are considered bronchus and the alveoli are considered lung tissue. Bronchioles are minute branches into which a bronchus divides. The bronchioles connect to the alveoli (air sacs). Alveoli are any of the many tiny air sacs in the lungs at the ends of bronchioles where the exchange of oxygen and carbon dioxide takes place. Hence they are considered part of the lung body part values. They also have capillaries around each alveolus where the air exchange takes place in the blood. When a physician takes lung tissue after puncturing through a bronchial wall, it is frequently alveoli (lung) tissue which is being biopsied. A human adult lung contains an average of 480 million alveoli.



CODING CHALLENGES IN ICD-10-PCS

We will first address the nuances of bronchoscopy coding in ICD-10-PCS. Discussion of CPT coding will follow further below. As mentioned earlier, one of the most frequent errors coders make is coding a “transbronchial” biopsy to a code for lung tissue excision when there is no evidence that actual lung tissue was excised. This will change the DRG on the case. Consider the following: A patient has a mass of the left upper lobe “lung” and is scheduled for bronchoscopic biopsy. The physician states that the patient is scheduled for a “lung biopsy.” The physician inserts the scope, views the bronchial tree and then takes an endobronchial biopsy of tissue in the left upper lobe bronchus. Viewing the pathology report validates this is bronchial tissue. The bronchus is not punctured and no actual lung tissue is biopsied. Pathology report confirms bronchus malignancy.

INCORRECT CODING AND DRG:

Diagnosis: C34.12, Malignant neoplasm of upper lobe, left bronchus or lung

Procedure: 0BBG8ZX, Excision left upper lung lobe, endoscopic, diagnostic

DRG: 168, Other resp system O.R. proc. w/o CC/MCC RW 1.3359

CORRECT CODING AND DRG:

Diagnosis: C34.12, Malignant neoplasm of upper lobe, left bronchus or lung

Procedure: 0BB88ZX, Excision left upper lobe **bronchus**, endoscopic, diagnostic

DRG: **182, Respiratory neoplasms w/o CC/MCC RW 0.8167**

As the coder can see, assuming the physician's term "lung" literally, can result in an incorrect procedure code and DRG assignment. This is actually an area of OIG and RAC reviewer focus.

Keep in mind that the term “transbronchial” literally is defined as “through, beyond or across the bronchus” however it can also be interpreted as “through or within the bronchus.” This is why it is such a difficult coding area. The coder **MUST** read the operative report and pathology report to ascertain what type of tissue was actually biopsied. The original intent of the term “transbronchial lung biopsy” was to infer an actual biopsy of lung tissue was taken. However, reading many operative reports, coders will see that this is not always the case. Since this impacts the DRG, attention to the actual tissue biopsied in the report is a must.

In addition, coders must be cautious when selecting terms in an encoder. Coders can easily be led to incorrect codes depending on the terms selected. Coders must always verify their codes in the tabular of both types of code books.

From the AHA ICD 10 Coding handbook: “Bronchoalveolar lavage (BAL), also called “liquid biopsy,” should not be confused with whole lung lavage. BAL is a diagnostic procedure performed via a bronchoscope under local anesthesia. It involves washing out **alveoli tissue** and **peripheral airways** to obtain a small sampling of tissue. BAL is coded to the root operation “Drainage” because it involves removing fluids. The body part value should be chose for the particular LUNG lobe that the BAL is focused on. Recently AHA updated an older Coding Clinic, changing the body part value to LUNG:

Correction Notice: Bronchoalveolar Lavage Coding Clinic, First Quarter 2017: Page 51

Summary: *Coding Clinic*, First Quarter 2016, page 26, **contained an error** regarding the appropriate ICD-10-PCS code for bronchoalveolar lavage (BAL). The previous code was assigned to lower lobe bronchus in error. BAL involves washing out and sampling **alveoli of the lung** (small sacs within the lungs). The appropriate code assignment for a BAL is 0B9J8ZX Drainage of left **lower lung lobe**, via natural or artificial opening endoscopic, diagnostic since the lung body part values more accurately capture the objective of bronchoalveolar lavage,

The BAL of the peripheral airways is included in the code assigned to the body part lung so no extra code needs to be assigned. So bottom line, for BAL assign lung body part not a bronchus body part.

Whole lung lavage is a therapeutic procedure performed for pulmonary alveolar proteinosis. The procedure is performed under general anesthesia and mechanical ventilation. The lungs are lavaged by filling and emptying one lung at a time with saline solution. The second lung is usually lavaged three to seven days after the first lung has been lavaged. Report whole lung lavage using code **3E1F88Z, Irrigation of respiratory tract using irrigating substance, via natural or artificial opening endoscopic**. Assign also a code for the mechanical ventilation provided.

Code 3E1F88Z would not be assigned for washings only. See *Coding Clinic*, First Quarter 2017: Page 51 that addresses when washings are performed with BAL.

Coders will need **to report separate codes for each separate lobe biopsied**, whether lung tissue or bronchus tissue. For example, if a bronchoscopy is performed and the physician performs endobronchial biopsy of the right upper lobe bronchus and right lower lobe bronchus, then two codes are reported:

0BB48ZX for the bronchoscopic biopsy of the right upper lobe bronchus
0BB68ZX for the bronchoscopic biopsy of the right lower lobe bronchus

If lymph nodes were biopsied via bronchoscopy and TBNA (transbronchial needle aspiration) then the below code would be added:

07B74ZX for the biopsy of thorax lymph nodes via needle. See *Coding Clinic*, First Quarter 2014 p. 26.

PROCEDURAL VIDEOS

Bronchoscopy with Endobronchial Biopsy (5:15) <https://www.youtube.com/watch?v=XTC3AKmtrcs> (2:21) In this video, bronchial tissue is obtained by forceps via bronchoscopy. Only bronchial tissue is taken by the forceps (or brush technique if utilized.) No lung tissue is taken as there is no puncturing of the bronchial wall.

Bronchoscopy with LUL bronchial biopsy by forceps and BAL (1:05)

<https://www.youtube.com/watch?v=sxe4SCc6Meg>

Transbronchial Biopsy Needle Aspiration (TBNA) of Subcarinal Lymph Node Tissue (7:49)

<https://www.youtube.com/watch?v=Wcr5LxIZxUk> You will see in this video that the physician punctures through the mucosa of the bronchus to guide the needle into the subcarinal lymph node. This is actually a very common procedure. Many physicians choose to biopsy the thoracic lymph nodes to ascertain if a malignant

tumor has spread to the lymph nodes. This will confirm the primary and secondary sites of malignancy. This would be coded to “07B74ZX , Excision of thorax lymphatic, percutaneous endoscopic approach, diagnostic.”

If the physician wants to needle biopsy a lung tumor itself, many times this is done by placing the needle transthoracic rather than through the bronchoscope. See below.

Transthoracic Lung Biopsy: <https://www.youtube.com/watch?v=abvYaB2Vcml> The needle is inserted through the skin and chest wall into the lung, samples tissue, then withdraws needle.

CODING CLINICS PERTAINING TO BRONCHOSCOPY AND ASSOCIATED PROCEDURES

Included are the Coding Clinic Q&A summaries that are especially important to coders and are involved in errors found on reviews. Please be sure to read all of the below Coding Clinic issues in full on bronchoscopy coding as these will be utilized in the quiz. Coders must review any upcoming Coding Clinics for additional information.

Bronchoscopy with Suctioning and Washings for Removal of Mucus Plug

Coding Clinic, Third Quarter 2017: Page 14

Summary: Suction of RUL bronchial mucus plug via bronchoscopy with bronchial washings is coded to root operation extirpation, 0BC58ZZ, Extirpation of matter from right middle lobe bronchus, via natural or artificial

Bronchoscopy with Suctioning for Removal of Retained Secretions

Coding Clinic, Third Quarter 2017: Page 15

Summary: Secretions were suctioned from the lower lobes of the lung by bronchoscope Assign 0B9M8ZZ, Drainage of bilateral lungs, via natural or artificial opening endoscopic, for the suctioning of the lower lobes of the lung.

Correction Notice: Bronchoalveolar Lavage (BAL)

Coding Clinic, First Quarter 2017: Page 51

Summary: *Coding Clinic, First Quarter 2016, page 26, contained an error regarding the appropriate ICD-10-PCS code for bronchoalveolar lavage (BAL).* Code 0B9B8ZX, Drainage of left lower lobe bronchus via natural or artificial opening endoscopic, should be 0B9J8ZX, Drainage of left **lower lung lobe**, via natural or artificial opening endoscopic, diagnostic. BAL involves washing out and sampling alveoli of the lung and not the bronchus.

Note that the below in RED FONT is no longer valid:

Bronchoalveolar Lavage, Endobronchial Biopsy and Transbronchial Biopsy

Coding Clinic, First Quarter 2016: Page 26

Summary: A bronchoscopy is performed, **bronchoalveolar lavage (BAL), bronchial washings and cytology brushings** were obtained in the right **upper lobe bronchus**; **endobronchial biopsies** and **transbronchial biopsies** from the **right upper lobe**; and **bronchoalveolar lavage samples were obtained from the left lower lobe**. The brushings are coded to “excision.” The BAL is coded to “Drainage” and of the lung body part, not the bronchus. Index states:

Lavage

Bronchial alveolar, diagnostic see Drainage,

Respiratory System **OB9**

Fiberoptic Bronchoscopy with Brushings and Bronchoalveolar Lavage

Coding Clinic, First Quarter 2016: Page 27

Summary: Brushings via bronchoscopy are coded to root operation "Excision" and body part bronchus, using correct lobe and BAL is coded to Drainage, Lung, and to correct lobe. (Corrected via 1Q2017 CC)

Selective Excision of Paratracheal Lymph Nodes

Coding Clinic, Third Quarter 2014: Page 10

Summary: A patient diagnosed underwent flexible fiberoptic bronchoscopy, video-assisted thoracoscopic right lobectomy and removal of lymph nodes from the right paratracheal stations 2, 4R, 7, 9, and 10R. Code to "Excision" of lymph nodes unless the MD is queried to see if a chain of lymph nodes are removed.

Correction Notice: Transbronchial Needle Aspiration Lymph Node Biopsy

Coding Clinic, First Quarter 2014: Page: 26

Coding Clinic for ICD-10-CM/PCS Fourth Quarter 2013, pages 111-112, was incorrect. It should not be drainage but be coded to 07B74ZX **Excision** of thorax lymphatic, percutaneous endoscopic approach, diagnostic. The 4Q2013 Coding Clinic has more information.

Fiducial Marker Placement

Coding Clinic, First Quarter 2014: Page 20

Summary: A radiologic marker placement such as a fiducial marker **is not coded** Code only the inspection of left lung, via natural or artificial opening endoscopic. The appropriate root operation for transbronchial needle aspiration biopsy is "Excision." Fine needle aspiration is done by placing a needle through tissue, applying suction and the tissue is aspirated for biopsy. The root operation drainage is used when fluid or gas is removed, for diagnostic or therapeutic purposes (i.e., collection of fluid or drainage of abscess). So to recap, tissue or cells is coded to excision, aspiration of fluid only without cells is coded to drainage.

Brush biopsy of lung

Coding Clinic, **Fourth Quarter 1992** Page: 27 to 28

(Note that this is for ICD-9-CM however the information is clinical and still holds true)

Summary: The term brush biopsy of the lung is actually a misnomer. The brush biopsy is of the bronchus, not the lung. No lung tissue is taken during a brush biopsy. This is different from a transbronchial biopsy where the bronchoscope biopsy forceps actually punctures the terminal bronchus and samples of the peribronchial alveoli (lung tissue) are taken.

CPT AND BRONCHOSCOPY CODING

Most of the bronchoscopy codes in CPT are in range 31622-31654. Usually a separate code is assigned for each different bronchoscopic procedure, unless there is an NCCI edit that precludes the reporting of both codes. NCCI edits should be followed for most payors including Medicare.

CPT coding for bronchoscopies has been fairly straightforward. In 2016, the AMA deleted the code 31620 for EBUS during bronchoscopic diagnostic or therapeutic interventions. EBUS combines a bronchoscope with ultrasound to visualize the bronchi and adjacent structures. The AMA created three new codes for EBUS with bronchoscopy for the purpose of obtaining transtracheal and transbronchial sampling of lymph nodes or peripheral lesions.

The new codes are:

31652 with endobronchial ultrasound (EBUS) guided transtracheal and/or transbronchial sampling (eg, aspiration[s]/biopsy[ies]), **one or two** mediastinal and/or hilar lymph node stations or structures

31653 with endobronchial ultrasound (EBUS) guided transtracheal and/or transbronchial sampling (eg, aspiration[s]/biopsy[ies]), **3 or more** mediastinal and/or hilar lymph node stations or structures

+31654 with transendoscopic endobronchial ultrasound (EBUS) during bronchoscopic diagnostic or therapeutic intervention(s) for peripheral lesion(s) (List separately in addition to code for primary procedure[s])

(Use 31654 in conjunction with 31622, 31623, 31624, 31625, 31626, 31628, 31629, 31640, 31643, 31645, 31646)

(For EBUS to access mediastinal or hilar lymph node station[s] or adjacent structure[s], see 31652, 31653)
(Report 31652, 31653, 31654 only once per session)

The below photo will help to guide the coder in what lymph nodes are considered mediastinal, and which lymph nodes are considered hilar. Many times the physician will dictate in the report that they sampled stations 4L, 4R and 7 via EBUS. As you see from the photo below, these are mediastinal lymph nodes and code 31653 would be assigned.

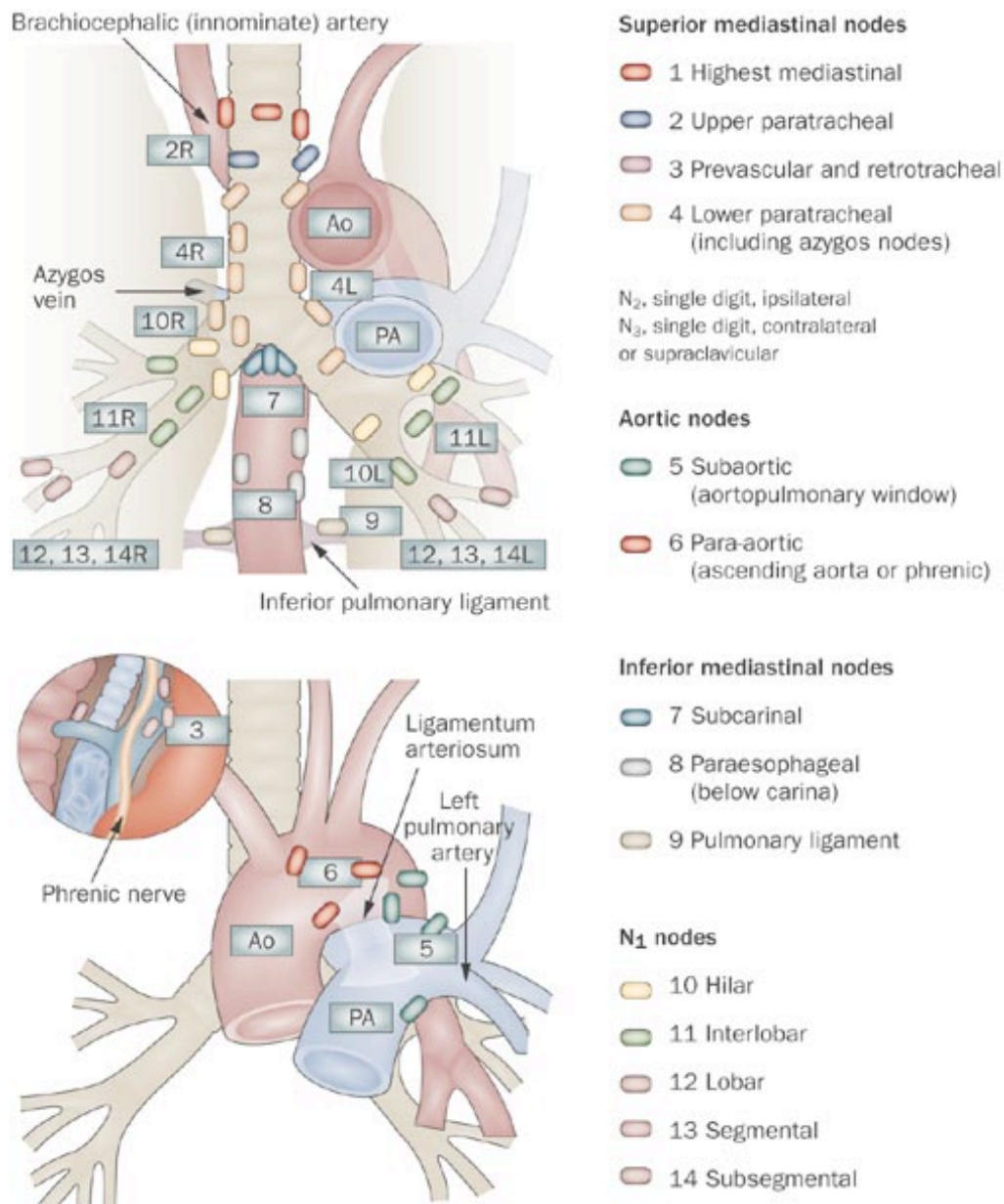
For 31654, the description in the CPT Changes-An Insider's view 2016 book gives a Clinical Example of this code used for a peripheral lung lesion, which it describes as **"out of the visual field of the bronchoscope."** And the rationale for this code is: "to identify transendoscopic endobronchial procedures performed during diagnostic or therapeutic bronchoscopic procedures for lesions peripheral to the lymph node stations or structures."

Here is an example of a case coded to 31654:

31654 Example

A patient presents with a 1.5-cm peripheral lung lesion. Via transendoscopic ultrasound probe guidance, the lesion is identified.

An imaging catheter is introduced via the bronchoscope. The catheter is directed via multiple segments until the desired subsegment is identified, to reach and image the lesion to confirm location and specifics of the lesion. The lesion, which is **out of the visible field of the bronchoscope**, is located and described. The catheter is then removed and the target accessed. The catheter is reintroduced to reconfirm position and access to the target. The process is repeated for each additional target lesion.



CODING CLINIC FOR HCPCS AND CPT ASSISTANTS RELATED TO BRONCHOSCOPY

Be sure to read these in their entirety:

Unilateral Bronchoscopy

Coding Clinic for HCPCS, Fourth Quarter 2015: Page 7

Endoscopic Procedures

Coding Clinic for HCPCS Second Quarter 2011 Page: 1

Transbronchial Biopsy with Core Needle

Coding Clinic for HCPCS Second Quarter 2010 Page: 4

2011 Respiratory System Surgery/Pulmonary Medicine/Category III Bronchial Valve Changes

CPT Assistant January 2011, Volume 21, Issue 1, page 6

Coding Communication: Bronchoscopy

CPT Assistant April 2010, Volume 20, Issue 9, page 5

Surgery: Respiratory System

CPT Assistant May 2008, Volume 18, Issue 5, pages 13 -15

Coding Communication: Bronchoscopy Procedures: A Closer Look

CPT Assistant, August 2005, Volume 15, Issue 8, pages 4-6

Coding Communication: Bronchoscopy

CPT Assistant, September 2004, Volume 09, Issue 14, pages 8-10

Many older coding references have outdated information due to coding changes

CODING EXAMPLES

#1 Here is an excerpt from an actual operative report for a **bronchoscopy with bronchial biopsy**:

"Procedure Done: Bronchoscopy and bilateral washings. Washings with **bronchoalveolar lavage** from the right upper lobe, **endobronchial biopsies** of the right upper lobe with **brushing** from the right upper lobe.

Procedure note: Full survey of the airways was achieved..... bilateral washings and **bronchial alveolar lavage** from the right upper lobe with **endobronchial biopsies** from the right upper lobe and **brushing** from the right upper lobe all were done successfully endoscopically."

For ICD-10-PCS this procedure is coded:

0BB48ZX for excision of right upper lobe bronchus via bronchoscopy for diagnostic purposes. (This includes both the endobronchial biopsies and brushings of the RUL) "Brushings" are coded to the root operation "Excision" and "lavage" is coded to the root operation "Drainage."

0B9C8ZX for drainage of RUL lung for BAL of the right upper lobe via bronchoscopy for diagnostic purposes. See Coding Clinic, First Quarter 2017: Page 51. Use lung as the body part.

In the index, washings is assigned to "irrigation." This may be confusing to the coder. In our example the washing was for lavage so that specimens could be taken for diagnostic purposes, **not** to irrigate the bronchus as we saw in the previous message. Washing is a procedure in which cells are taken from the inside of the bronchi. A bronchoscope (a thin, tube-like instrument with a light and a lens for viewing) is inserted through the nose or mouth into the lungs. A mild salt solution is washed over the surface of the airways to collect cells, which are then looked at under a microscope. Bronchial washing is used to find infections. It may also help find cancer or changes in cells that may lead to cancer.

In our example, the MD states "bilateral washings" yet there is evidence of washings and lavage of right upper lobe, not irrigation only. And there is also excision of RUL bronchial tissue. Since two different root operations have been performed on the same body site, then both codes are reported. In addition, BAL is coded to body part LUNG and not bronchus. In this case the washings are actually part of the lavage and not coded separately. Coders must be careful when the physician uses the terms "washing" "irrigation" and "lavage" and look for the objective.

For CPT this procedure is coded:

31623, Bronchoscopy, rigid or flexible, including fluoroscopic guidance, when performed, diagnostic, with cell washing, when performed; **with brushing** or protected brushings for the brushings

31625, Bronchoscopy, rigid or flexible, including fluoroscopic guidance, when performed, diagnostic,

with **cell washing**, when performed; with bronchial or **endobronchial biopsy(s)**, single or multiple sites
31624 Bronchoscopy, rigid or flexible, including fluoroscopic guidance, when performed, diagnostic,
with **bronchial alveolar lavage**

#2 Here is an excerpt from an actual operative report for a **bronchoscopy with lung biopsy**:

- “Procedures: 1. Flexible bronchoscopy
2. **EBUS, Radial probe**
3. **Transbronchial lung biopsy, RUL**
4. **BAL of the RUL**
5. Fluoroscopy

Patient brought to procedure room and time out performed. 1% lidocaine was used to anesthetize the OP. Moderate sedation was administered. The flexible bronchoscope was inserted via the mouth and into the trachea. A full airway survey was performed down to the subsegmental bronchi. **There was no endobronchial lesions.** **The scope was wedged in the RUL where a BAL was performed.** The scope was advanced into the RUL and the radial EBUS probe was inserted and used to examine the peripheral airways to identify the target lesion. In the post RUL, there were 5 subsegmental airways seen and with a **combination of radial EBUS** and fluoroscopy, the airway closest to the target was identified and the EBUS probe was removed. **Under direct fluoroscopic guidance, transbronchial lung biopsy times 6 was performed in the RUL of the location of the target.** Moderate bleeding was noted and this was controlled using ice saline and 3 cc of topically administered diluted phenylephrine. Aspiration of bloody secretions was performed and the bronchoscope removed.

Pathology:

LUNG, RIGHT UPPER LOBE, TRANSBRONCHIAL BIOPSY:

Lightly pigmented intra-alveolar macrophages, eosinophils and neutrophils
Negative for malignancy
No granulomas identified

The specimen is received in formalin labeled with patient name and “RUL TBNA”

Fragments 3. Sizes less than 0.1 to 0.2 cm.

Cassette Summary: A1 three pieces, filtered please note smallest tissue may not survive processing”

For ICD-10-PCS this procedure is coded:

0B9C8ZX for the bronchoalveolar lavage (drainage) of the right upper lobe via bronchoscopy for diagnostic biopsy. See Coding Clinic, First Quarter 2017: Page 51. Use lung as the body part.

0BBC8ZX for the transbronchial lung tissue excision of the right upper lobe via bronchoscopy for diagnostic biopsy. Note that lung tissue is documented. This is a true transbronchial lung biopsy. Aspiration of the bloody secretions is part of the overall procedure.

Most clients do not code the EBUS in ICD-10-PCS.

For CPT this procedure is coded:

31628, Bronchoscopy, rigid or flexible, including fluoroscopic guidance, when performed, diagnostic, with cell washing, when performed; **with transbronchial lung biopsy(s), single lobe.**

31624, Bronchoscopy, rigid or flexible, including fluoroscopic guidance, when performed, diagnostic, with cell washing, when performed; with broncho alveolar lavage
+31654, with transendoscopic endobronchial ultrasound (EBUS) during bronchoscopic diagnostic or therapeutic intervention(s) for peripheral lesion(s) (List separately in addition to code for primary procedure(s)) **(This is for the EBUS identification of the lung (peripheral) lesions to biopsy)**

REFERENCES

AHA Coding Clinic
ICD-10 Coding Handbook
CPT Assistant

Websites Utilized:

<https://www.nlm.nih.gov/medlineplus/ency/article/003857.htm>

Photos:

<http://www.mdguidelines.com/bronchoscopy>

<http://web.stanford.edu/group/cfcenter/Bronchoscopy.html>

<http://medical-dictionary.thefreedictionary.com/bronchoscopy>

Proceed now to take the 10 question quiz.