

LEARNING OBJECTIVES FOR THIS EXERCISE:

1. Identify all of the anatomical structures listed in this exercise.
2. Clearly explain the location of the human heart and its attached blood vessels to a person who has never had an anatomy class.
3. Describe and identify the three primary histological layers of the heart.
4. Describe and identify the three primary histological layers of an artery.
5. Identify the primary brain stem structure that controls heart rate.
6. Identify the skeletal structures surrounding the heart, and how you can use these bony landmarks to define the boundaries of the heart on a living person.
7. Be proficient with the review questions

INSTRUCTIONS:

Read through this exercise and complete any activities that appear in the readings.

SECTION 1: BACKGROUND INFORMATION

The heart is an organ of the cardiovascular system. Using blood as the transport vehicle, this system functions to transport substances around the body that are vital to **homeostasis**. The contracting heart is the primary force that sustains blood movement through the system.

SECTION 2: REVIEW MATERIAL

You should review the following tissues:

- cardiac muscle
- smooth muscle
- general epithelial
- adipose
- general connective

You should also review the medulla oblongata, (if you have already done brain dissection in lab) which has some control over heart contraction rate, and the skeletal structures around the heart.

SECTION 3: ORIENTATION

Your heart is a somewhat cone shaped organ, approximately the size of your own clenched fist. The heart is located in the medial cavity of the thorax (the mediastinum). It is flanked

Name: _____

laterally by the lungs, posteriorly by the vertebral column, and anteriorly by the sternum. The apex (lower point) of the heart extends slightly to the left of the body's midline and rests on the diaphragm around the area of the fifth intercostal space (between the fifth and sixth rib). The base (upper broad surface) of the heart lies just below the second rib and points towards the right shoulder. Usually, the lower right chamber (the right ventricle) of the heart rests towards the front of the thorax.

SECTION 4: BASIC HEART ANATOMY AND BLOOD VESSELS

You should be able to identify structures on illustrations, such as those found in your textbook and worksheets. If you can not identify all of your structures, then you should get out your textbook and worksheets and start memorizing them now.

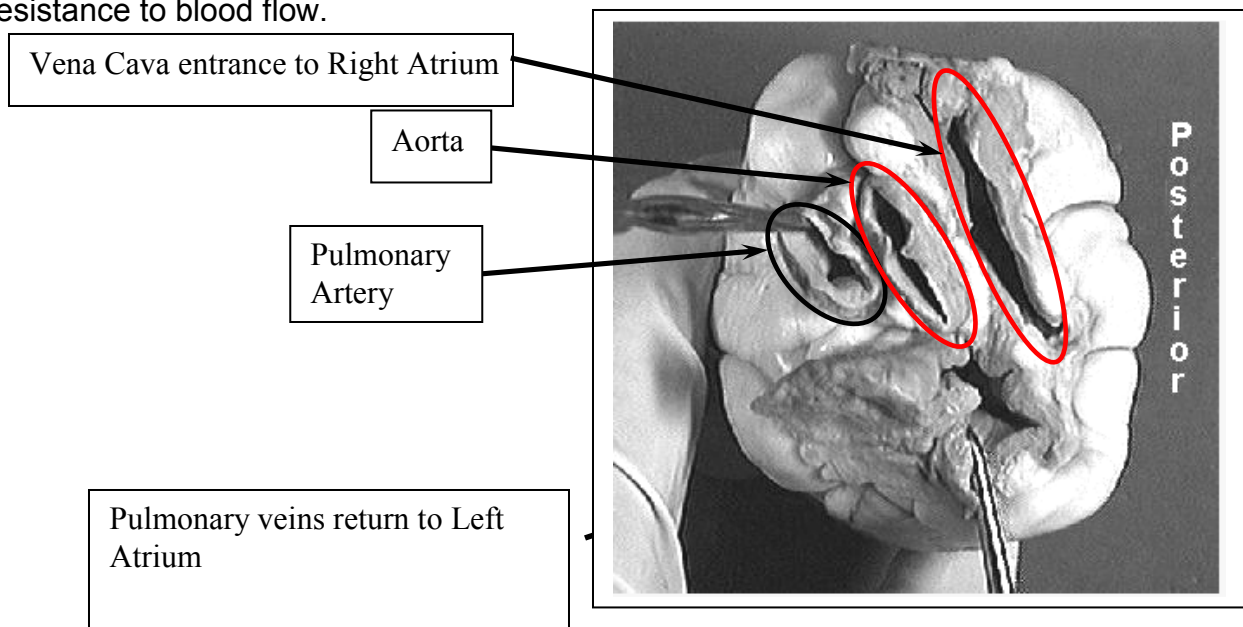
SECTION 5: ANATOMY OF AN ARTERY

Arteries are conducting vessels that carry blood away from the heart. The walls of arteries are constructed of three coats, or tunics. Starting outside and moving inward, the three "coats" are the tunica externa, the tunica media, and the tunica interna.

The tunica externa is the outermost coat. This layer is composed of fibrous connective or areolar tissue, and its primary function is to support and protect arteries.

The tunica media is the bulky middle coat and is composed primarily of smooth muscle (and elastic tissue). This layer regulates the diameter of an artery, which in turn alters resistance and blood pressure.

The tunica interna lines the lumen of an artery, and consists of a single layer of squamous cells. This layer of cells, along with its slight basement membrane, is called the endothelial layer. This endothelium is continuous with the endocardium, and is specialized to decrease resistance to blood flow.



Name: _____

SECTION 6: SHEEP HEART DISSECTION

Here are the basic steps you should follow when dissecting the sheep heart:

1. Gather your dissection equipment and a sheep heart.
2. Rinse the sheep heart thoroughly with cold water to remove excess preservatives and to flush out blood clots.
3. Observe the pericardium. If the pericardial sac is intact then remove the outer layer from its attachment points.
4. Carefully pull the **visceral pericardium (epicardium)** away from the **myocardium** (follow the same procedure described in step 3).
5. Examine the external surface of the heart. Notice the accumulation of adipose tissue. This adipose usually accumulates along the boundaries of the heart chambers and along the coronary arteries. Remove as much adipose as possible. Now you should be able to identify the apex (bottom left "point" of the heart) and the auricles (earlike flaps projecting from the atria).
6. Locate the pulmonary trunk and the aorta on the superior aspect of the heart. Clear the adipose away from these arteries. The pulmonary trunk divides into the left and right pulmonary arteries. The aorta will have a large branch coming from beneath the pulmonary trunk. This branch is the right brachiocephalic artery. The right brachiocephalic artery divides into the right subclavian and the right common carotid arteries. Notice the three distinct layers of all these arteries.
7. Starting at the apex and moving towards the base, make a coronal (frontal) cut through the heart. Stop cutting when your knife reaches the top portions of the atria.
8. Open the heart at the apex. Now you should be able to identify the remaining structures on your Hot List.
9. Notice that the heart is made up of three histological layers: the epicardium (which is the same as the visceral pericardium), the myocardium (literally "heart muscle"), and the endocardium ("inside the heart"). Locate the side with the thickest myocardial wall. This will orient you to the left side of the heart.
10. You should see that there are spaces (or "chambers") on the left and right sides of the lower heart. These are the left and right ventricles ("vent" referring to something coming out of the space, which is blood in this case).
11. You should also see a thick structure dividing the two ventricles, the bulk of which is comprised of **cardiac** muscle. This is the interventricular septum.
12. The ventricles are divided from the chambers directly above them by atrioventricular (or "AV") valves. These valves have flaps (or "cusps") to which "heart strings" attach. The left AV valve had two cusps, so it can be referred to as being a "bicuspid" valve. The right valve has three cusps, so it can be referred to as being a "tricuspid" valve.

Name: _____

13. The strings that attach to the AV cusps are called chordae tendinea.
14. The chordae tendineae are anchored to the ventricular walls via papillary ("nipple-like") muscles.
15. You will need to cut through the rest of your heart in order to identify the remainder of the Hot List structures.
16. Note that you will need to remove the right ventricular wall and cut into the pulmonary trunk in order to view the pulmonary valve (or right semilunar valve).
17. Properly dispose of all organic materials and clean your dissecting tools and trays before leaving lab

SECTION 7: EXPLORING VALVE ACTION

If time allows, you can imitate blood flow through the heart and observe valve action by doing the following activity:

1. Obtain an intact heart and locate the superior vena cava (SVC). Use your scissors to cut along the walls of the SVC in order to open up the right atrium. Do not cut through the entire atrial wall. Only cut enough so you can see the interior of the chamber.
2. Observe the **right A.V. valve** (the right A.V. Valve has "three flaps" or is "tricuspid" in structure).
3. Slowly pour water into the right atrium and allow it to flow into the right ventricle.
4. Gently squeeze the right ventricle and watch the closing action of the right A.V. Valve **WARNING:** Do not squeeze the ventricle too roughly or too quickly. If you do then be prepared to have water squirted on your face, in your mouth, nose, eyes, etc.
5. Drain the water from the heart.
6. Now go to the pulmonary trunk and cut down the front of its wall until you see the **pulmonary semilunar valve**.
7. Pour some water into the pulmonary trunk so it runs towards the right ventricle. Observe the closing action of this valve.

When you are done with this activity, answer the following question: How is the closing action of atrioventricular (cuspid) valves different from the closing action of semilunar valves?

Name: _____

SECTION 8: REVIEW QUESTIONS

1. The heart is an organ of this body system. _____
2. What is the muscular layer of the heart is called? _____
3. What is the name of the sac surrounding the heart? _____
4. What type of tissue comprises the bulk of the myocardium? _____
5. What is the function of the heart? _____
6. What is the function of an artery? _____
7. From outermost to innermost, what are the three layers of an artery?

8. What is the function of a vein? _____
9. What is the name of the space in a blood vessel wherein blood flows?

10. What is the lining of the heart called? _____
11. What is the primary brain stem structure that controls heart rate.

12. What is the specific space in the thoracic cavity where the heart is located?

13. What bone protects the heart anteriorly? _____
14. The bulk of the heart rests on this side of the body. _____
15. The pericardium attaches to this structure inferiorly. _____
16. Which side of the heart as a thicker ventricular wall? _____
17. What layer of an artery consists mostly of smooth muscle? _____
18. What chambers of the heart function to receive blood from the veins?

19. The tunica interna is continuous with this layer of the heart.

20. What part of the heart rests just below the right second rib?

21. What are the bottom two chambers of the heart called? _____
22. What valves are located between the atria and the ventricles?

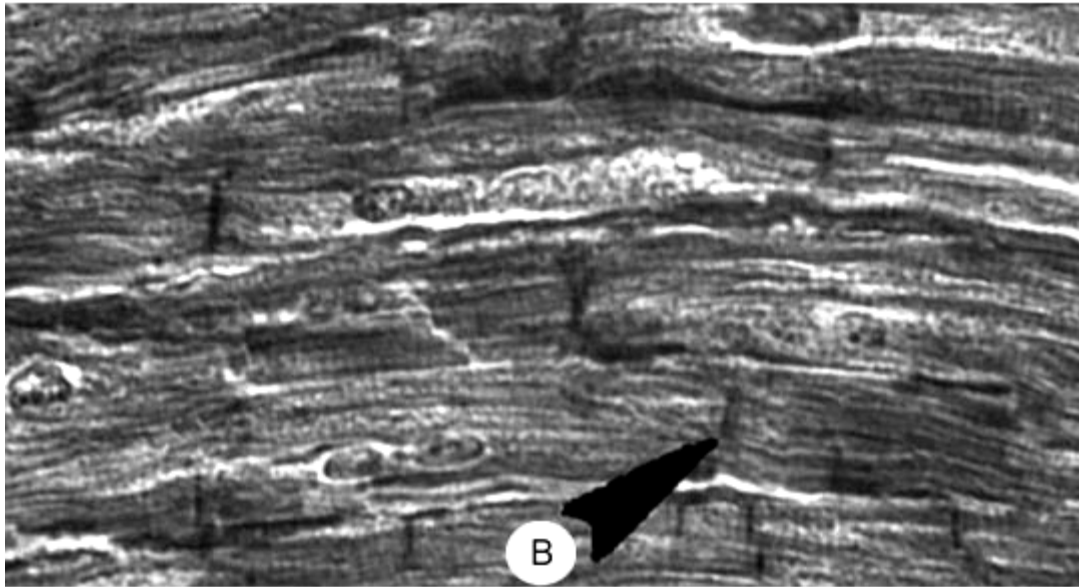
23. The apex of the heart points to this side of the body. _____
24. What is the branch of the aorta that divides into the right subclavian and right common carotid arteries? _____
25. What is the scientific term for the "heart strings" that extend from the AV cusps to the papillary muscles? _____
26. What structure divides the two ventricles of the heart? _____
27. The superior vena cava attaches to this heart chamber. _____
28. What is the largest artery of the human body? _____
29. What are the "ear-like" structures that extend from the atria? _____
30. The apex of the heart usually sits at the same approximate level as the space between these two ribs. _____

SECTION 9: PRACTICE TESTS

Test your knowledge with the following practice tests Real Heart Images

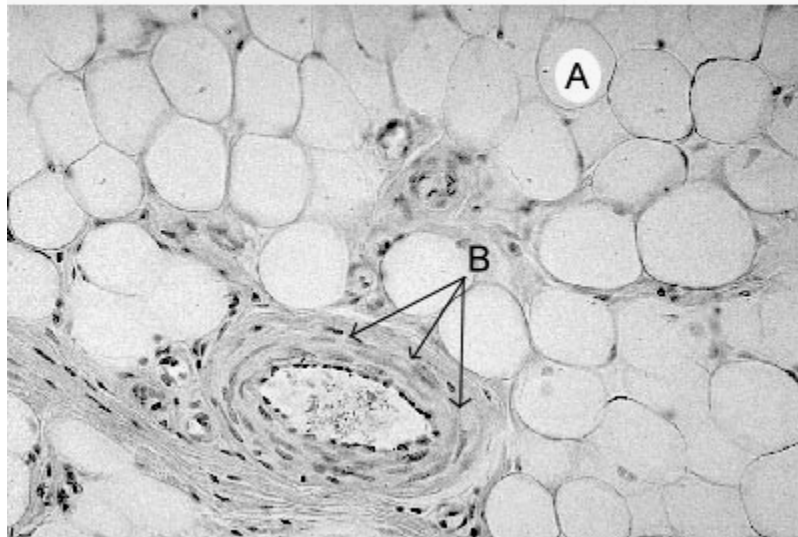
A) What type of tissue is this?

B) What is the arrow pointing towards?



A) What type of tissue is this?

B) What do you think the arrow is pointing at?
(Hint: Look at the different layers.)



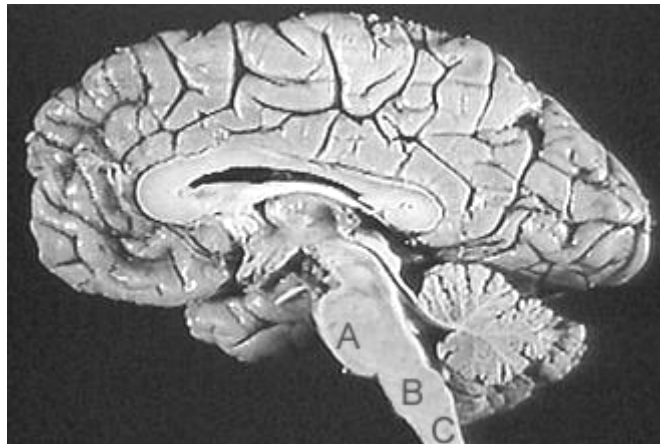
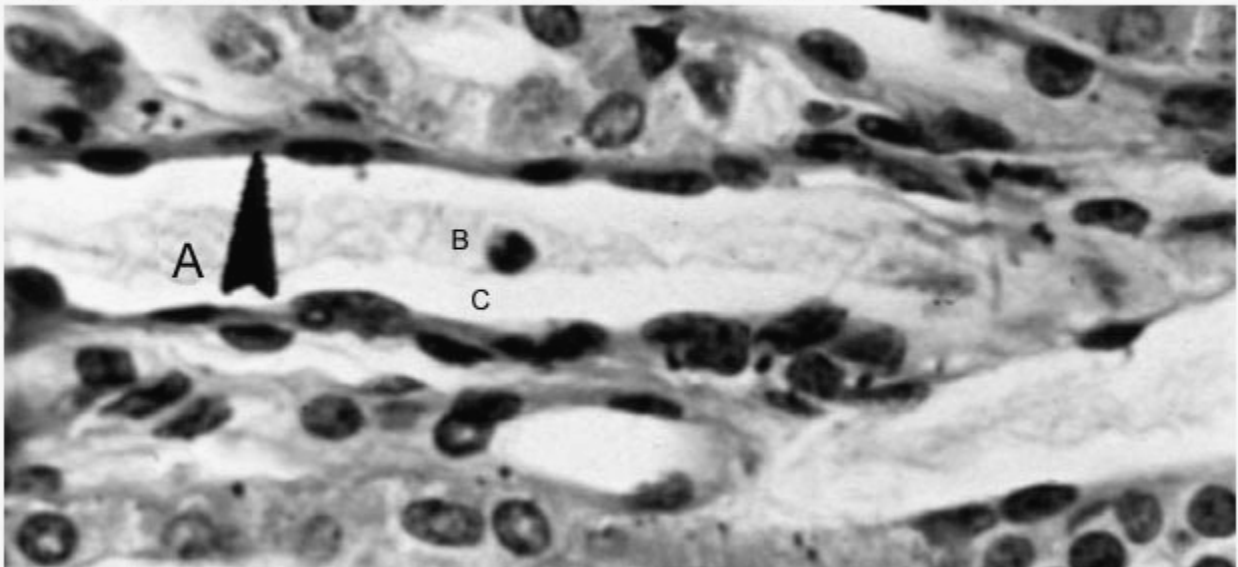
Name: _____

This is a section of a blood vessel.

Item "B" is on blood cells located within the vessel.

A) What layer is the arrow pointing at?

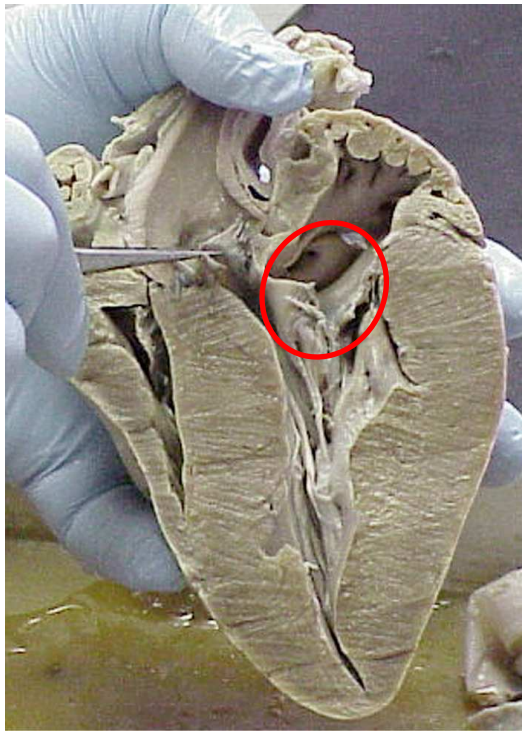
C) What is this space called?



The primary neural control of the heart originates in brain section (A / B / C). Choose one.

The name of this brain section is the _____.

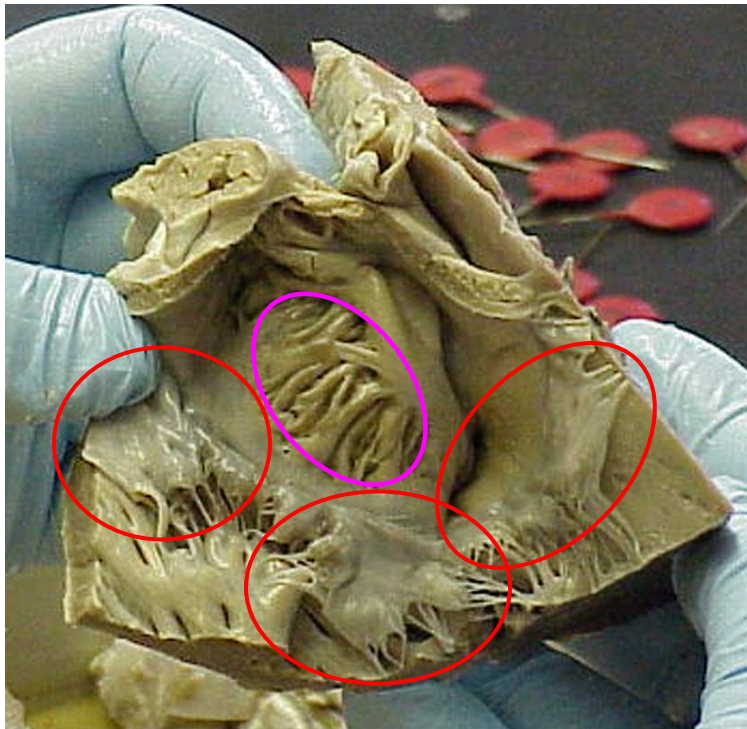
Name: _____



1. What structure are the tweezers holding?

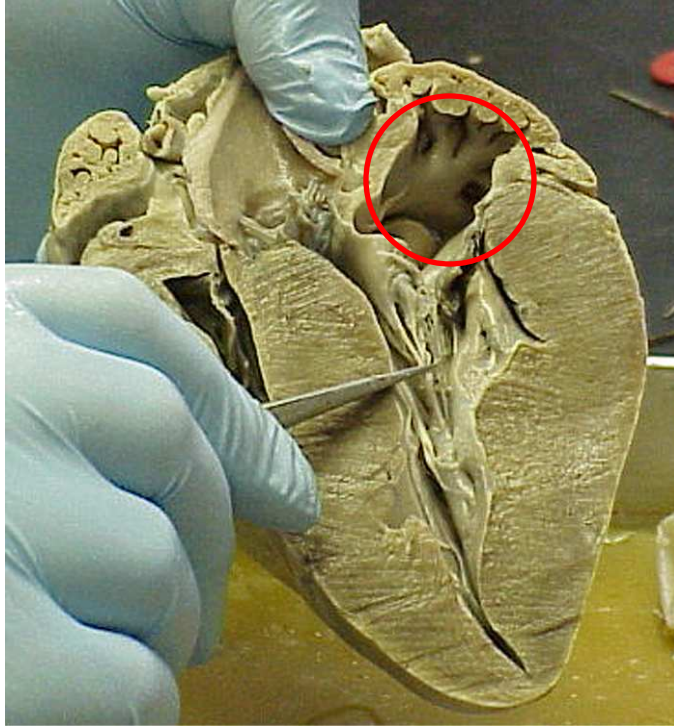
2. The two thin leaflets circled make up the

_____ valve.



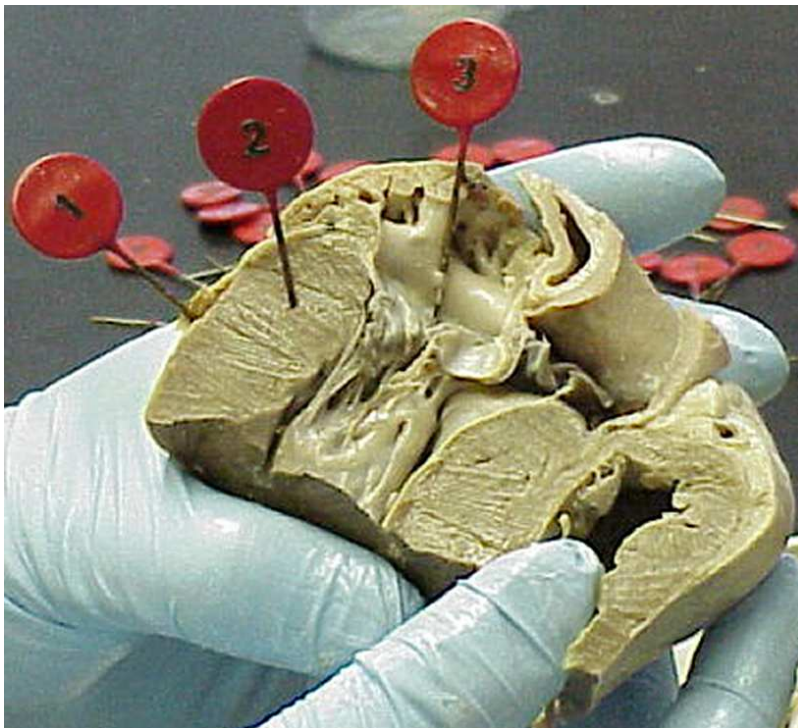
3. The beams and bridges circled are called

4. These three leaflet structures make up what structure?



5. What are the small string like structures held by the tweezers?

6. The chamber circled is the _____

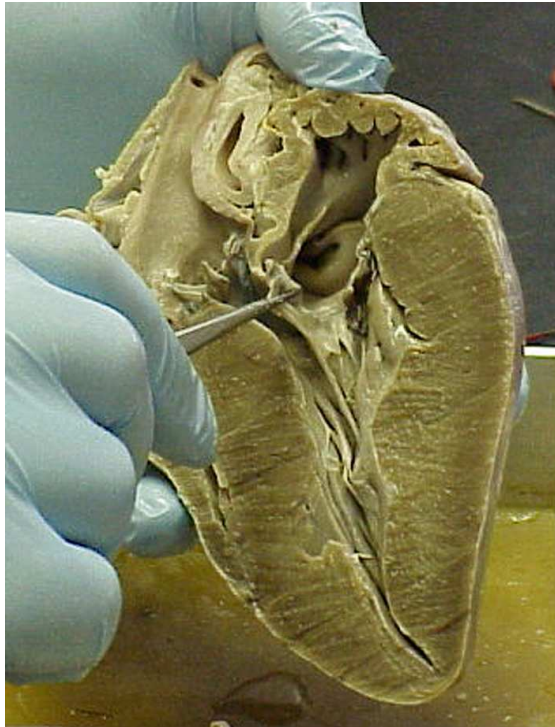

Tag 1. The outer layer of the heart is the
7. _____

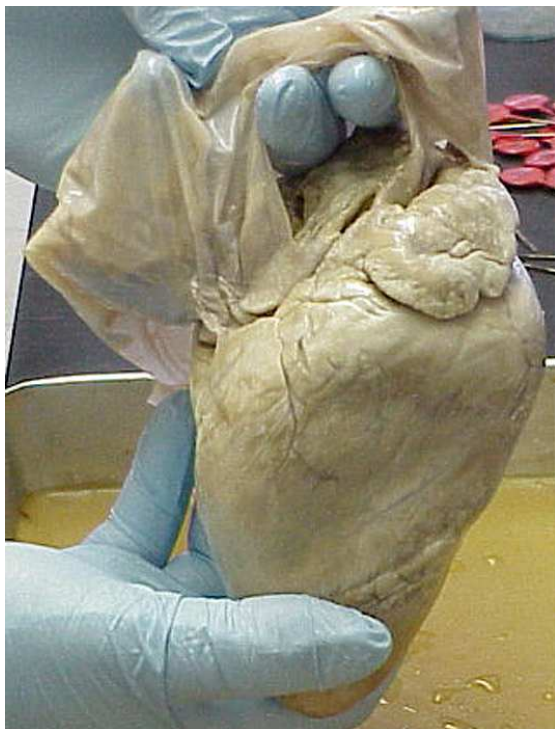Tag 2. The muscle mass is called the
8. _____

Tag 3. The inner layer of the heart is called the
9. _____

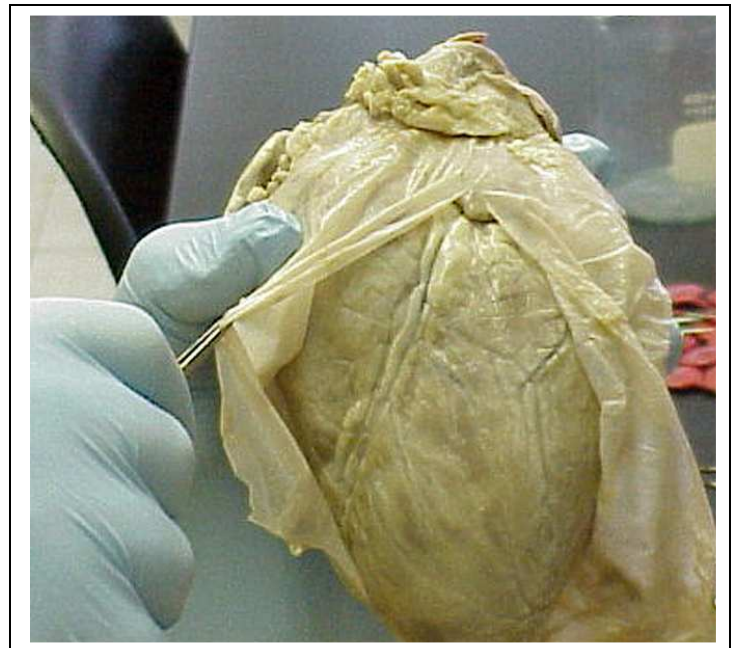
Name: _____



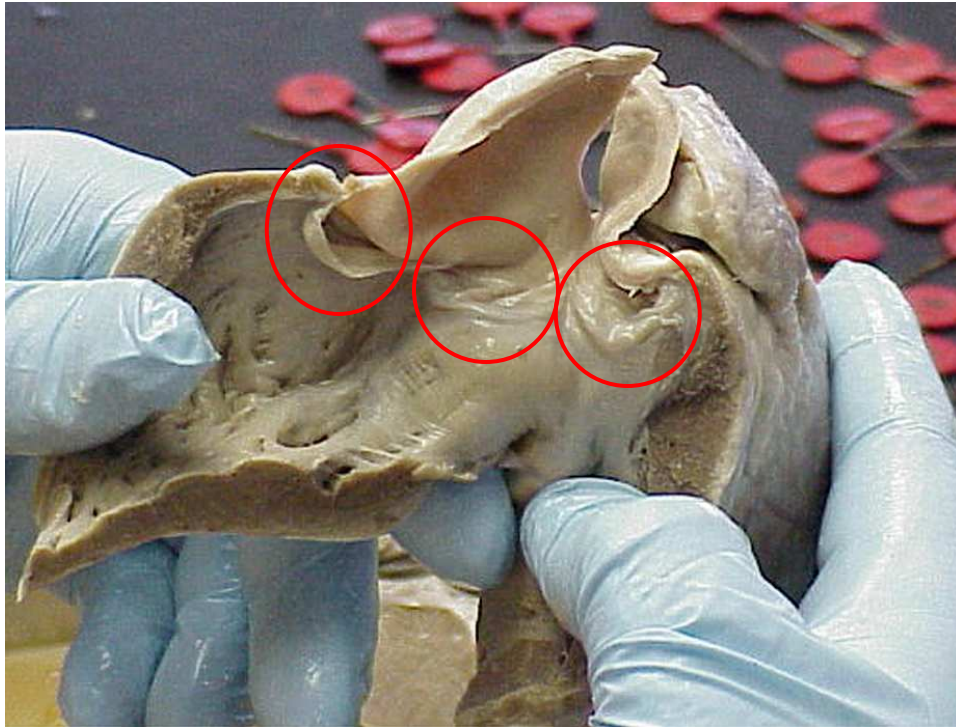
10. The structure in the grasp of the tweezers is the _____ valve.



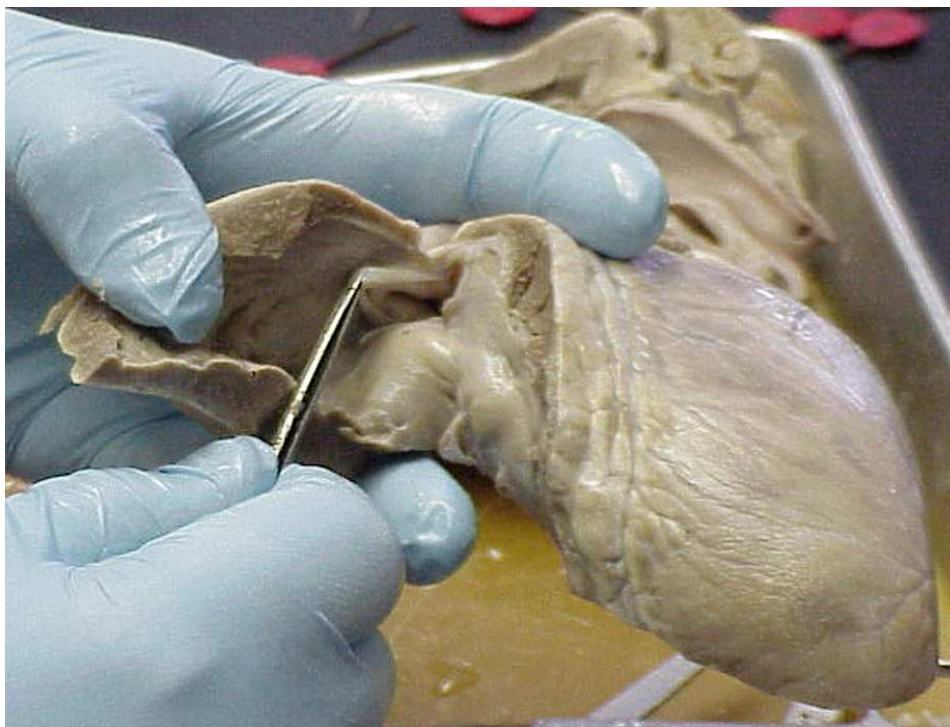11. The sheet-like structure being removed from the heart is the _____



Name: _____

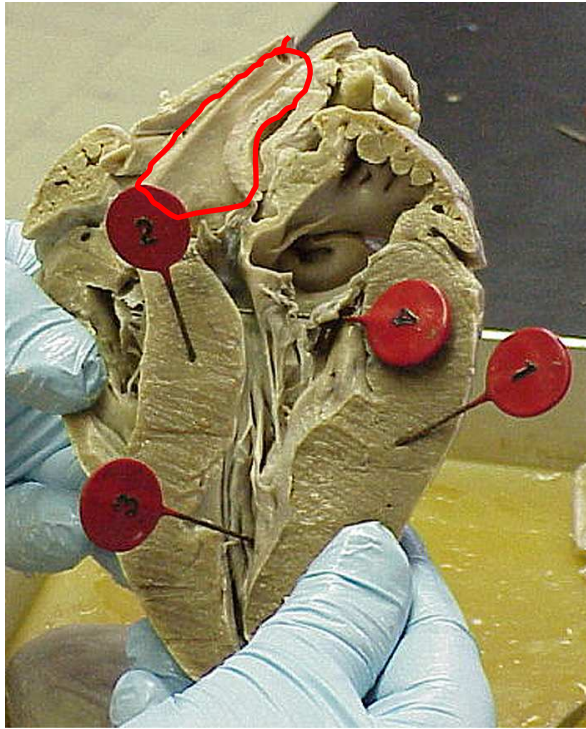


12. These three valve leaflets make up what valve? _____



13. This is another valve with similar structure to that above. What valve is it? _____

Name: _____



Tag 1. 14. This muscle mass is

the _____ of the

15. _____ ventricle.

Tag 2. This muscle mass is the intraventricular

16. _____

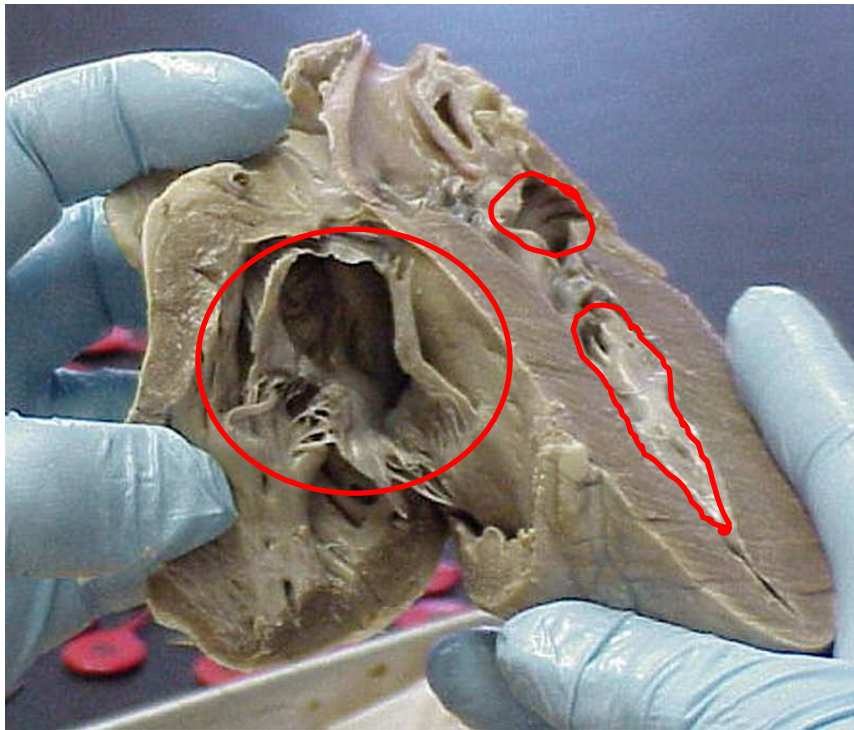
Tag 3. The ridges of tissue are called

17. _____

Tag 4. This is the

18. _____ valve.

19. The circled structure is the _____

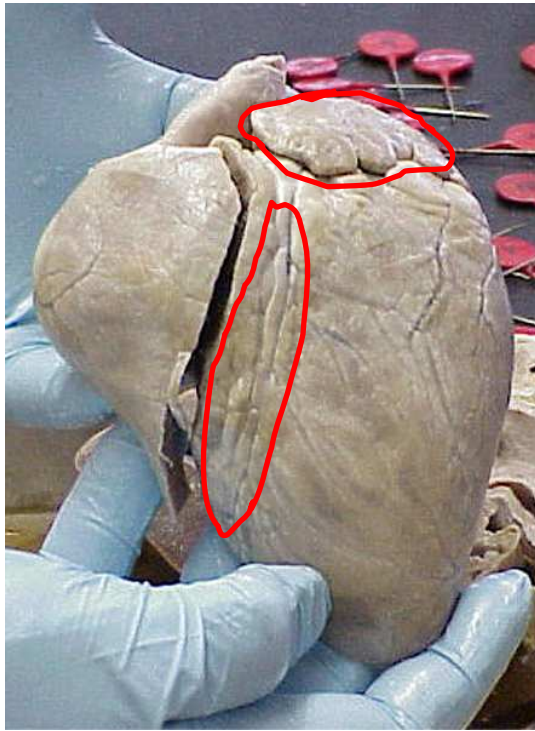


20. Name the upper chamber:

21. Name the Lower chamber:

22. Name the three leaflet structure:


Name: _____



23. The upper circled heart portion is called the

24. The lower marked area is known as the:

_____ sulcus.



25. Name the upper chamber: _____

26. Name the lower chamber: _____

27. The muscular protrusions into the chambers are called the

_____ muscles.