

Sporadic Inclusion-Body Myositis and Hereditary Inclusion-Body Myopathies

Diseases of Oxidative Stress and Aging?

Valerie Askanas, MD, PhD; W. King Engel, MD

Sporadic inclusion-body myositis and hereditary inclusion-body myopathies are progressive and highly debilitating muscle diseases. The most characteristic morphologic feature of sporadic inclusion-body myositis and hereditary inclusion-body myopathies is vacuolar degeneration of muscle fibers, accompanied by intrafiber clusters (“tangles”) of paired-helical filaments and by accumulation of several proteins that are characteristic of a brain of patients with Alzheimer disease. In neither the hereditary inclusion-body myopathies nor sporadic inclusion-body myositis are the sequential steps of the pathogenic cascade understood. The several forms of hereditary inclusion-body myopathies have different genetic transmissions and probably different genetic defects. Because the sporadic inclusion-body myositis and hereditary inclusion-body myopathies have several characteristic pathologic features in common, we postulate that their different causes trigger the same upstream aberration leading to a similar downstream cascade of pathologic events, which are ultimately responsible for the characteristic muscle-fiber degeneration. We propose that important contributory factors leading to the inclusion-body myositis–specific muscle fiber destruction are muscle aging and oxidative stress, putatively induced by the upstream overexpression of β -amyloid precursor protein within abnormal muscle fibers.

The term *inclusion-body myositis* (IBM) was introduced in 1971 by Yunis and Samaha¹ to describe a subset of patients with chronic polymyositis whose muscle biopsy specimens showed, in addition to inflammation, abnormal muscle fibers containing vacuoles and characteristic filamentous inclusions within the cytoplasm and nuclei. Sporadic IBM is now recognized as the most common muscle disease beginning after age 50 years. It is of unknown cause and pathogenesis and leads to severe disability.^{2,3}

In 1993 we introduced the term *hereditary inclusion-body myopathies*⁴ to designate hereditary muscle diseases with muscle pathologic features strikingly resembling those of sporadic IBM, except for a lack of lymphocytic inflammation (and a few other features, discussed later);

hence, the term “myopathy” instead of “myositis.” Hereditary IBM encompasses several autosomal recessive and dominant syndromes of progressive muscle weakness and various clinical presentations but similar features in the muscle biopsy specimen. The clinical onset of hereditary IBM is usually in the second or third decade.

Since the pathologic phenotype of hereditary IBM is now well defined, a hereditary muscle disease whose muscle biopsy specimen contains vacuoles and characteristic IBM-type inclusions and other features (see below) should be considered a type of hereditary IBM and then further subclassified when a unique pathologic abnormality is identified. For example, the less precise general term, *distal myopathy*, in relation to the hereditary IBM syndromes is not desirable because it includes several other syndromes with different pathologic phenotypes from

From the Neuromuscular Center, Department of Neurology, University of Southern California School of Medicine, Good Samaritan Hospital, Los Angeles.

Table 1. Classification of Hereditary Inclusion-Body Myopathies (IBMs)

Classification	Chromosome	Gene	Patients
Autosomal recessive (AR-IBM)			
Quadriceps spared AR1a	9p1-q1	?	Persian (Iranian) Jews Afghani Jews India family Japanese* Mexican family Others
AR1b	?(not 9p1-q1)	?	Persian (Iranian) Jewish family†
Quadriceps not spared AR2	?	?	French-Canadian family‡ Others
Autosomal dominant (D-IBM)			Swedish "distal myopathy" Finnish "tibial muscular dystrophy" Denver, Colo, family Chicago, Ill, family Los Angeles, Calif, Mexican family Pennsylvania family Others

*Previously "distal myopathy with rimmed vacuoles."

†Pseudodominant (cousin marriage).

‡Family has central nervous system abnormality.

hereditary IBM. It is now apparent that several muscle diseases previously designated as "distal myopathies" are indeed hereditary IBMs, based on their muscle structure and the newest genetic studies. As we proposed in 1995,² the Japanese "distal myopathy with rimmed vacuoles" is the same "quadriceps-sparing hereditary IBM" that occurs in Persian Jewish patients, based both on characteristic muscle pathologic characteristics⁵ and linkage to the same locus on chromosome 9p1-q1.⁶⁻⁸ Other ethnic groups with quadriceps-sparing autosomal recessive hereditary IBM also link to chromosome 9p1-q1.^{9,10} Some of the dominant syndromes previously designated as distal myopathies, eg, Welander myopathy, also have morphologic features of IBM on biopsy specimens and should be considered hereditary IBM. Our current classification of the hereditary IBM syndromes is shown in **Table 1**.

CHARACTERISTIC FEATURES OF IBM MUSCLE BIOPSY SPECIMENS

Light-microscopic features of a muscle biopsy specimen include various degrees of lymphocytic mononuclear cell inflammation, muscle fibers with vacuoles containing red and green staining material with the Engel-Gomori trichrome reaction, ragged-red fibers, cytochrome *c* oxidase-negative muscle fibers, and atrophic muscle fibers.^{2,3} On a given section, 60% to 80% of the vacuolated muscle fibers contain foci positive with Congo red, thioflavine S, or crystal violet, all of which denote amyloid.^{3,11}

By electron microscopy, the most characteristic feature of the vacuolated muscle fibers is the presence of cytoplasmic 15- to 21-nm diameter paired helical filaments, which strikingly resemble paired helical filaments in the brain of patients with Alzheimer disease (AD) and similarly contain phosphorylated tau.^{2,3} Those inclusions were previously described simply as "filaments" or as "tubulofilaments."²

A remarkable feature of sporadic IBM vacuolated muscle fibers is abnormal accumulation within them of a group of proteins that are abnormally accumulated in the brain of patients with AD. These include β -amyloid protein, C- and N-terminal regions of β -amyloid precursor protein (β APP), apolipoprotein E, ubiquitin, α_1 -antichymotrypsin, and superoxide dismutase 1 (SOD1). The amount of β APP messenger RNA (mRNA) is increased in sporadic and hereditary IBM vacuolated muscle fibers.^{2,3}

Cellular prion protein and its mRNA are also accumulated within sporadic IBM vacuolated muscle fibers.^{2,3}

HEREDITARY IBM

Most of the pathologic features of the muscle biopsy specimen in patients with hereditary forms of IBM are similar to those of sporadic IBM, but hereditary IBM muscle biopsy specimens lack lymphocytic mononuclear cell inflammation. In contrast to the abnormal muscle fibers of sporadic IBM, in hereditary IBM, most of the vacuolated muscle fibers do not stain for Congo red positivity, and typically, ragged-red fibers and cytochrome *c* oxidase-negative muscle fibers are not present.³ Also in contrast to the features of sporadic IBM, in hereditary IBM, paired helical filaments lack some epitopes of phosphorylated tau, are not congophilic, and do not contain apolipoprotein E.³ **Table 2** and **Table 3** illustrate pathologic similarities and differences between sporadic and hereditary IBMs. Mitochondrial DNA deletions are common in sporadic IBM¹²⁻¹⁴ but are not present in Persian Jewish patients with autosomal recessive hereditary IBM,¹⁴ except in our oldest (46-year-old) patient.¹⁴ Therefore, in patients with hereditary IBM, compared with those with sporadic IBM, muscle pathologic features seem somewhat "less advanced." Possible reasons for this phenomenon are discussed below.

PUTATIVE PATHOGENIC MECHANISM(S) OF SPORADIC AND HEREDITARY IBM

The pathogenic cascade in either hereditary or sporadic IBM is not well understood. The several forms of hereditary IBM have different genetic transmission and probably have different genetic defects. The cause of sporadic IBM with its typical lymphocytic inflammatory aspect is presumably different but still unknown (possibly viral).^{2,3} Because sporadic IBM and the recessive and dominant forms of hereditary IBM have several characteristic pathologic features in common, we postulated that different causes in the IBMs lead to a downstream common pathologic cascade that is ultimately responsible for the characteristic vacuolar muscle fiber degeneration.^{2,3,8}

We now discuss factors that possibly contribute to the pathogenesis of IBM.

Table 2. Pathologic Phenotype of Sporadic and Hereditary Inclusion-Body Myositis (IBMs)*

Pathological Features	Sporadic IBM	Hereditary IBMs
Similarities		
Vacuolated muscle fibers	+	+
Ubiquitin†	+	+
β-Amyloid precursor protein†	+	+
β-Amyloid precursor protein mRNA	+	+
Prion protein†	+	+
Prion protein mRNA	+	+
Neuronal NO synthase†	+	+
Inducible NO synthase†	+	+
Phosphorylated tau† with antibodies		
SMI-31	+	+
AT8	+	+
Differences		
Inflammation	+	-
Ragged-red fibers	+	-
COX-negative muscle fibers	+	-
Congo red	+	-
Phosphorylated tau† with antibodies		
SMI-310	+	-
PHF-1	‡§	‡§
Apolipoprotein E†	‡§	‡§
Nitrotyrosine†	‡§	‡

*Plus sign indicates the presence of or a positive reaction to; minus sign, the absence of or a negative reaction to; mRNA, messenger RNA; NO, nitric oxide; and COX, cytochrome c oxidase.

†Immunoreactivity.
‡Defined inclusions.
§Diffuse.
||Multiple dots.

OXIDATIVE STRESS AS A POSSIBLE FACTOR IN THE PATHOGENIC CASCADE OF SPORADIC AND HEREDITARY IBM

Recently, there has been increasing evidence that free radical toxicity may participate in IBM pathogenesis. Superoxide dismutase-1 and superoxide dismutase-1 mRNA were increased in vacuolated muscle fibers of patients with sporadic and hereditary IBM,³ suggesting an attempted protective response in these fibers to pathologically increased superoxide. Superoxides can rapidly combine with nitric oxide (NO) to form the very toxic peroxynitrite, which can then pathologically nitrate tyrosine groups on proteins to form nitrotyrosine.¹⁵ Neuronal and inducible forms of NO synthase, which produce NO, and nitrotyrosine are abnormally accumulated in vacuolated muscle fibers of sporadic and hereditary IBM.³ The presence of nitrotyrosine is indicative of NO-induced oxidative stress.¹⁵ To our knowledge, the IBMs are the first muscle diseases in which NO-induced oxidative stress has been demonstrated. Our most recent studies indicate abnormal lipid peroxidation in sporadic IBM.¹⁶

The reason(s) for increased superoxides, NO synthases, nitrotyrosine, and abnormal lipid peroxidation in sporadic IBM and the hereditary forms of IBM is not yet known. Various proteins are abnormally accumulated in IBM muscle fibers, but the role each plays in the pathogenic cascade is not understood. Not known also is whether one of the proteins initiates the cascade, caus-

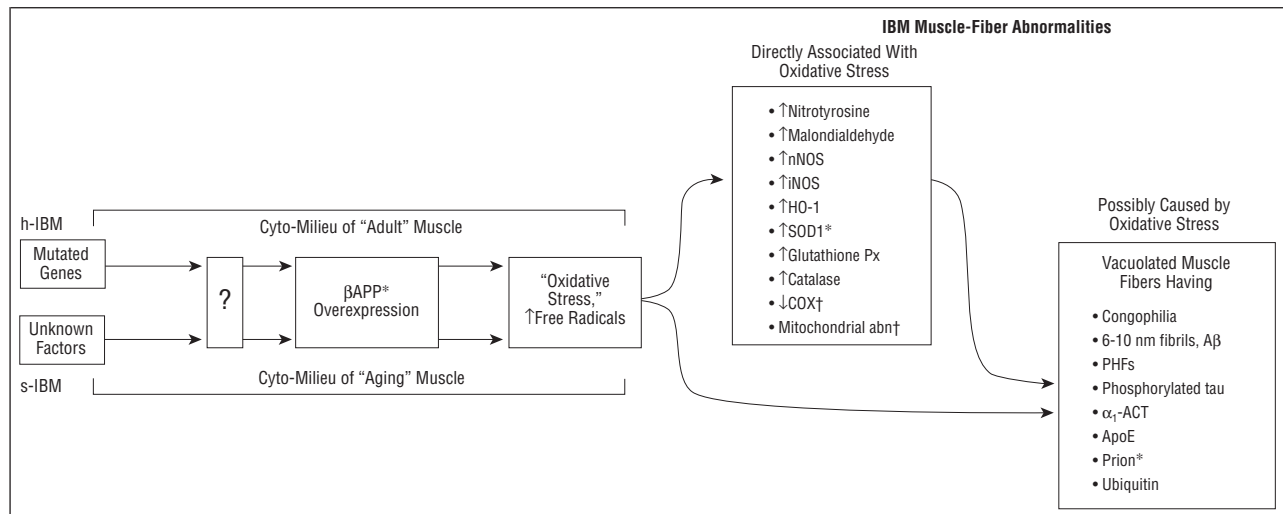
Table 3. Ultrastructural Immunoreactivities of Various Proteins on Paired Helical Filaments (PHFs) of Sporadic and Hereditary Inclusion-Body Myositis (IBMs)*

Protein	PHFs	
	Sporadic IBM	Hereditary IBMs
Similarities		
β-Amyloid precursor protein†	-	-
Ubiquitin†	+	+
Prion protein†	+	+
Neuronal NO synthase†	+	+
Inducible NO synthase†	+	+
Phosphorylated tau† with antibodies		
SMI-31	+	+
AT8	+	+
Differences		
Apolipoprotein E†	+	-
Nitrotyrosine†	+	-
Phosphorylated tau† with antibodies		
SMI-310	+	-
PHF-1	+	-
Non-electron-microscopic difference		
Congophilia	+	-

*Minus sign indicates absence of or negative reaction to; plus sign, presence of or positive reaction to; and NO, nitric oxide.
†Immunoreactivity.

ing accumulation of other proteins and possibly culminating in oxidative stress; or whether the oxidative stress induces various protein abnormalities. One possibility is that the known and yet-unknown mitochondrial abnormalities, including respiratory chain dysfunctions, in sporadic IBM¹²⁻¹⁴ are responsible for the generation of reactive oxygen species, which then produce the manifestations of oxidative stress. However, this mechanism is unlikely to play a role in the hereditary IBMs because their muscle biopsy specimens do not have detectable mitochondrial abnormalities.^{2,3,14}

We postulate that the accumulation of βAPP, β-amyloid protein, or both within muscle fibers is an early step in the pathogenic cascade common to all forms of sporadic and hereditary IBMs. β-Amyloid protein can induce oxidative stress in a variety of cells.¹⁷ In both the sporadic and the hereditary forms of IBM, abnormal accumulations of βAPP, including its β-amyloid protein portion, and of β-amyloid protein separately in 6- to 10-nm fibrils, occur very early in the disease process and precede other abnormalities, including congophilia, within the vacuolated muscle fibers.^{2,3} A key step facilitating the cascade of pathologic events that results in IBM we hypothesize to be the overproduction of βAPP, which causes cellular disturbance that leads to an increased generation of free radicals, culminating in oxidative stress. The **Figure** illustrates our hypothetical model of this pathogenic aspect of sporadic and hereditary IBMs. In accordance with this hypothesis is our recent demonstration that βAPP overexpression mediated by βAPP gene transfer into cultured normal human muscle fibers induces several aspects of the IBM phenotype, including vacuolization, mitochondrial cytochrome c oxidase deficiency, structural mitochondrial abnormalities, and increased production of SOD1 and SOD1 mRNA.³



Genetic defects in hereditary inclusion-body myopathies (h-IBM) and various factors (including a putative virus) in sporadic inclusion-body myositis (s-IBM) lead to unknown mechanisms (? box in diagram). These up-regulate β -amyloid precursor protein (β APP) transcription, resulting in β APP overexpression. In the cyto-milieu of "aging muscle" of s-IBM or of "adult muscle" of h-IBM, overexpression producing excessive β APP (the whole molecule or its β -amyloid protein [A β] fragment) leads to "oxidative stress" with increased free radicals, which contribute to producing abnormalities demonstrated as IBM muscle fiber abnormalities. Those abnormalities can be considered either directly associated with oxidative stress or possibly caused by oxidative stress. Perhaps some of the former contribute to producing (directly or indirectly) some of the latter. nNOS indicates neuronal nitric oxide synthase; iNOS, inducible NOS; HO-1, heme-oxygenase-1; SOD1, superoxide dismutase 1; Px, glutathione peroxidase; COX, cytochrome c oxidase; abn, abnormalities; PHFs, paired helical filaments; α_1 -ACT, α_1 -antichymotrypsin; ApoE, apolipoprotein E; asterisk, increased protein and messenger RNA; dagger, it is present in virtually all patients with s-IBM and in the older patients with h-IBM; upward arrow, increased amount; and downward arrow, decreased amount.

Therefore, oxidative stress is suspected to be an important contributory factor in IBM pathogenesis. If this is true, a possible therapeutic avenue for the various forms of IBM is to reduce the amount of free radicals or to prevent their formation in affected muscle fibers.

MUSCLE AGING AS A POSSIBLE CONTRIBUTORY FACTOR IN THE DEVELOPMENT OF SPORADIC AND HEREDITARY IBM

Sporadic IBM becomes clinically manifest after age 50 years and more often in the 60s and 70s. The etiologic factor (or factors) is not known. We consider that in sporadic IBM, 3 overlapping aspects of muscle fiber destruction exist. One is an attack on muscle fibers by cytotoxic T lymphocytes, which is prominent early in the involvement of a muscle and usually less evident in later stages; the second is a vacuolar degeneration, somewhat less in early stages compared with greater involvement in later stages; and the third is muscle fiber atrophy (which often resembles denervation atrophy), also more prominent in later stages. The composition of the lymphocytic infiltrates is similar to that in ordinary polymyositis.¹⁸ In contrast to patients with polymyositis, patients with sporadic IBM as a group respond poorly to anti-inflammatory treatment, possibly because of an unresponsiveness of mechanisms that cause the vacuolar degeneration and muscle fiber atrophy. We have not seen a patient older than 50 years with what could be considered "pure polymyositis"; all of those patients with inflammation in muscle biopsy specimens had features of sporadic IBM. We raise the possibility that the milieu of aged muscle fibers (1) modifies the response to inflammation and promotes the development of IBM-characteristic vacuolar degeneration or (2) is preferentially susceptible to a putative virus causing sporadic IBM.

We further postulate that within the aged muscle fibers, there are diminished cellular defense mechanisms caused either by the overexpression of yet-unknown genes encoding putatively detrimental cellular factors that become activated in an aged cellular environment or by an underexpression of "youthful" genes encoding putatively beneficial cellular factors. This mechanism subsequently may lead to muscle fiber cellular death, vacuolar degeneration, or atrophy due to an increased accumulation of unknown toxic substances.

In accordance with this concept is the possibility that in sporadic IBM, a virus dormant for years may become activated in an aged cellular milieu due to decreased cellular defense mechanisms (analogous to the phenomenon of the human T-lymphotropic virus type 1 [HTLV-1] acquired in infancy through mother's milk not becoming clinically pathogenic until the fifth through the seventh decade of life¹⁹). We have proposed that a virus causes sporadic IBM, including the mitochondrial abnormalities, oxidative stress, protein accumulations, and altered transcriptions,^{2,3} but for most patients with sporadic IBM, a putative virus has not been found. One patient of ours (from an area of Iran endemic for HTLV-1) with typical sporadic IBM had a positive reaction for HTLV-1 on enzyme-linked immunosorbent and Western blot assays and for leukocytes on polymerase chain reaction and had HTLV-1 p19 antigen detected immunohistochemically in his vacuolated muscle fibers.²⁰ These results in this patient enhance the suspicion of a viral cause in other patients with sporadic IBM.

In the hereditary forms of IBM, causative abnormal genes existing since birth do not become manifest until about the second or third decade of life. We postulate that a specific hereditary IBM genetic defect, combined with the milieu of the early-adult muscle fiber, leads to the IBM-characteristic vacuolar degeneration. The ob-

served less-advanced pathologic changes of the hereditary forms of IBM in comparison with the sporadic IBM might be due to the less-aged intracellular environment, a lack of lymphocytic inflammation, or an enhancing specific hereditary IBM genetic milieu within the muscle fibers.

POSSIBLE RELEVANCE TO AD PATHOGENESIS

Because the same proteins accumulate within sporadic and hereditary IBM muscle fibers as accumulate in the brain of sporadic and hereditary forms of AD, these diseases might have pathogenic similarities, and knowledge of one might help elucidate the other. Cellular aging and evidence of oxidative stress are associated with both AD²¹ and the various forms of IBM. Within the IBM and the AD groups, the sporadic and hereditary forms are morphochemically similar. Different forms of hereditary IBM are probably caused by different genes that appear to lead to a common downstream final pathogenic cascade that is ultimately responsible for the characteristic vacuolar muscle fiber degeneration. This would be the same principle as in AD, in which at least 4 different genes (and other unknown factors) lead to the same pathologic phenotype in the brain.²²

One protein, prion, accumulates in IBM vacuolated muscle fibers but does not accumulate in the brain of patients with AD; it does, however, accumulate in the brain of patients with sporadic and hereditary prion diseases. In prion brain diseases, the amount of prion mRNA is not increased, but instead a unique mechanism of transmissible/inducible prion protein disfiguration, aggregation, and insolubilization has been proposed to account for prion protein accumulation.²³ Because IBM muscle fibers have increased prion mRNA, we suggest that increased prion protein in them is related to enhanced mRNA-directed synthesis. In this respect, the IBMs are different from the prion brain diseases.

Relatively easy access to sporadic and hereditary IBM muscle biopsy specimens and the fact that sporadic and hereditary IBM human muscle (in contrast to adult human neurons of AD and prion brain diseases) can be cultured to a rather mature state for an extended period of time make this abnormal human muscle tissue a valuable material from which to glean insight into the pathogenesis of these degenerative muscle diseases and, by inferential analogy, possibly shed light on the degenerative brain diseases having pathologic similarities.

PUTATIVE "JUNCTIONALIZATION" OF NONJUNCTIONAL REGIONS OF MUSCLE FIBERS IN IBM

Several of the accumulated "IBM proteins" and the increased "IBM mRNAs" are, in mature muscle fibers, ones normally found only at the postsynaptic region of the neuromuscular junction (NMJ) (eg, β AAPP, prion, SOD1, neuronal and inducible NO synthase, ubiquitin, α_1 -antichymotrypsin, apolipoprotein E, and the mRNAs of β AAPP and prion [tau is not accumulated at the normal NMJ]²⁴). We have termed the normal phenomenon of protein and mRNA accumulation at the NMJ *junctionalization*.^{2,3,24} It

is induced by the contacting motor neuron axonal tip and presumably is governed, at least partially, by enhanced expression of the genes of those "junctional proteins" by the junctional (subs synaptic) nuclei of the muscle fiber. Normally, during NMJ development, there is concurrent down-regulation of the junctional-protein genes in the nonjunctional nuclei located throughout the muscle fiber other than at the NMJ. Because most of the proteins (except tau) that accumulate in the IBMs in the form of inclusions scattered throughout the abnormal muscle fibers are normal junctional proteins, we proposed that in sporadic and hereditary IBM, there is junctionalization of extrajunctional regions of the muscle fiber, associated with altered gene expression in the previously nonjunctional nuclei. This junctionalization could possibly be induced, directly or indirectly, by a putative virus in sporadic IBM and the product of a mutated gene in hereditary IBM, perhaps abetted by reactive oxygen species and aged-milieu factors.

CONCLUSIONS

Sporadic IBM and the hereditary forms of IBM are progressively debilitating muscle diseases. Despite considerable recent progress, the detailed pathogenesis are not known, and consistently successful treatment is not available (although single-dose, alternate-day prednisone, eg, 20-60 mg, can provide slight to moderate benefit for some patients with sporadic IBM³). Knowledge of the abnormal genes causing the hereditary forms of IBM and how they affect the muscle fiber, coupled with detailed analyses of possible factors causing sporadic IBM, should lead to a clarification of the proposed downstream common cascade that produces the characteristic IBM type of vacuolar muscle-fiber degeneration. Learning the steps of that putative common cascade might lead to a common method of treating and preventing the muscle fiber vacuolar degeneration even *before* their respective upstream pathogenesis will be discovered and become clinically treatable.

The past several years produced rapid advances in knowledge of the aging brain and the possible role of oxidative stress in neurodegenerations.²¹ However, there are virtually no studies regarding the molecular aspects of human muscle aging and its prevention. We predict that as the population ages, sporadic IBM will become a more common cause of disability. Further studies of muscle aging should augment the understanding of IBM pathogenesis and lead to defining molecular targets for precise therapeutic intervention.

Accepted for publication January 5, 1998.

Supported in part by grants NS31836 and NS34103 from the National Institutes of Health, Bethesda, Md; the Muscular Dystrophy Association, Tucson, Ariz; and the University of Southern California Neuromuscular Center Research Fund, Los Angeles.

Reprints: Valerie Askanas, MD, PhD, Neuromuscular Center, Department of Neurology, University of Southern California School of Medicine, Good Samaritan Hospital, 637 S Lucas Ave, Los Angeles, CA 90017-1912.

REFERENCES

1. Yunis EJ, Samaha FJ. Inclusion-body myositis. *Lab Invest*. 1971;25:240-248.
2. Askanas V, Engel WK. New advances in the understanding of sporadic inclusion-body myositis and hereditary inclusion-body myopathies. *Curr Opin Rheumatol*. 1995;7:486-496.
3. Askanas V, Engel WK. Newest approaches to diagnosis and pathogenesis of sporadic inclusion-body myositis and hereditary inclusion-body myopathies, including molecular-pathologic similarities to Alzheimer disease. In: Askanas V, Serratrice G, Engel WK, eds. *Inclusion-Body Myositis and Myopathies*. Cambridge, England: Cambridge University Press; 1998:3-78.
4. Askanas V, Engel WK. New advances in inclusion-body myositis. *Curr Opin Rheumatol*. 1993;5:732-741.
5. Murakami N, Ihara Y, Nonaka I. Muscle fiber degeneration in distal myopathy with rimmed vacuole formation. *Acta Neuropathol (Berl)*. 1995;89:29-34.
6. Ikeuchi T, Asaka T, Saito M, et al. Gene locus for autosomal recessive distal myopathy with rimmed vacuoles maps to chromosome 9. *Ann Neurol*. 1997;41:432-437.
7. Mitrani-Rosenbaum S, Argov Z, Blumenfeld A, Seidman CD, Seidman JG. Hereditary inclusion-body myopathy maps to chromosome 9p1-q1. *Hum Mol Genet*. 1996;5:159-163.
8. Askanas V. New developments in hereditary inclusion-body myopathies. *Ann Neurol*. 1997;41:421-422.
9. Argov Z, Tiram E, Eisenberg I, et al. Various types of hereditary inclusion-body myopathies map to chromosome 9p1-q1. *Ann Neurol*. 1997;41:548-551.
10. Middleton LT, Christodoulou K, Askanas V, et al. Molecular genetics of autosomal-recessive hereditary inclusion-body myopathy (AR-IBM) [abstract]. *Ann Neurol*. 1997;42:414.
11. Mendell JR, Sahenk Z, Gales T, Paul L. Amyloid filaments in inclusion-body myositis. *Arch Neurol*. 1991;48:1229-1234.
12. Oldfors A, Moslemi A-R, Fyhr I-M, Holme E, Larsson N-G, Lindberg C. Mitochondrial DNA deletions in muscle fibers in inclusion-body myositis. *J Neuropathol Exp Neurol*. 1995;54:581-587.
13. Santorelli FM, Sciacco M, Tanji K, et al. Multiple mitochondrial DNA deletions in sporadic inclusion-body myositis: a study of 56 patients. *Ann Neurol*. 1996;39:789-795.
14. Desnuelle C, Paquis V, Paul R, et al. mtDNA analysis in muscle of patients with sporadic inclusion-body myositis and hereditary inclusion-body myopathy. In: Askanas V, Serratrice G, Engel WK, eds. *Inclusion-Body Myositis and Myopathies*. Cambridge, England: Cambridge University Press; 1998:318-328.
15. Beckman JS, Koppenol WH. Nitric oxide, superoxide, and peroxynitrite: the good, the bad, and the ugly. *Am J Physiol*. 1996;271:C1424-C1437.
16. Broccolini A, Engel WK, Alvarez RB, Thomas CE, Yang C-C, Askanas V. Possible pathogenic role of malondialdehyde, a toxic product of lipid peroxidation, in inclusion-body myositis [abstract]. *Neurology*. 1998;50:367-368.
17. Butterfield DA. β -Amyloid-associated free radical oxidative stress and neurotoxicity: implications for Alzheimer's disease. *Chem Res Toxicol*. 1997;10:495-506.
18. Dalakas MC, Sivakumar K. The immunopathologic and inflammatory differences between dermatomyositis, polymyositis and sporadic inclusion-body myositis. *Curr Opin Neurol*. 1996;9:235-239.
19. Hino S, Doi H. Mechanisms of HTLV-1 transmission. In: Román GC, Vernant J-C, Osame M, Hurst MJ, eds. *HTLV-1 and the Nervous System*. New York, NY: Alan R Liss Inc; 1989:495-501.
20. Engel WK, Haginoya K, Alvarez RB, Sabetian K, Bajoghli M, Askanas V. Sporadic inclusion-body myositis (s-IBM) in an HTLV-1-positive Iranian Muslim [abstract]. *Neurology*. 1997;48:124.
21. Markesbery WR. Oxidative stress hypothesis in Alzheimer's disease. *Free Radic Biol Med*. 1997;23:134-147.
22. Lippa CF, Saunders AM, Smith TW, et al. Familial and sporadic Alzheimer's disease: neuropathology cannot exclude a final common pathway. *Neurology*. 1996;46:406-412.
23. Prusiner SB, Hsiao KK. Human prion diseases. *Ann Neurol*. 1994;35:385-395.
24. Askanas V, Engel WK, Alvarez RB. Fourteen newly recognized proteins at the human neuromuscular junctions—and their non-junctional accumulation in inclusion-body myositis. In: Richman DP, ed. *Myasthenia Gravis and Related Diseases: Disorders of the Neuromuscular Junction*. Vol 841. New York, NY: Annals of New York Academy of Sciences; 1998;841:28-56.