

## Neonatal chlamydial conjunctivitis

K PERSSON, R RÖNNERSTAM, L SVANBERG, AND S POLBERGER

Departments of Clinical Virology, Ophthalmology, Obstetrics and Gynaecology, and Paediatrics, Malmö General Hospital, Sweden

**SUMMARY** Maternal chlamydial antibodies were determined in cord sera of 41 infants who developed neonatal chlamydial conjunctivitis and compared with the antibody profile of infants who had been exposed to *Chlamydia trachomatis* at birth by their isolation positive mothers but in whom conjunctivitis did not develop. No protective effect could be attributed to maternal antibodies transferred to the infants. Paired sera samples were collected from 18 infants with chlamydial conjunctivitis. Chlamydial IgM antibodies were detected in four of these 18 cases at the time diagnosis was established by isolation. An additional eight cases had developed chlamydial IgM at the time the convalescent sera samples were taken, on average on day 40. At that time symptoms had disappeared after systemic treatment had been given. Thus chlamydial IgM antibodies were eventually shown in two thirds of infants with chlamydial conjunctivitis who were all systemically treated and clinically healed. These data suggest a cautious assessment of chlamydial IgM in the diagnosis of chlamydial pneumonia.

Neonatal chlamydial infection may occur when the mother has a genital infection by *Chlamydia trachomatis*. The prevalence of genital chlamydial infection in pregnant and puerperal women ranges between 2 and 18% in different populations.<sup>1–7</sup> The most common clinical manifestation of neonatal chlamydial infection is conjunctivitis, which is observed in 20–35% of exposed infants. *C. trachomatis* can, however, be recovered from several locations besides the conjunctivae—that is, nasopharynx, gastrointestinal tract, and vagina.<sup>8</sup> Respiratory tract infection by *C. trachomatis* may lead to pneumonia with some distinct features and is usually observed at 4–12 weeks of age.<sup>9</sup> Chlamydial pneumonia has been detected in up to 18% of infants born of mothers positive for *C. trachomatis*.<sup>10</sup>

About two thirds of infants exposed to *C. trachomatis* at birth show serologic signs of chlamydial infection. High or extremely high IgM titres of chlamydial antibodies can be shown in cases of infant chlamydial pneumonia. In contrast, serum chlamydial IgM antibodies have only been shown in a low proportion of cases with neonatal chlamydial conjunctivitis.<sup>11</sup> Local chlamydial antibodies in tear fluid are usually absent when chlamydial conjunctivitis is diagnosed but can be shown after 5–10 weeks of age,<sup>12</sup> although symptoms may have subsided or completely disappeared by then. Pro-

duction of serum IgG antibody is generally not apparent until 10 weeks and may be obscured by passively transferred maternal antibodies.<sup>11</sup>

We have investigated the chlamydial antibody state at birth in infants exposed to maternal chlamydial infection and in the mothers.

### Materials and methods

**Patients.** The study group comprised 43 infants with neonatal chlamydial conjunctivitis confirmed by isolation of *C. trachomatis* from the conjunctivae. Samples of cord sera were available from 41 of these neonates as well as samples of delivery sera from their mothers. These 43 cases represent consecutive cases seen during a four year period, excluding two cases where neither samples of cord serum nor samples of acute phase or convalescent sera were available. During the later part of the period paired sera samples were regularly collected and obtained from 18 cases.

Another group comprised 16 infants whose mothers had genital chlamydial infection detected by postpartum isolation but where conjunctivitis did not develop in the child during the first 6 months of life. Samples of cord sera from the neonates and delivery sera from their mothers were available in all these cases.

The control group consisted of newborn infants

with clinically suspected neonatal septicaemia. This group comprised 29 neonates from whom chlamydial isolation was taken from the nasopharynx and the eyes. Paired sera samples were collected.

Delivery sera samples were obtained from 41 women matched for age with the mothers of the infants with chlamydial conjunctivitis.

**Chlamydial isolation and serology.** Cotton wool swabs were used for conjunctival and genital isolation of *C. trachomatis*. Nasopharyngeal specimens were aspirated with a syringe using an infant feeding tube. Irradiated McCoy cell cultures were inoculated in duplicate and stained after 72 hours with iodine.

Serology was performed by microimmunofluorescence<sup>13</sup> with the modification that a pool of yolk sac grown antigens, consisting of the serotypes D-K, was used.<sup>14</sup> All samples of sera were screened at a dilution of 1/16 and positive samples titrated to end point dilution. Titres are stated as the reciprocal of the highest dilution with antibody reactivity. All IgM positive samples were absorbed with aggregated IgG to remove any confounding rheumatoid factor<sup>15</sup> and then titrated.

## Results

**Antibody profile at birth.** Chlamydial antibodies in cord sera represent maternally transferred IgG. Such antibodies were detected in 40 out of 41 neonates in whom chlamydial conjunctivitis later developed, with a geometric mean titre of 128. One of these infants was born prematurely in the 35th week of gestation weighing 2250 g. This infant had chlamydial antibodies at a titre of 64. All the other children in this group were born at full term with weights within the normal range. Their mothers, who had a mean age of 24, had chlamydial IgG antibodies in all cases except one, in which case the infant also lacked detectable chlamydial antibodies. The geometric mean titre in the mothers was 170, not significantly different from that of their children.

For comparison 16 infants were available whose mothers had genital chlamydial infection detected after delivery. Thus they were exposed at birth but did not develop conjunctivitis during the first 6 months of life. Cord serum chlamydial IgG antibodies were detected in 13 of these 16 children, with a geometric mean titre of 67, which does not differ significantly from that of the 41 symptomatic infants. Again in all the 13 cases where the infant had detectable antibodies the mothers had chlamydial IgG antibodies. The mothers of the remaining three infants without chlamydial antibodies were antibody negative. The geometric mean antibody titre for all

16 mothers in this group was 56, which is not significantly different from that of their children but is possibly lower ( $p < 0.05$ ) than that of the mothers of symptomatic children. The mean age of the mothers with asymptomatic children was 23.

The prevalence of maternal chlamydial antibody for mothers of symptomatic infants was compared with the prevalence of antibodies post partum in the women matched for age without genital chlamydial infection. Serum chlamydial IgG antibodies in these control women were found in 10 of 41 (23%) compared with 40 of 41 (98%) in the 'symptomatic' group ( $p < 0.001$ ) and 13 of 16 (81%) in the 'asymptomatic' group ( $p < 0.001$ ).

**Antibody response in cases of chlamydial conjunctivitis.** In 18 cases of neonatal chlamydial conjunctivitis confirmed by isolation of *C. trachomatis* from the conjunctivae paired sera samples were obtained during the disease. The acute phase serum sample was collected at a mean age of 21 days, with a range of 11–34 days, when the diagnosis had been established by demonstration of *C. trachomatis*. The convalescent serum sample was obtained on average 19 days later at a mean age of 40 days (range 28–54 days). Cord sera samples were available in all these cases, and chlamydial IgG antibodies were observed in 17. Chlamydial IgM antibodies were never found in the cord sera samples. In one of the 18 cases a fourfold rise in chlamydial IgG titre was found, but in most cases maternal antibodies concealed any production of IgG antibody in the child. Chlamydial IgM antibodies were detected in four of 18 acute phase sera samples and in 12 of the 18 convalescent sera samples (Figure).

The development of chlamydial IgM antibodies was shown after the infants had been treated with

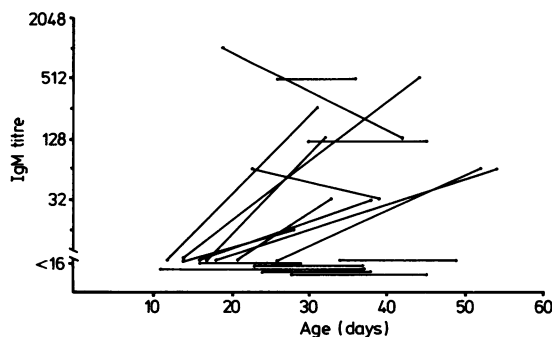


Figure Chlamydial IgM antibody response in 18 infants with chlamydial conjunctivitis confirmed by isolation of *C. trachomatis*.

systemic erythromycin (50 mg/kg/day) and when the condition was clinically healed.

As controls, 29 infants with suspected neonatal septicaemia had bacteriological and virological cultures and serological tests performed. As part of this protocol chlamydial cultures from conjunctival swabs and nasopharyngeal secretions were performed, which yielded uniformly negative results. Paired sera samples were available in all 29 cases. The first serum sample was collected at a mean age of 4 days (range 1–22 days) and the second at 30 days (range 17–47 days). No change in chlamydial IgG antibodies was detected. IgM antibodies to *C. trachomatis* could not be shown in any case. When antibiotics were used in this group gentamycin and penicillin were chosen. Conjunctivitis was not seen in any of these infants.

### Discussion

Chlamydial IgG antibodies were detected in 40 of 41 samples of cord sera taken from infants with neonatal chlamydial conjunctivitis, and neither the prevalence of antibodies nor the geometric mean titre differed from the infants without conjunctivitis whose mothers had proven genital chlamydial infection 3–4 days after delivery. Therefore, transferred maternal serum antibodies did not seem to confer any detectable protection against chlamydial infection of the conjunctivae. The mean age of the mothers of the 41 infants with chlamydial conjunctivitis was 24 compared with 23 for the mothers infected with chlamydia with asymptomatic infants. Thus there was no indication that any resistance factor related to age of the mothers might have determined the subsequent clinical eye manifestations in the children with chlamydial conjunctivitis.

Experimental chlamydial eye infections in volunteers have shown partial immunity to the homologous chlamydial strain.<sup>16 17</sup> Systemic immunity seemed to be more important than local immunity in those experiments. Antibodies to a genus antigen determined by complement fixation present before the challenge did not prevent infection. This antibody reactivity reflected previous exposure to any of the 15 serovars of *C. trachomatis* or even to the ornithosis agent, *Chlamydia psittaci*. Our results are not directly comparable as the infants in our study had maternally transferred antibodies, which should be expected to be homologous to the infecting strain.

In several different studies the attack rate of clinical chlamydial conjunctivitis has been estimated to be 20–35% of exposed infants in populations where the prevalence of natural chlamydial infections has varied between 2–18%. Even in Nairobi,

Kenya, with the impressive prevalence of 28.5% of maternal *C. trachomatis* infections, the attack rate of chlamydial conjunctivitis in the infants was of the same magnitude. (M Laga, *et al.* Paripartum infection with *Neisseria gonorrhoeae* and *Chlamydia trachomatis*, low birth weight, and ophthalmia neonatorum in Nairobi, Kenya. Presented at 6th International Meeting of the International Society for STD Research, August 1985, Brighton, United Kingdom.) The high and low prevalence populations must be expected to differ in several respects—for example, age, the proportion of primary and secondary chlamydial infection, and antibody profile, to mention a few. A uniform attack rate under these varying circumstances therefore decreases the odds of finding a single factor of major importance for the outcome of chlamydial exposure at birth.

Neonatal chlamydial conjunctivitis is usually apparent during the first and second week of life and diagnosed somewhat later. The antibody response to *C. trachomatis* during the disease showed a fourfold rise of IgG antibodies in only one case, but serum IgM antibodies were shown in four of the acute phase sera samples and in 12 of the convalescent sera samples. Thus a significant increase in the prevalence of IgM chlamydial antibodies was observed during the course of chlamydial conjunctivitis despite the fact that clinical manifestations disappeared as the infants were treated with systemic erythromycin. IgM antibodies to *C. trachomatis* were not detected in the control infants with suspected septicaemia. In this group sera samples were obtained at 4 and 30 days of life, and the results are therefore not directly comparable with those in the study group where samples were collected on average on day 21 and 40. The most unfavourable comparison between acute phase sera samples in the study group and convalescent sera samples in the control group still discloses a difference in the prevalence of IgM antibodies at the  $p=0.02$  level. The real difference is probably even greater as the convalescent sera samples in the control group were collected on average at a time half way between the first and second sera samples in the conjunctivitis group when the frequency of IgM antibodies could be expected to be higher than 4/18.

Thus most of the infants with chlamydial conjunctivitis eventually developed serum IgM antibodies detected at a time when the disease had healed. The same general pattern of antibody development has been described with tear antibodies where almost every infant with chlamydia conjunctivitis had detectable tear antibodies after 8–10 weeks, although they had been antibody negative earlier in

the course.<sup>12</sup> These results indicate that systemic and local antibodies develop gradually in infants with chlamydial conjunctivitis after the antigenic stimulus has been eliminated by treatment.

High concentrations of IgM antibodies to *C. trachomatis* are generally found in cases of chlamydial pneumonia.<sup>11</sup> The results presented in this paper indicate that chlamydial IgM antibodies at 6–12 weeks of age when chlamydial pneumonia is seen may be the result of chlamydial conjunctivitis alone. Thus chlamydial IgM seems to indicate neonatal chlamydial infection rather than chlamydial pneumonia, although antibodies may develop late. A respiratory tract infection concomitant with or after chlamydial conjunctivitis may be due to another pathogen like respiratory syncytial virus or *Bordetella pertussis*, even when chlamydial IgM antibodies are present.

#### References

- <sup>1</sup> Chandler JW, Alexander ER, Pheiffer TA, Wang S-P, Holmes KK, English M. Ophthalmia neonatorum associated with maternal chlamydial infections. *Trans Am Acad Ophthalmol Otolaryngol* 1977;**83**:302–8.
  - <sup>2</sup> Frommell GT, Rothenberg R, Wang S-P, McIntoch K. Chlamydial infection of mothers and their infants. *J Pediatr* 1979;**95**:28–32.
  - <sup>3</sup> Hammerschlag MR, Anderka M, Semine DZ, McComb D, McCormack WM. Prospective study of maternal and infantile infection with *Chlamydia trachomatis*. *Pediatrics* 1979;**64**:142–8.
  - <sup>4</sup> Schachter J, Holt J, Goodner E, Grossman M, Sweet R, Mills J. Prospective study of chlamydial infection in neonates. *Lancet* 1979;ii:377–80.
  - <sup>5</sup> Mårdh P-A, Helin I, Bobeck S, Laurin J, Nilsson T. Colonisation of pregnant and puerperal women and neonates with *Chlamydia trachomatis*. *Br J Vener Dis* 1980;**56**:96–100.
  - <sup>6</sup> Heggie AD, Lumicao GG, Stuart LA, Gyves MT. *Chlamydia trachomatis* infection in mothers and infants. *Am J Dis Child* 1981;**135**:507–11.
  - <sup>7</sup> Persson K, Rönnerstam R, Svanberg L, Holmberg L. Maternal and infantile infection with chlamydia in a Swedish population. *Acta Paediatr Scand* 1981;**70**:101–5.
  - <sup>8</sup> Schachter J, Grossman M, Holt J, Sweet R, Specter S. Infection with *Chlamydia trachomatis*: involvement of multiple anatomic sites in neonates. *J Infect Dis* 1979;**139**:232–4.
  - <sup>9</sup> Beem BO, Saxon EM. Respiratory tract colonization and a distinctive pneumonia syndrome in infants infected with *Chlamydia trachomatis*. *N Engl J Med* 1977;**296**:306–10.
  - <sup>10</sup> Grossman M, Schachter J, Sweet R, Bishop W, Jordan C. Prospective studies in chlamydia in newborns. In: Mårdh P-A, Holmes KK, Oriel JD, Piot P, Schachter J, eds. *Chlamydial infections*. Netherlands: Elsevier Biomedical Press, 1982:213–6.
  - <sup>11</sup> Schachter J, Grossman M, Azimi PH. Serology of *Chlamydia trachomatis* in infants. *J Infect Dis* 1982;**146**:530–5.
  - <sup>12</sup> Wang S-P, Grayston JT. Micro immunofluorescence antibody response in *Chlamydia trachomatis* infection, a review. In: Mårdh P-A, Holmes KK, Oriel JD, Piot P, Schachter J, eds. *Chlamydial infections*. Netherlands: Elsevier Biomedical Press, 1982:301–16.
- genital TRIC, lymphogranuloma venereum, and related organisms in a new microtiter indirect immunofluorescence test. *Am J Ophthalmol* 1970;**70**:367–74.
- <sup>14</sup> Treharne JD, Darougar S, Jones BR. Modification of the microimmunofluorescence test to provide a routine serodiagnostic test for chlamydial infection. *J Clin Pathol* 1977;**30**:510–7.
  - <sup>15</sup> Knez V, Stewart JA, Ziegler DW. Cytomegalovirus specific IgM and IgG response in humans studied by radioimmunoassay. *J Immunol* 1976;**117**:2006–13.
  - <sup>16</sup> Dawson C, Jawetz E, Hanna L, Rose L, Wood TR, Thygeson P. Experimental inclusion conjunctivitis in man. *Am J Epidemiol* 1966;**84**:411–25.
  - <sup>17</sup> Jawetz E, Rose L, Hanna L, Thygeson P. Experimental inclusion conjunctivitis in man. *JAMA* 1965;**154**:150–62.

Correspondence to Dr K Persson, Department of Clinical Virology, Malmö General Hospital, S-21401 Malmö, Sweden.

Received 7 February 1986