

# Introduction to Abdominal Ultrasound



Debra M. Beard, DVM, MS, DACVR  
Clinical Associate Professor, Radiology  
Auburn University College of Veterinary Medicine

## Why use Ultrasound in your practice?

US is a non-invasive method imaging of internal structures including abdomen, thorax (heart), eye, and appendages. The sound beam of diagnostic US frequencies has not been known as a biohazard, even in the sensitive tissues of the developing fetus. US can be used to guide biopsies and centesis needles for retrieval of small volume samples or close to vital structures, such as mediastinal masses. US can be used in non-anesthetized and non-sedated animals, reducing the need for anesthesia in high-risk patients (geriatric, pediatric, organ compromised). Many pet owners want the most advanced diagnostics available for their pet, while other owners want to avoid perceived risk of surgery.

## What ultrasound isn't...

US isn't a crystal ball or a clinical pathologist. US isn't interpreted the same as a shadow on an X-ray film (bone absorbs US and can't be examined except for the surface!). Also, US isn't a foolproof way of diagnosing obscure diseases (or common ones for that matter!).

## What ultrasound can do.....

- determine internal structure/texture of an organ or mass (**ECHOTEXTURE**) and its relative "grayness" (**ECHOGENICITY**)
- characterizing fluids within an organ or body cavity (**CELLULAR vs. ACELLULAR**)
- locating non-radiopaque calculi within organs
- pregnancy diagnosis
- biopsy and centesis guidance

## How does Ultrasound (US) work?

A piezoelectric crystal in the US transducer (or "probe") sends out sound waves at particular frequencies into the body tissues. These sound waves are ***reflected, transmitted, or absorbed*** by the various structures they encounter in the body. The differences between how much soundbeam a tissue reflects or transmits give the tissue its acoustic characteristics. We see this translated into shades of gray on a TV or computer monitor; the highly reflective portions of a tissue show up as very white, while the non-reflective structures transmit the soundbeam and show up as black.

## Ultrasound timeline

- 1890's: Piezoelectric effect discovered by Paul-Jacques and Pierre Curie
- WWI: detection of ships and mines in harbors
- 1946: "A"- mode developed
- 1948: first time used medically in monitoring fetal development
- 1951: Dr.'s Hertz and Edler identified heart valves and chambers
- 1962: "B"-mode US developed
- 1964: Dr. Joseph Holmes brings US to USA
- 1972: Real-time US developed

## Abdominal Ultrasound


**Patient preparation.** In US, patient preparation is paramount. Since air reflects the US beam, as much care as possible must be removed from the beam path – CLIP

THE HAIR! This may require that you explain to the owner that the preservation of the haircoat will prevent a thorough US examination. If this limitation is acceptable to the owner, at least they have been warned.

### Patient preparation:

Clip the hair...  
Clip the hair...

**CLIP THE !#\$% HAIR!!!**



**Frustrated sonographer**

If the skin is dirty, muddy, or scruffy from dermatitis, it is best to remove as much of this debris as possible. Cats (and some dogs) often have very fine guard hairs at the skin surface; a quick rubdown or spritz of this remaining hair with alcohol will help remove the trapped air. Then apply an acoustic coupling gel (US "lube") to the skin to maximize the soundbeam transmission. Yes, you may use alcohol alone, but this may degrade the rubber face of the transducer over time (check with your ultrasound machine manufacturer).

**Positioning for exams.** For the majority of abdominal examinations, patients should be lying comfortably on their sides. Reasoning: Our patients are laterally flattened (as opposed to humans that are dorsoventrally flattened), so the **lateral recumbency** takes advantage of the tendency of the abdomen flatten even further, allowing less distance to the "far reaches" of the area to be examined. Some veterinary sonographers prefer their patients in a V-trough in dorsal recumbency. This makes the kidneys (particularly the right kidney), adrenal glands, and some other organs difficult to find or examine thoroughly.

Scanning a standing patient is useful if the patient is very large, if massive abdominal fluid is present, and for examination of the stomach.

**Systematic US examination.** It is very important to follow a pattern of examination of organs in the abdomen. Since the US beam only “sees” a very small portion of the area at any given time, it is easy to miss an area or miss examining an entire organ unless you establish a routine that allows you to examine all organs and areas. As you perform the exam, your **mental “checklist”** will help guide the examination. My routine abdominal exam begins with the structures on the left side (patient in right lateral recumbency) and proceeds as follows:

- Spleen (head, body, tail)
- stomach
- liver, left side to middle
- left kidney
- left adrenal gland
- aorta and sub-lumbar lymph nodes
- urinary bladder and prostate
- Descending colon and small bowel

The patient is then rotated to left lateral recumbency and the exam proceeds on the right side:

- right kidney
- right adrenal
- duodenum
- pancreas, right limb and body
- liver, right
- gall bladder
- portal vein
- caudal vena cava and lymph nodes

Individual intestinal loops can be selected and followed to get an overview of the appearance of the bowel, but a focal bowel lesion can be easily missed. Moving the probe slowly over the abdomen on both left and right sides in a “grid”- type of pattern will help to “screen” for focal lesions within the bowel.

The dorsally recumbent position (patient in a V-trough) is useful in guided cystocentesis and examination of the liver vasculature.

Other observations to make as the exam progresses include:	
Free abdominal fluid present?	Cellular vs. acellular? Guided centesis for small volumes
Abdominal vasculature	Compare aorta and CVC size Saddle thrombus (aortic) in cats

	Venous thrombi
Intra-abdominal lymph nodes	Enlarged (visible)? Homogenous or inhomogeneous?
Intra-abdominal masses	From which organ does the mass originate? Vascular?
Stomach and intestinal motility	4-6 contractions/minute

The abdominal ultrasound report form included at the end of your notes is a working checklist that will help you work through a complete abdominal ultrasound exam in a systematic manner.

**Mass localization:**

When attempting to localize a mass to a particular organ, it is very important to view the mass from as many planes as possible, but always from at least two orthogonal planes (sagittal and transverse).

Other important attributes of an unidentified mass to note include:

- motility (or lack thereof)
- vascularity
- homogeneous/heterogeneous
- cyst-like (simple vs. complex)
- well-defined vs. ill-defined
- smooth vs. irregular margins

**Ultrasound scanning controls**

**Image orientation**

- Sagittal and dorsal scan planes -- cranial aspect of the patient or organ is on the left of the video display
- Transverse scan planes -- right aspect of the patient or organ is on the left of the video display

**Transducers or “probe” selection**

The transducers are designated by numbers in MHz, which refer to the frequency of the characteristic soundbeam emitted by that transducer. Remember, a ceramic crystal produces the soundbeam, therefore the transducer is a delicate instrument that can be damaged by rough or careless handling. ***This is the costliest part of the machine -- do not drop or submerge in water.***

The rule of thumb regarding transducer selection is as follows: the higher the number (in MHz), the better the resolution, but the less depth of penetration into body tissues.

\_\_ Transducer MHz \_\_ \_\_ Resolution \_\_ \_\_ Penetration

## Transducer MHz           Resolution           Penetration

Therefore, always use the highest MHz transducer available, and then switch to the next highest MHz transducer only when needed for additional penetration to deeper body structures.

### Transducer selection guidelines

- 7.0 MHz or higher: cat abdomens, small dog abdomens, ocular, tendons
- 5.0 MHz: medium to large dog abdomens, most hearts (especially if Doppler capabilities are needed)
- 2.0-3.0 MHz: large animal abdomens, hearts of

### **Depth of field adjustment**

Depth of field can be adjusted to visualize a specific area of interest within an organ or to visualize the entire organ. A depth of field that is too shallow will cut off part of the field, while a depth of field that is too deep will show a great deal of black space deep to the organ or area of interest.

### **Focal points**

The focal points are indicated on the edge of the image by one or more small arrowheads. The focal point should be set at the level of the specific area of interest that you are viewing to optimize the resolution of the image at that depth. The disadvantage of multiple focal points is that the frame rate become slower in the image may appear to "swim" or look "jerky".

### **Power and gain settings**

Some ultrasound equipment allows the operator to adjust the power "output" of the ultrasound. Power is the intensity of the ultrasound entering the patient, and should be kept to the necessary minimal level to reduce image distortion.

Gain is the amount of amplification applied to returning ultrasound echoes. Gain is often divided into near-field and far-field gain settings, and an overall gain setting. As a rule of thumb, first reduce the near-field gain and preserve or boost the far-field gain to obtain a balanced image, and then use the overall gain setting to increase or decrease the brightness of the image.

Together, power and gain settings are used to obtain a visually pleasing gray-scale image that is uniform in both the near and far fields.



Now we are ready to scan!

## Renal sonography

Ultrasound imaging of the kidneys does not depend on renal function (unlike contrast radiographic studies). Serial measurements can be used for assessment of progression or resolution of renal disease. Ultrasound guided FNA or core biopsies are now favored over more invasive, less selective biopsy methods.

### Scanning position

Imaging of the kidneys from the lateral aspect is less affected by bowel gas. Imaging of the dog's right kidney can present a challenge due to the more cranial position of the kidney within the rib cage. Evaluation through the right 11 – 12 intercostal space may be necessary.

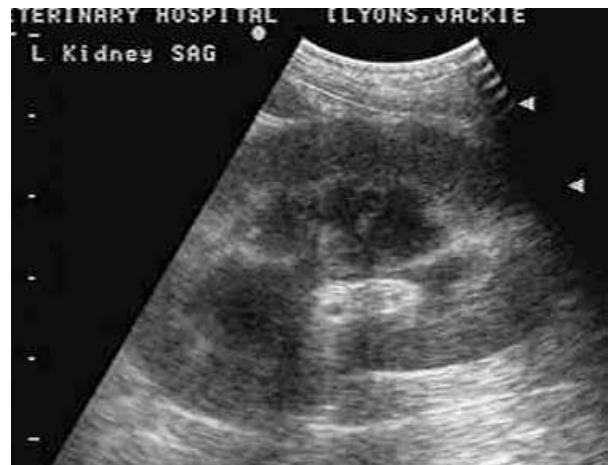### Normal appearance

Scan planes:

- Dorsal “anatomy – lab kidney”
- Sagittal “watermelon”, “parallel bars”
- Transverse “C – sign”

Normal anatomy:

- Cortex (echogenic)
- Medulla (less echogenic)
- Corticomedullary junction (well visualized)
- Renal sinus with fat (hyperechoic)
- Renal hilus
- Renal artery and vein (anechoic)
- Ureter (anechoic) – generally is not seen unless dilated (pyelectasia or hydroureter)



### Indications

When should US be recommended for your patients?

- lack of visualization of kidneys on abdominal radiographs
- abnormal size or shape
- uremia
- hematuria
- flank or back pain
- Ultrasound-guided biopsy
- Part of routine abdominal US exam

### Interpretation

US size determinations (pole-to-pole measurements are more accurate than radiographs because of lack of magnification. Normal kidney size in cats = 3.8-4.4 cm in length; transverse measurements have not correlated well with disease states (or lack thereof). Reliable published “normals” for kidney sizes in dogs have not been established

(due to the extreme variability of body size and style), therefore renal size in dogs should still be measured on a V/D radiograph compared to the L2 vertebral body length (2.5-3.5x L2).

Renal sizes on ultrasound		
Dogs	Cats	Ferrets
Not established; Use V/D radiograph; should be 2.5-3.5 x L2 body length	3.8-4.4cm length	

### ***Diffuse renal abnormalities***

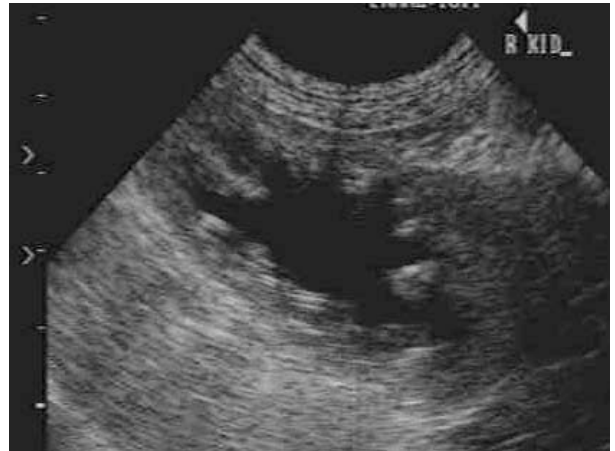- Increased cortical echogenicity with enhanced corticomedullary definition
  - glomerular and interstitial nephritis
  - acute tubular necrosis or nephrosis (toxins)
  - end-stage renal disease
  - parenchymal calcification
  - renal lymphoma, FIP (cats)
  - metastatic squamous cell carcinoma
- Decreased cortical echogenicity with decreased corticomedullary definition
  - lymphosarcoma (dog and cat) – can also appear as one or more hypoechoic masses

### ***Focal abnormalities***

- Calculi/mineralization
- Masses
  - uniform or complex echotexture
  - hemorrhage, hematomas
  - granulomas
  - abscesses
  - infarcts
  - primary or metastatic neoplasia
- cysts
  - solitary or multiple
  - inherited or acquired
    - polycystic kidney disease (congenital i.e. Persian and Persian-X cats) or acquired
    - trauma

### **Collecting system abnormalities:**

- Hydronephrosis/hydroureter
- Dilatation of renal pelvis (pyelectasia)
- Pyelonephritis
  - Obstruction of urine flow
  - Diuresis
  - Calculi and mineralization



## Urinary Bladder

Normal urinary bladder has smooth walls that have 3 distinct layers:

- outer serosal layer (hyperechoic - white)
- middle muscular layer (hypoechoic - dark)
- inner mucosal layer (hyperechoic - white)

The urine within the urinary bladder should be anechoic (no echoes).

- inflammatory - cystitis - +/- wall thickening
  - normal 1-2mm
  - cranioventrally, becomes generalized
  - polypoid cystitis - multiple, small masses projecting into lumen
  - benign polyps (rare) - get a biopsy
- blood clots -
  - secondary trauma, bleeding disorders, infection, or neoplasia
  - hyperechoic, non-shadowing echogenicities with irregular shape
  - may gravitate to dependent part of bladder or adhere to wall
  - iatrogenic - traumatic cystocentesis
- Cystic calculi
  - hyperechoic focal echogenicities in the dependent part of bladder
  - shadowing varies with composition and compactness
  - ultrasound more sensitive to lower mineral content and may detect calculi that are not visible on radiograph
- Neoplasia
  - most common neoplasm is transitional cell carcinoma
  - focal wall thickening with an irregular, sessile mass extending into lumen
  - epithelial
  - SCC, adenocarcinoma
  - Mesenchymal
  - Muscle, fibrous, vascular



## Adrenal glands

### Scanning position

The left adrenal (LA) gland is generally the easiest to locate. Locate the aorta in the longitudinal plane; examine the aorta with small dorsal to ventral movements while sliding the transducer cranially to the area of the left kidney. The left renal artery (LRA) will be seen as an anechoic tube exiting the aorta and forming a “shepherd’s crook” or “hook” type of appearance. The left adrenal gland resides in the “crook” formed by the aorta and the LRA. Small rotational movements will maximize the pole-to-pole visualization of the gland.

The right adrenal (RA) gland is notoriously more difficult to find than the LA because of the proximity of the gas-filled duodenum and pylorus. In the flank region, locate the caudal vena cava (CVC) in the longitudinal plane and slide cranially (as when using the aorta to find the LA) until the right renal hilus is located. The renal vessels can be seen as anechoic tubular or round structures adjacent to the right kidney. Move the transducer dorsal to ventral in a back and forth movement; the RA is located slightly cranial to the right renal vein.

**The kidneys should not be used to localize the adrenal glands -- they are mobile and may change their positional relationship when pressure of the ultrasound probe is placed on them. Use your "vascular roadmap".**

### Normal appearance

The left adrenal is a “dumbbell” or “peanut”-shaped hypoechoic structure that may be slightly more echogenic than the surrounding vessels. The right adrenal gland is a “bent arrow” or “comma” shaped, therefore usually cannot be seen in its entirety in one plane. The medulla is often more echogenic than the cortex.

The left adrenal gland is often larger than the right. The size and shape of the adrenals may vary with body weight or breed. In cats, the adrenal glands may be more oval or cylindrical bannings in dogs. An abnormal shape is often a better indication of disease than are size measurements. A rounded or “plump” or mass-like gland should always be suspect for disease. The size of normal adrenal glands is listed below:

species	LA	RA
dogs	$\leq 7.4$ mm maximumW	Same as left
cats	4.3 $\pm$ 0.3 mm	Same as left
ferrets	6-8mm L x 2-3.5mmW	8-11mmL x 2.5-3mmW

### Indications for adrenal sonography

- Alopecia in ferrets
- mass in the adrenal area
- mineralization of adrenal glands on radiographs
- suspect Cushing’s syndrome
- differentiate between pituitary dependent hyperadrenocorticism (80%) and adrenocortical tumors

- suspect Addison's disease
- part of routine abdominal US exam

**Interpretation of Adrenal gland enlargement**

*Pituitary-dependent hyperadrenocorticism*

- Bilateral symmetrical adrenal gland enlargement is most common with PDH but may also be seen as unilateral or bilateral unequal enlargement.
- 23% of dogs with PDH did not have adrenal gland enlargement based on the upper limit of 7.4 mm (low sensitivity).
- More common in poodles, dachshunds, beagles, boxers, Boston Terriers, and German shepherd dogs.
- Diabetes mellitus is a concurrent finding in approximately 80% of cats with hyperadrenocorticism.
- Nodules and masses are uncommon with PDH.

*Adrenal neoplasia*

- Carcinoma, pheochromocytoma, and metastatic neoplasia
- Reported more frequently in females and larger breeds
- Nodules and masses are more frequent with loss of normal shape; considered more likely if the adrenal size exceeds 2 cm
- All adrenal tumors are locally invasive and potentially metastatic.
- Can be bilateral
- Opposite gland may or may not be suppressed
- Adrenal neoplasia may be functional or nonfunctional

*Hypoadrenocorticism* - thinner, may be more echogenic? Most often the glands are seen as sonographically normal.

*Adrenal mineralization* -highly suggestive of adrenocortical neoplasia in dogs; incidental finding in cats.

<b>Differentials for adrenal gland enlargement</b>	
<b>Unilateral vs. bilateral</b>	<b>Condition suggested</b>
Bilateral, mild to moderate	PDH
Unilateral, moderate	PDH, primary adrenal neoplasia, metastatic neoplasia

## Liver sonography

### Scanning position

Liver scanning is accomplished by positioning the transducer directly under the sternum at the xyphoid angled slightly cranially, attempting to avoid the air in the stomach. Intercostal views can also be used. Gas in the stomach may require repositioning the patient (standing) in order to visualize the entire liver. Introducing fluid per os into the stomach often helps with visualization by producing an acoustic “window” to the liver. Sagittal and transverse scans of the liver should be made by sweeping the soundbeam back and forth from side-to-side and cranial to caudal in an attempt to visualize the entire liver.

### Normal appearance

The normal appearance of hepatic parenchyma is uniform with medium level echoes. Hepatic and portal veins interrupt the uniform pattern, and focal lesions are easily detected. Although the liver is well suited for sonographic evaluation because of its large size, judging whether a liver is small or larger than normal is difficult with US.

Liver **size** is best assessed on abdominal radiographs

- Liver has coarser texture than the spleen
- Liver is isoechoic or slightly hyperechoic to right kidney
- Hepatic veins = anechoic tubular structures (black “streaks”) in the parenchyma
- Portal veins = anechoic tubular structures with white borders

### Indications for hepatic sonography

- Ascites
- hepatomegaly
- cranial abdominal mass
- metastasis check
- icterus
- fever of unknown origin
- ultrasound-guided biopsy
- Evaluation of treatment response

### Interpretation

Sonographic signs of liver disease can be divided into focal (including multifocal) and diffuse categories depending on the distribution of abnormalities with regards to echotexture and echogenicity. Other parameters to evaluate include margination and vasculature.

#### Echotexture

- Coarse vs. homogenous

#### Margination

- Smooth vs. lumpy or irregular

#### Vasculature

- Portal veins (numbers, visibility)
- Hepatic veins (size)

### Echogenicity

- Compared with other organs (assuming other organs are normal)

### ***Focal/multifocal liver disease:***

US is excellent for detection of focal liver abnormalities because of the uniform background parenchyma. An irregularity of the margins or parenchyma is easily observed. Peripheral masses may deform the capsule.

Differentials for focal/multifocal liver disease includes:

- Cysts
- hematomas
- abscesses
- hepatic necrosis
- nodular hyperplasia
- neoplasia

### Cysts and cyst-like structures

Hepatic cysts, like other cystic lesions, are characterized by the thin, well-defined walls, absence of internal echoes, sharp distal borders, and strong distal acoustic enhancement.

Hepatic cysts are often incidental, however polycystic disease should be ruled out with multiple cysts. In both canine and feline polycystic disease, cysts may also be present in the kidneys. The cysts may become secondarily infected as well.

Cysts with irregular walls, septations, or internal debris may indicate toxic, inflammatory, or neoplastic disease. Ultrasound guided fine needle aspiration of the cyst and subsequent cytologic evaluation and bacterial culture are indicated.

### Hematomas

The internal appearance of a hematoma varies with its age.

- Acute = echogenic
- Subacute = anechoic to hypoechoic then echogenic when clot formation occurs. Mixed echogenicity in irregular borders may appear during clot retraction, lysis, and seroma formation.
- Chronic (weeks-months) = anechoic

### Nodular hyperplasia

Very common, occurs in up to 70% of older dogs. Nodular hyperplasia has not been described in cats. May appear as hypoechoic nodules, but can also be isoechoic to hyperechoic as well as mixed echogenicity. It is very difficult to differentiate nodular hyperplasia from other focal lesions based on sonographic appearance; the bottom line is that cytology/histology is necessary.

### Neoplasia

Focal or diffuse pattern is seen with both primary and metastatic neoplasia. Neoplasia should be high on the list of differentials in an older animal with liver lesions. Diagnosis must be confirmed with aspiration or core biopsy.

Metastatic neoplasia is more common than primary neoplasia in the liver.

Common metastatic tumors include:

- Carcinomas originating from the GI tract, pancreas, and mammary glands
- Sarcomas of the spleen
- Lymphosarcoma

Common primary liver tumors include:

- Hepatocellular adenoma and carcinoma
- Cholangiocellular adenoma and carcinoma
- Mesenchymal origin neoplasia including bile duct carcinoma, hemangiosarcoma

A solitary focal liver lesion in an otherwise healthy animal may be a benign lesion however neoplasia cannot be ruled out. This should signal the need for a complete abdominal ultrasound to look for additional signs of disease. If none are found, the lesion should be measured for baseline size, and serial monitoring for changes should be scheduled.

### Abscess

While uncommon, hepatic abscesses may be associated with infection of other organs or organ systems. Diabetes mellitus may be a predisposing condition, as well as biliary disease, pancreatitis, neoplasia, and long-term steroid use.

The appearance on ultrasound a liver abscess is extremely variable depending on the age of the abscess and the appearance of the centralized necrosis. Gas may be present. Diagnosis depends heavily on correlation with the history, hematologic parameters, and aspiration for bacterial culture.

### Hepatic necrosis

This is uncommon, and the pattern may be multifocal or diffuse. Causes of this can include chemical, viral, toxic, or immune-mediated insults.

### ***Diffuse liver disease***

This is one of the most difficult to assess and must be correlated with clinical findings such as liver enzyme alterations, bile acids, and coagulation factors. Biopsy is almost always necessary for definitive diagnosis. Comparing the liver echogenicity with that of the kidneys and spleen at a similar depth and instrument gain settings can help establish a deviation from normal in echogenicity. Also comparing liver echogenicity to the portal vein walls is useful as well.

### Decreased echogenicity

The portal veins may appear more prominent than usual.

- lymphoma, leukemia
- amyloidosis
- acute hepatitis (+/-)
- passive congestion  $2^0$  to right heart failure

### Increased echogenicity

The portal veins may appear less prominent than usual.

- Fatty infiltration (can be  $2^0$  to diabetes mellitus in dogs and hepatic lipidosis in cats)
- Steroid hepatopathy
- Chronic hepatitis
- cirrhosis
- Lymphosarcoma (less common)
- Nodular hyperplasia

### Mixed echogenicity

This appearance can be seen with diffuse neoplastic disease causing a coarse echotexture. This may involve portions of the liver or the entire organ.

## Splenic sonography

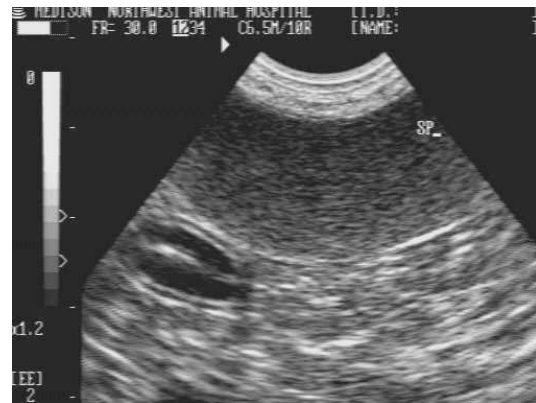
### Scanning position

The spleen is best seen with the patient in right lateral recumbency, and starting at the splenic head in the left cranial abdomen, examined systematically in the sagittal and transverse planes to the tail of the spleen. The position of the tail of the spleen is variable and may extend along the left body wall, or across the midline ventrally. It is important to aim the transducer cranially under the border of the rib cage to visualize the entire splenic head.

### Normal appearance

The normal appearance of the spleen is a homogeneous, fine echotexture with medium- to high-level echoes (less coarse and more echogenic than the liver). It has a smooth echogenic capsule. Splenic veins appear as anechoic tubular structures converging into several large veins at the hilus to form the splenic vein deep to the splenic parenchyma. Arteries are generally not visible except with color-Doppler. It is common to see hyperechoic non-shadowing areas adjacent to superficial splenic vessels; this represents splenic capsular invagination and fat surrounding vessels at the splenic hilus and is considered normal.

**US assessment  
of  
splenic size  
is subjective and  
is better  
assessed on  
radiographs**



### Indications for splenic sonography:

Palpable or radiographic splenomegaly is the most common indication for splenic ultrasound.

### Interpretation:

Disruptions in splenic parenchyma can be classified as diffuse or focal/multifocal.

#### *Diffuse splenic disease*

#### *Diffuse splenomegaly*

There are many differentials for disappearance and in those cases ultrasonography is not particularly helpful in establishing a specific diagnosis.

- Barbiturates, tranquilizers, AIHA, lymphoma, mast cell tumor, rickettsial diseases, septicemia, passive congestion
- passive congestion
- portal or systemic circulation disturbances
- anesthetic agents, tranquilizers

Diffuse splenomegaly with decreased echogenicity

- Lymphoma
- Plasmacytic neoplasia
- Acute congestion
- Complete or partial torsion
- Acute splenitis
- Extramedullary hematopoiesis
- Amyloidosis

Diffuse splenomegaly with increased echogenicity

- Chronic congestion
- Chronic inflammatory processes
- Chronic myeloproliferative disorders

Torsion

- Marked enlargement
- Hypoechoic to diffuse anechoic areas (“lacy” appearance)
- Less difficult to diagnose with Doppler
- May see echogenicities within the lumen of larger veins (thrombi)

Inflammation (splenitis)

- Acute
- Chronic (vasculitis, peritonitis, bacterial or fungal infection)

Neoplasia

- May appear as “coarse” echotexture
- can appear also as focal lesions
- hemangiosarcoma, lymphoma, mast cell tumor, leiomyosarcoma, osteosarcoma, fibrosarcoma

**Focal or multifocal disease**

Like the liver, focal lesions of the spleen are easily detected but not easily differentiated by their ultrasound appearance. History and lab work should be used to narrow down a tentative differential list. Ultrasound-guided fine needle aspirates are needed in most cases for definitive diagnosis.

Hematoma

The appearance is variable depending on the age of the hematoma. Maybe subcapsular or intraparenchymal.

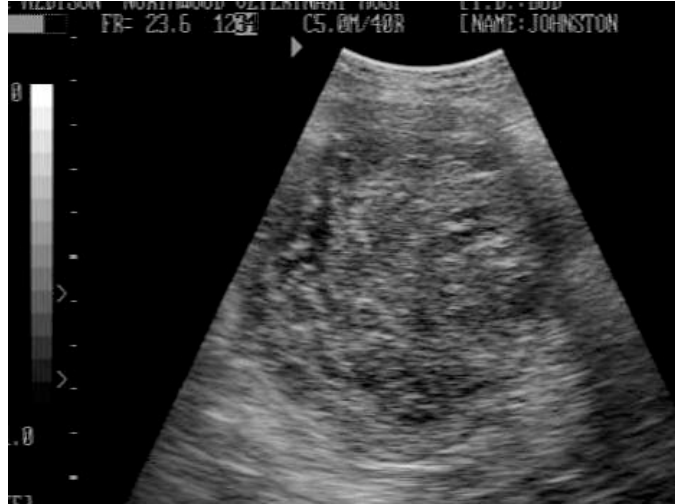Infarcts

Abscess

Nodular hyperplasia

Neoplasia

- Sarcomas are the most common (hemangiosarcoma, lymphosarcoma), but any cell type found in spleen can cause primary neoplasia
- Other muscle layer tumors include leiomyosarcoma, fibrosarcoma, liposarcoma, osteosarcoma, chondrosarcoma, rhabdomyosarcoma, and myxosarcoma
- Carcinomas are most common metastatic tumor
- Mast cell tumor is also commonly seen.



Echogenic splenic lesions

**Splenic thrombus**

**Splenic lymphadenopathy**

## **Pancreatic sonography**

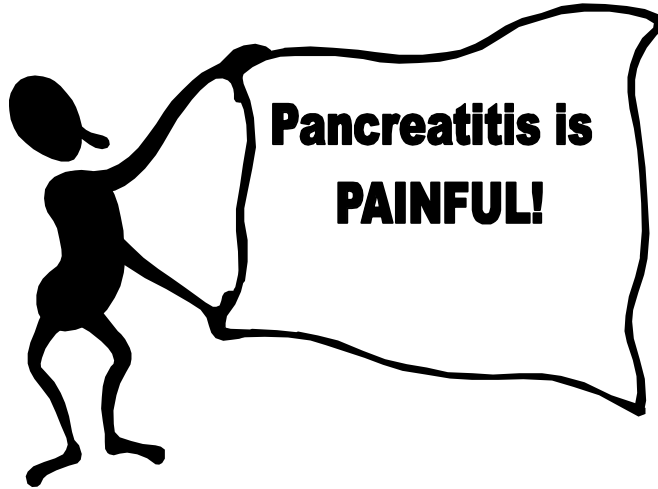A normal pancreas may not be sonographically detectable in some animals. If normal, it is a small ribbon of tissue with an echogenicity similar to the adjacent mesentery, and in proximity to gas-filled bowel, all of which can make the pancreas difficult to see.

The right limb of the pancreas is dorsomedial to the descending duodenum. To find the right limb of the pancreas:

- scan along the right cranial abdomen in the region of the right kidney
- once the right kidney is located, release pressure on the body with the probe
- duodenum should slide in ventral to the kidney
- small medial or back and forth movement with the probe will allow visualization of the pancreas
- the pancreas can then be followed to the caudal duodenal flexure about mid-abdomen) and then cranial to the body of the pancreas which lies in the cranial flexure
- filling the stomach with water may help provide an acoustic window.



REMEMBER:



This is diagnostically significant. You can exacerbate pancreatitis by exerting pressure with transducer!!! Used gently, US is an excellent way to diagnose and monitor response to treatment.

The left limb of the pancreas is often difficult to see if the stomach is distended with food or gas. Again, filling the stomach with water may help provide an acoustic window.

Pancreatic changes:

- acute pancreatitis.
  - hypoechoic or areas of mixed echogenicity
  - +/- small amount of free fluid surrounding pancreas
  
- chronic or low-grade pancreatitis
  - mixed to hyperechoic areas

Pancreatic mass lesions:

Most mass lesions are sequelae of pancreatitis.

- pseudocysts
- cysts
- abscesses
- neoplasia (uncommon)
  - adenocarcinoma
  - islet cell tumor (insulinoma)

## Gastrointestinal sonography

### Scanning position

It is important for patients to be in lateral recumbency for the majority of gastrointestinal examination by ultrasound. Again, our patients are laterally flattened, so it stands to reason that our acoustic window will improve when we have less layers of gas-filled bowel to scan through.

Since it is not practical for us to examine the entire gastrointestinal tract from stomach to colon such as in an exploratory surgery, we must be satisfied with exploring sonographically as much of the bowel as possible. To this end, patients should be scanned in a "grid" pattern from both left and right lateral recumbency, while watching for abnormal bowel loops, masses, free fluid, lymph nodes, and other abnormalities on the monitor. When it possible abnormality is noted, the grid pattern is halted and the abnormality is examined in several scan planes until the sonographer is satisfied that the structure has been clarified.

**Stomach** -- the stomach is immediately caudal to the liver and should be examined from both the left lateral and right lateral positions. The fundus of the stomach must often be examined from an intercostal view in the left lateral abdomen. Sliding the transducer ventrally to the midline in both the sagittal and transverse planes gives a good view of the body of the stomach. The pylorus is best seen from the right lateral aspect. In most instances, near wall of the stomach is all that can be assessed due to gastric gas. Allowing the patient to drink water or infusing water via a stomach tube can improve the acoustic window and provide visualization of a larger portion of the stomach wall.

**Duodenum** -- is best visualized from the right lateral position. The duodenum is the most superficial organ in the right lateral abdomen and can be visualized just deep to the body wall. Very little pressure should be applied with the transducer, as the duodenum can be very mobile. Since all small bowel appears similar sonographically, the duodenum can be confirmed by following it cranially to the pylorus and caudally to the caudal duodenal flexure (CDF will be at the level of the umbilicus and dogs and cats).

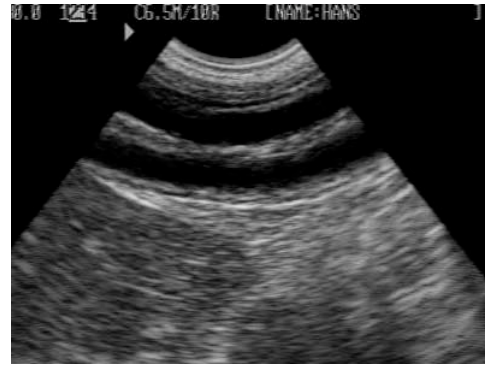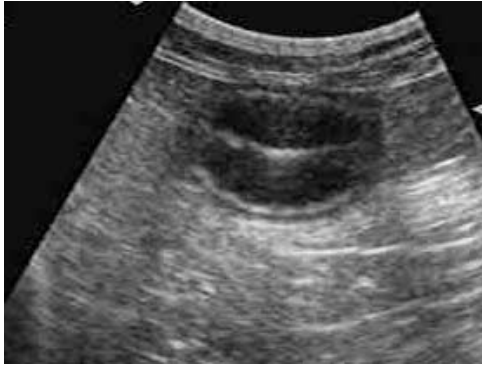### Normal appearance

Normal GI tract is composed of four major layers that can be seen sonographically:

- Mucosa (hypoechoic)
- submucosa (hyperechoic)
- muscularis (hypoechoic)
- Serosa (hyperechoic)

These, plus the mucosal/lumen interface have a **distinct banded appearance**, and all should be seen. The near wall of the segment may be the only portion visualized because of gas in the bowel; gas reflects US and makes any structure deep to the gas not visible. Submucosal and muscular layers should be thin and of equal thickness.

**Motility** can be assessed in real time; 5-6 segmental contractions per minute should be seen.



**Size.** The thickness of a single wall of stomach or small bowel can be measured using the electronic calipers on the ultrasound machine.

GI thickness	Dogs	Cats
Stomach	3-5 mm	2-4.4 mm (at rugal fold)
Duodenum	5 mm (max)	
Small bowel	2-4 mm(av.)	2.1 mm (av.)
Colon	<2 mm	1.7 mm (av.)

## Indications

## Interpretation

GI diseases seen:

*Congenital Hypertrophic Pyloric Stenosis*

•

*Chronic Hypertrophic Gastropathy*

•

*Neoplasia*

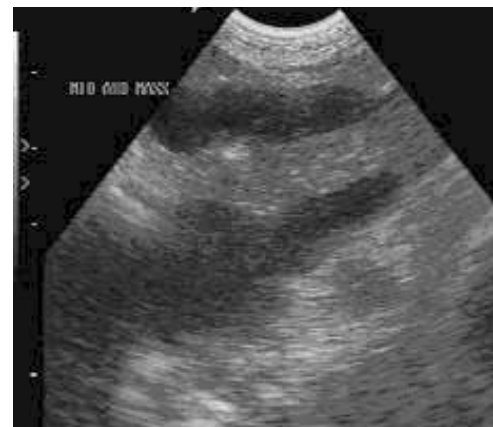
- Focal wall thickening with loss of wall layers
- some neoplasia does not cause loss of wall layers (carcinoma-in-situ)
- mass lesions with adhesions to adjacent bowel

*Inflammatory disease*

- Bowel wall > 5mm thickness
- maintain visualization of wall layers

*Fungal enteritis*

- Thickening of bowel wall diffusely or specific segments
- loss of normal wall layers



- +/- increased echogenicity
- mesenteric, gastric, and colic lymph nodes +/- enlarged

***FIP***

- Similar to fungal enteritis
- look for renal changes

***Intussusception***

- Characteristic appearance - double concentric hypoechoic ring with hyperechoic center (“bulls-eye” or target)
- May see free peritoneal fluid

***Ileus***

- Obstruction
- Associated with acute gastroenteritis, foreign bodies, localized inflammation and adhesion, intussusception, and neoplasia. May also be drug-induced, or as a response to abdominal pain.
- Characterized by increased intraluminal gas. May make visualization of intra-abdominal organs very difficult due to gas artifact.

***Foreign body***

- Technically challenging to diagnose gastrointestinal foreign body using ultrasound
- Foreign body may be sonolucent; may only show up as a “filling defect” or less echoic region in the more hyperechoic ingesta
- A bright interface associated with strong acoustic shadowing is highly suggestive of the foreign body. Quite often the bright interface will not change shape or deform when the surrounding stomach/bowel undergoes a peristaltic movement.

# Reproductive sonography

## Male

When should I use diagnostic US in a male dog?

- hematuria
- dysuria
- stranguria
- constipation
- testicular abnormalities
- prostatic/testicular enlargement on PE

## Prostate

- size is subjective
- smoothly marginated hyperechoic capsule
- medium-to-fine homogeneous echotexture
- echogenicity variable relative to surroundings
- bilobed in transverse plane
- anechoic to hypoechoic urethra visible
- pubis may obscure view of caudal aspect

## Prostate - Benign Hyperplasia

- enlargement (symmetric/asymmetric)
- smooth or nodular margins w/out capsule disruption
- echogenicity variable
- echotexture variable
- hyperechoic foci - fibrosis
- mineralization generally not seen

## Prostate - Prostatitis

- sonographically similar to BPH
- usually heterogeneous, mixed echogenicity
- +/- focal areas of hypo- or hyperechogenicity
- +/- cyst-like structures (including abscess formation)
- sub-lumbar lymph nodes often enlarged
- aspirate for culture/sensitivity and biopsy

## Prostate - Neoplasia

- mineralization is strongly suggestive \*
- irregular margins, disruption of capsule \*
- extension to urethra and bladder neck \*
- sub-lumbar lymph nodes usually enlarged
- adenocarcinoma and undifferentiated carcinomas
- biopsy to confirm; radiograph thorax for metastasis

## Prostate - Cysts

- prostatic and paraprostatic
- anechoic, fluid-filled structure w/ variable wall thickness
- +/- hyperechoic foci which swirl when agitated
- internal septations

- differentiate from urinary bladder
- contrast cystogram to identify structures radiographically in addition to US

#### Testes - Indications

- assess palpable and nonpalpable changes
- differentiate testicular from epididymal and scrotal disease
- localize undescended testicles
- abnormal testicles warrants abdominal exam for metastasis or systemic disease
- need biopsy for differentiation of mass lesions

#### Testes/scrotum - Diseases

- Neoplasia
- Orchitis
- Atrophy
- Torsion

#### Scrotal hernias

## Female

#### Ovaries

##### Normal appearance:

- 1.5 x 0.7 x 0.5 cm round to oval structures caudal to kidney (caudal pole)
- appearance varies with estrus cycle
- homogeneous and isoechoic to renal cortex in anestrus and early proestrus
- multiple follicles at estrus
- daily serial exams needed to detect ovulation

##### Cystic ovaries

- pyometra, hydrometra
- cystic endometrial hyperplasia

##### Ovarian neoplasia

- masses of complex echotexture
- bilateral primary adenocarcinomas

##### Ovarian stump granulomas

#### Uterus

##### Normal appearance:

- hypoechoic, 3-layered tubular structure
- differentiate from small bowel - lacks motility, lacks intraluminal gas, and 3 vs. 5 layers
- located between bladder and colon

##### pyometra

- enlarged uterine horns (usually symmetrical)
- walls variable (may be thick and irregular or smooth and thin)
- homogeneous, anechoic luminal contents

##### stump pyometra (granuloma)

- centesis of uterine fluid is contraindicated; may contaminate peritoneum with bacteria

neoplasia - rare in dogs and cats

- adenomas
- adenocarcinomas
- leiomyomas
- leiomyosarcomas

Female - Uterus - pregnancy

- early diagnosis
  - 10 days post-breeding in dogs
  - 11 days post-breeding in cats
- fetal numbers not accurately assessed
- viability can be assessed by single exams (detection of heartbeat) or serial exams (observation of fetal growth)
- enlarging uterus
- \*gestational sac (d.18 post-ovulation)
- embryo (d. 21-23 post-ovulation)
- \*cardiac activity (d. 21-23 post-ovulation)
- \*fetal movement (d. 33 post-ovulation)

## Abdominal Ultrasound Exam Report

**Date:**

**Client name:**

**Case number:**

Abnormal	Organ	Normal	Not seen	Comments
	Spleen			
	Left kidney			
	Left adrenal			
	Aorta			
	CVC			
	Urinary bladder			
	Uterus/ovaries			
	Prostate			
	Testicles			
	Colon			
	Stomach			
	Lymph nodes			
	Liver			
	Gallbladder			
	Right kidney			
	Right adrenal			
	Pancreas			
	Duodenum			
	Peritoneum			
	Small bowel			
	Free fluid			

**Comments:**

**Conclusions:**

- 1.
- 2.
- 3.



**References used in preparation of lectures:**


Veterinary Diagnostic Ultrasound (2nd edition)  
by Nyland and Mattoon  
W.B. Saunders, 2002

Veterinary Diagnostic Ultrasound (1st edition)  
by Nyland and Mattoon  
W.B. Saunders, 1995

Manual of Veterinary Echocardiography  
By June Boon  
Williams and Wilkins, 1999

Course notes 1995-1999: Sue Finn-Bodner, DVM, MS, DACVR (portions used  
with permission from Dr. Finn-Bodner)

Veterinary Radiology and Ultrasound  
bimonthly publication of the ACVR



Thanks to all of you for taking time out of your busy schedules to attend this ultrasound course. It is my sincere goal that each of you leave here excited about ultrasound and ready to add it to your diagnostic regimen. Please call if I can help you in your ultrasound or diagnostic imaging endeavors in any way.

Debra M. Beard, DVM, MS, DACVR  
bearddm@auburn.edu  
334-844-5045 (Auburn University)